



UNIVERSITÀ  
DEGLI STUDI  
FIRENZE

## FLORE

# Repository istituzionale dell'Università degli Studi di Firenze

### **Ultrasonographic staging: a new staging system for deep endometriosis.**

Questa è la Versione finale referata (Post print/Accepted manuscript) della seguente pubblicazione:

*Original Citation:*

Ultrasonographic staging: a new staging system for deep endometriosis / Coccia ME;Rizzello F. - In:  
ANNALS OF THE NEW YORK ACADEMY OF SCIENCES. - ISSN 0077-8923. - ELETTRONICO. - 1221:(2011), pp.  
61-69. [10.1111/j.1749-6632.2011.05951.x]

*Availability:*

This version is available at: 2158/781229 since:

*Published version:*

DOI: 10.1111/j.1749-6632.2011.05951.x

*Terms of use:*

Open Access

La pubblicazione è resa disponibile sotto le norme e i termini della licenza di deposito, secondo quanto stabilito dalla Policy per l'accesso aperto dell'Università degli Studi di Firenze (<https://www.sba.unifi.it/upload/policy-oa-2016-1.pdf>)

*Publisher copyright claim:*

(Article begins on next page)

# Ultrasonographic staging: a new staging system for deep endometriosis

Maria Elisabetta Coccia<sup>1</sup> and Francesca Rizzello<sup>2</sup>

<sup>1</sup>Department of Science for the Health of Woman and Child, University of Florence, Florence, Italy. <sup>2</sup>Department of Medical Pathophysiology, Sapienza University of Rome, Rome, Italy

Address for correspondence: Maria Elisabetta Coccia, via Ippolito Nievo 2, 50129 Firenze, Italy. [cocciame@tin.it](mailto:cocciame@tin.it)

Modern imaging techniques allow for the noninvasive diagnosis of endometriosis. Preoperative staging of pelvic endometriosis helps the gynecologist plan therapy and offer a prognosis to patients. The challenge of creating a satisfactory classification of endometriosis remains. The ability of the current classification schemes to predict pregnancy outcome, or aid in the management of pelvic pain, is recognized to be inadequate. The study of deeply infiltrating endometriosis and adenomyosis is greatly hampered by a lack of clear terminology and the absence of a consensus classification of the lesions. A reviewed consensus classification of endometriosis in general, with a more detailed consideration on deep endometriosis, is urgently required. We suggest a new staging system for deep, infiltrating endometriosis based on ultrasonographic findings. Prospective data collection and review in large centers may provide a larger clinical base from which to derive empirical point scores and breakpoints in the classification scheme.

**Keywords:** endometriosis; deep infiltrating endometriosis; DIE; classification; ultrasound

## Introduction

Endometriosis is a benign gynecological disease defined as the presence of endometrial glands and stroma outside of the uterine cavity. It affects 5–10% of women of reproductive age and produces symptoms including dysmenorrhea, deep dyspareunia, and chronic pelvic pain.<sup>1</sup>

Although endometriosis represents one of the most studied gynecological conditions, it still remains an enigmatic disease, difficult both to study and to understand. A part of the clinical confusion, and inappropriate management surrounding endometriosis, comes from the variability of its clinical presentation, the variable aspect of the lesions, and from its multifocal distribution. Furthermore, the lack of clear terminology and the absence of a consensus on a preoperative staging system can lead to misunderstandings when trying to compare results and outcomes.

## Endometriosis: a multiform disease

Three different forms of endometriosis must be considered: peritoneal, ovarian, and deep infiltrating

endometriosis (DIE).<sup>2</sup> The presence of endometrial glands and stroma within the myometrium characterize another form of endometriosis called adenomyosis. In this case, microscopically, there are endometrial glands and stroma within the myometrium.

In detail, superficial peritoneal endometriosis has multiple types of appearance. The typical lesion has a puckered, blue-black, powder-burned appearance. Others appear as atypical lesions, including the microscopic, early, or subtle (papular or glandular; vesicular), hemorrhagic (red vesicular or flame-like), and fibrotic (from white to black pigmented) lesions, supposedly representing the evolution of a superficial implant.<sup>3,4</sup>

Ovarian endometrioma is also called a “chocolate cyst” because of the characteristic dark brown or chocolate-colored content.<sup>5</sup> It can be monolateral or bilateral. When only one ovary is affected, the preferential site is the left ovary.<sup>3</sup>

DIE is a specific entity histologically defined when endometriotic lesions extend more than 5 mm underneath the peritoneum.<sup>6,7</sup> DIE is responsible for painful symptoms, the severity of which are strongly

associated with the depth of the lesions.<sup>8–10</sup> Another aspect of deeply infiltrating endometriosis lesions is their multifocal character. In a group of 241 patients, 344 lesions were histologically determined as DIE. The percentage of lesions located on a single organ (uterosacral ligaments, upper portion of the posterior vagina wall, bladder, and intestine) ranged between 29% and 83%.<sup>11</sup>

Because of the different locations, possible origins, types of appearance, and hormone responsiveness, it has been recently suggested that peritoneal endometriosis, ovarian endometriosis, DIE, and adenomyosis are different entities—each possibly with a different pathogenesis.<sup>12,13</sup>

Peritoneal endometriosis is thought to be the consequence of the implantation of menstrual laboring after reflux through the fallopian tube and ovarian endometrioma, and through the consequence of nonhormone-regulated bleeding from intraovarian epithelial inclusions after they have undergone metaplasia into endometrial-like tissue.<sup>5</sup>

The pathogenesis of DIE is the most debated. According to some investigators, its histopathogenesis is probably not related to the implantation of endometrial cells deriving from retrograde menstruation, but rather to the metaplasia of Müllerian rests. Recently, Chapron<sup>14</sup> observed that pelvic DIE lesions are more frequently observed in the posterior pelvic compartment and are most often located on the left side. Furthermore, abdominal DIE lesions are far less frequent than pelvic DIE lesions and, unlike these, they are most often located in the right side of the abdominal cavity (appendix and ileocecum junction). The author concluded that these observations may be also in favor of the theory of retrograde menstruation for DIE lesions.<sup>14</sup>

### Current staging systems for endometriosis

Endometriosis may present itself in many forms, but for clinical and research purposes it can be classified as peritoneal, ovarian, or deep endometriosis. The extent of the disease varies from a few small lesions on the peritoneum to extensive fibrosis and adhesion formation, often causing marked distortion of pelvic anatomy. We cannot forget this principle of histopathology when classifying the disease.

Currently, the revised scoring system of the American Society for Reproductive Medicine (rASRM) is used to determine the disease stage (ranging from

I, indicating minimal disease, to IV, indicating severe disease) on the basis of the type, location, appearance and depth of invasion of the lesions, and the extent of the disease and adhesions.<sup>15,16</sup> Despite the revisions, the rASRM system has serious limitations, including poor correlation with severity and poor prognostic valuation of the response to therapies for pain or infertility.<sup>16</sup> Moreover, as a surgical staging system, it implies the necessity of a surgical approach.

Visualization at surgery, mainly through laparoscopy, is still regarded as the gold standard diagnostic test—the definitive method to diagnose and stage endometriosis when looking for evidence of all types and stages of endometriosis. On the other hand, surgery performed in order to verify the presence of endometriosis or adhesions and to stage the disease, might imply high health costs and surgery risks for patients.

### Staging deep endometriosis

Another limitation of the rASRM system is the lack of specific in addressing the infiltrative form of endometriosis. In the rASRM staging system, great importance is given to ovarian endometriomas. But from a practical point of view, surgery for these conditions is not a complex procedure and does not require particularly experienced and expertly skilled surgeons, nor a multidisciplinary approach.<sup>17</sup>

Several schemes have been proposed to classify endometriosis with deep infiltrating lesions. Koninckx and Martin's scheme was essentially based on the pathogenesis of DIE [infiltration (Type 1), retraction (Type 2), and adenomyosis externa (Type 3)].<sup>18</sup> Adamyan proposed a staging system with retrocervical endometriosis according to the extent of the disease: Stage I with no vaginal involvement, Stage II involves the vagina, Stage III involves the vagina and rectum and has cul-de-sac distortion, and Stage IV includes cul-de-sac obliteration.<sup>19</sup> The Martin and Batt staging system also takes the DIE lesions' topography into account, differentiating among retrocervical, rectovaginal pouch, and rectovaginal septum endometriosis.<sup>20</sup> As Chapron observed, these staging systems are essentially limited by two factors. They do not consider the possibility of associated anterior disease (bladder DIE) in cases of posterior DIE; additionally, they group together patients for whom the surgical treatment may be very different.<sup>11</sup>

More recent staging systems try to correct these limitations. Chapron *et al.* suggest a classification essentially based on the DIE anatomic distribution and surgical management.<sup>11</sup> They take into account the presence of lesions in both antero- and posterouterine pouches.<sup>11</sup> Finally, in the ENZIAN-Score, four different stages are pronounced in analogy to an oncological staging, especially focusing on the retroperitoneal part of the severe endometriosis.<sup>21</sup>

Nevertheless, these staging systems based on surgical approaches, do not take into account symptoms of patients, do not specify the size and shape of the lesions, and are not suitable for a follow-up of patients when a conservative/expectant course of management is decided. Thus, the challenge of creating a satisfactory classification of endometriosis, and namely of DIE, remains.

As Vercellini observed, a valid and reliable classification should allow immediate comprehension of the severity of the condition, guide therapeutic strategies, permit the formulation of a reliable prognosis, and represent a feasible tool for research purpose.<sup>17</sup>

A number of important motivations are at the basis of the necessity for an ultrasonographic stage system of endometriosis:

- to map distribution of the lesions;
- to inform the patient of the therapeutic options and the prognosis;
- to allow correct planning of the therapeutic approach and facilitate choosing between several treatment options, medical, and surgical;
- to produce a standardized method and language for scientific groups studying endometriosis; and
- to allow comparisons of results.

In cases of expectant/medical management:

- to facilitate follow-up of the lesions; and
- to evaluate efficacy of medical treatment in reducing painful symptoms.

In the preoperative evaluation:

- to correctly identify different locations of endometriosis in certain sites, such as intestine or bladder where the surgery is particularly difficult and risky, thus requiring the cooperation of different specialists (multidisciplinary approach);

- to select an appropriate surgeon with sufficient experience in this kind of surgery; and
- to counsel the patient about the risks of surgery.

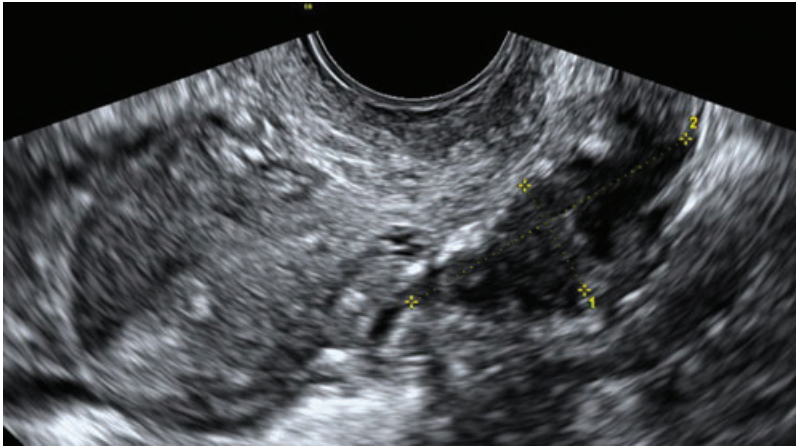
## Imaging methods

Modern imaging techniques allow noninvasive diagnosis of endometriosis. Ultrasound is generally considered a noninvasive, reproducible, and cost/effective method.

An ovarian endometrioma is described with imaging as a persistent, circular, homogeneous, hypoechoic “tissue,” without papillary proliferations, and with a clear demarcation from the ovarian parenchyma.<sup>22–27</sup> Deep endometriosis implants are suspected from the presence of hypoechoic linear thickening or nodules/masses, with or without regular contours, that have thin band-like echoes departing from the center of the mass defined as an “Indian head dress” (Fig. 1).<sup>28,29</sup>

Many studies have validated the nonsurgical diagnosis of endometriomas and deep endometriosis through transvaginal ultrasonography (TV-US).<sup>22–29</sup> Specifically, investigators have observed a sensitivity of 81–89% and specificity of 91–97% in predicting the endometriotic nature of ovarian cysts.<sup>30</sup> With regard to deep endometriosis, Guerriero *et al.* observed a high specificity and sensitivity in the detection of vaginal wall lesions (sensitivity of 91%, specificity of 89%) and rectovaginal endometriosis (sensitivity of 74%, specificity of 88%). For other locations, the sensitivity was lower (ranging from 67% to 33%) but with a comparable specificity.<sup>29,31</sup>

Recent technology offers interesting new procedures, such as 3-dimensional sonography, that could integrate 2-dimensional sonography and increase its diagnostic accuracy in the assessment of deep endometriosis. As suggested by Guerriero *et al.*, in the near future, 3-dimensional sonography for DIE could be an interesting mode of research with positive effects in everyday clinical practice.<sup>32</sup> Dessole *et al.* suggested “sonovaginography” as a new technique for the assessment of rectovaginal endometriosis. It is based on TV-US, combined with the introduction of saline solution into the vagina that creates an acoustic window between the probe and the surrounding structures of the vagina.<sup>33</sup> Recently Guerriero *et al.* have created “tenderness-guided” ultrasonography by increasing the amount of ultrasound gel inside the probe cover. Moreover,



**Figure 1.** Abnormal hypoechoic implant of deep endometriosis with irregular contours.

they asked patients to indicate which points felt tender under gentle pressure of the probe. Using this approach, they obtained a specificity of 95% with a sensitivity of 90%.<sup>29</sup> Locations above the rectosigmoid junction may be beyond the field of view of a transvaginal approach and limited by the presence of air for the transabdominal approach. These cases would require magnetic resonance imaging (MRI).<sup>34</sup>

Nonsurgical diagnostic approaches, such as TV-US and MRI, perform poorly in the detection of peritoneal and ovarian implants.<sup>3</sup> This group of patients often has less severe symptoms and has little risk of developing serious associated problems. Because the clinical significance of minimal endometriosis is not thoroughly defined, it is uncertain by which means, if at all, such types of peritoneal or ovarian lesions should be treated. It is still uncertain whether some early forms of endometriosis (rASRM I and II) may represent a physiological condition and thus should not be considered a disease.<sup>35</sup>

What we retain to be the most urgent criterion is a tool to study endometriosis, at the time of the first diagnosis, that is able to allow the gynecologist to discuss the various options of treatment with the patient and to follow-up the patients in a more objective way.

### **Deeply infiltrating endometriosis: ultrasonographic classification proposal**

Currently, transvaginal ultrasound is involved in the diagnosis and workup of endometriosis. Its

widespread use, the low invasivity, the reduced cost, and the high specificity and sensitivity make transvaginal sonography a first-level test in the study of endometriosis.

We propose a new staging system based on ultrasonographic findings. Our goal was to develop a feasible and reproducible clinical tool, to map and describe deep endometriotic implants, and to allow follow-up in cases of conservative management.

This classification is based on the evaluation of five components of DIE implants: location, size, shape of the lesions, symptoms aroused during the exam, and infiltration of the bowel wall. Adjunctive elements are also evaluated (e.g., presence of mono-lateral or bilateral ovarian endometrioma, kissing ovaries, adenomyosis, fixity of organs, and the urinary tract; Fig. 2). The staging system requires a detailed ultrasonographic examination protocol that includes, in addition to routine analysis of the uterus and ovaries, analysis of the vesicouterine pouch and the pouch of Douglas, the bowel (rectum, sigmoid colon, appendix, cecum, and small intestine), the retrocervical area (uterosacral ligaments, torus uterinus, and posterior vaginal fornix), and the rectovaginal septum.

The multifocal character of deeply infiltrating endometriosis lesions has prompted us to propose an “ultrasonographic classification” based firstly on the location of the lesions. Lesions observed can involve the anterior, posterior, or lateral compartments. The cervix of the uterus is a structure that is easy to recognize during TV-US. Thus, the distribution of lesions is described in more detail by specifying the position

in relation to the cervix: supracervical, cervical, or vaginal.

For each location, lesions are described as nodules (solid hypoechoic nodule with a rounded shape), linear thickening (abnormal hypoechoic linear thickening), or plaques (hypoechoic areas with irregular shape). The maximum longitudinal, anteroposterior, and transversal axes of the implants are also measured. In our classification scheme, painful symptoms, aroused during the exam by gently pushing the probe on each lesion, are registered on the basis of a numerical rating scale: none (0), mild (1–3), moderate (4–6), and severe (7–10).

Bowel involvement is suspected when a long, nodular, predominantly solid, hypoechogenic lesion adhering to the wall of the intestinal loop is observed. The degree of infiltration may vary from the serosal layer as far as the mucosal layer. Bazot *et al.* suggested that TV-US can accurately diagnose colorectal endometriosis and identify the infiltration of the muscularis propria.<sup>28</sup> All the layers of the bowel wall should be observed from the outer toward the inner layers: the serosa (thin hyperechoic line); the muscularis propria (two hypoechoic strips separated by a fine hyperechoic line); the submucosa (hyperechoic); the muscularis mucosa (hypoechoic); and the interface between the lumen and the mucosal layer (hyperechoic).<sup>36</sup>

Bazot's results were not, however, confirmed in larger studies. Thus, other techniques often are employed to specify the degree of bowel infiltration, for example, TV-US with bowel preparation (TVUS-BP),<sup>36</sup> transrectal ultrasonography,<sup>37,38</sup> endoscopic transrectal ultrasonography,<sup>28,39</sup> TV-US combined with water-contrast in the rectum (RWC-TVS),<sup>40</sup> and multislice computerized tomography combined with the distension of the colon by rectal enteroclysis.<sup>41</sup> In these cases, supplementary procedures should always be specified.

Adjunctive elements are added on a separate section: ovarian endometrioma(s), kissing ovaries, ovarian fixity, adenomyosis (diffuse or nodular), or urinary tract evaluation. The detection of kissing ovaries at ultrasound, when the ovaries are entirely or partly joined together and stabilized behind the pouch of Douglas, seems strongly associated with the presence of endometriosis, and is a marker of the most severe form of this disease.<sup>42</sup> Ovarian fixity was assessed by abdominal pressure with the ex-

aminer's hand and gentle pressure with the vaginal probe. In our experience, TV-US performed in the presence of fluid in the pelvis may show better adhesions attached to the uterus and ovaries. During TV-US, the absence of sliding of surrounding tissues and, in presence of pelvic fluid, the absence of ballotement are suggestive for ovarian adhesions. In our classification, two levels were distinguished: absence of adhesions, if the ovary is completely free and could be observed sliding across the surrounding tissues; and presence of adhesions, when some of the surrounding structures could not be separated from the ovary.

### New application and future perspectives

In the management of endometriosis, a reviewed consensus classification of the disease in general, with a more detailed attention to deep endometriosis, is urgently required. One of the principal challenges actually involved in managing endometriosis is obtaining information that might help the decision-making process and allow the gynecologist to select the optimal surgical strategy, even before the surgery.<sup>36,43</sup> In cases of DIE, the most symptomatic form of the disease, often requiring more complex surgical treatment, this information assumes particular weight.<sup>36</sup>

The ideal situation is to receive complete treatment in a single operation. As the effectiveness of surgery depends on how radical exeresis is, the surgeon should be aware of the location of DIE and plan the operative technique accordingly.<sup>11</sup> Thus, when deep endometriosis is clinically suspected, it is fundamental to perform an adequate preoperative workup capable of indicating whether one or more lesions are present, mapping the lesions, and identifying the size and depth of the lesion(s), and the involvement of surrounding tissue. With this information, it is then possible to define the treatment option to be applied, to devise a comprehensive surgical plan, and to coordinate different surgical procedures when necessary.<sup>36</sup>

Moreover, the lack of appropriate noninvasive tools is currently the main limitation for monitoring the disease progression, predicting clinical outcomes, and evaluating therapeutic effects even when medical/expectant management has been decided. A recent review showed that medical treatment in women with rectovaginal endometriosis was effective in terms of pain relief, lesion reduction during

### DEEP ENDOMETRIOSIS STAGING

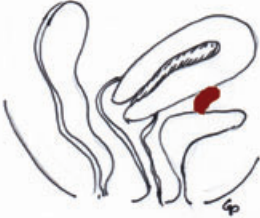
Name \_\_\_\_\_ Date \_\_\_\_\_

(LP \_\_\_\_\_)

**Legend:** P= plaque, N=nodule, L= linear thickening  
 S=serosal layer, SM=submucosal layer, M=mucosal layer

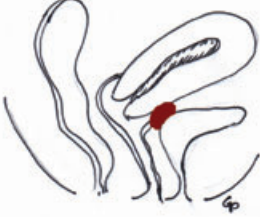
ANTERIOR COMPARTMENT

**a) SUPRACERVICAL-BLADDER**



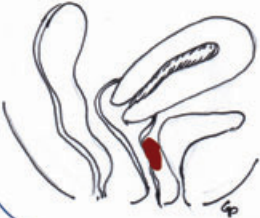
	Num.	Size (mm)	Pain
<input type="checkbox"/> sn	P		
	N		
	L		
<input type="checkbox"/> dx	P		
	N		
	L		
<input type="checkbox"/> med	P		
	N		
	L		

**b) CERVICAL**



	Num.	Size (mm)	Pain
<input type="checkbox"/> sn	P		
	N		
	L		
<input type="checkbox"/> dx	P		
	N		
	L		
<input type="checkbox"/> med	P		
	N		
	L		

**c) VAGINAL**



	Num.	Size (mm)	Pain
<input type="checkbox"/> sn	P		
	N		
	L		
<input type="checkbox"/> dx	P		
	N		
	L		
<input type="checkbox"/> med	P		
	N		
	L		

**Figure 2.** “Deep endometriosis staging” form.

therapy, and improvement in health-related quality of life.<sup>44</sup> The incessant progress in production of new pharmaceuticals creates an enormous need for noninvasive diagnostics of endometriosis.

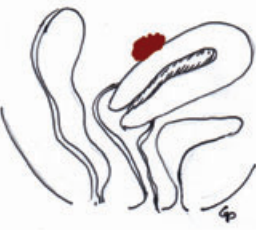
In light of this, a standard ultrasound mapping technique may develop into a very promising tool

for a noninvasive, reproducible, and feasible staging system in the future.

Some limitations of this classification system need to be identified. For example, if there are multiple lesions at a given site, it might be difficult to assess which of the lesions is responsible for causing pain

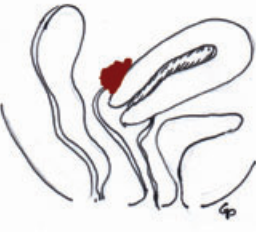
POSTERIOR COMPARTMENT

**a) SUPRACERVICAL- RECTO-SIGMOID**



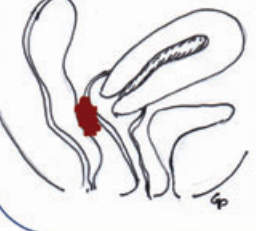
	Num.	Size (mm)	Bowel Infiltration (S/S/M/M)	Pain
<input type="checkbox"/> sn	P			
	N			
	L			
<input type="checkbox"/> dx	P			
	N			
	L			
<input type="checkbox"/> med	P			
	N			
	L			

**b) RETROCERVICAL**



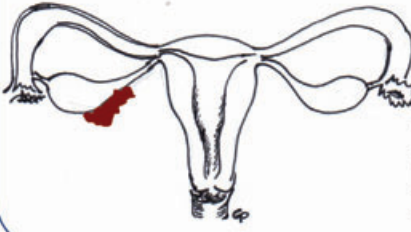
	Num.	Size (mm)	Bowel Infiltration (S/S/M/M)	Pain
<input type="checkbox"/> sn	P			
	N			
	L			
<input type="checkbox"/> dx	P			
	N			
	L			
<input type="checkbox"/> med	P			
	N			
	L			

**c) RECTO-VAGINAL**



	Num.	Size (mm)	Bowel Infiltration (S/S/M/M)	Pain
<input type="checkbox"/> sn	P			
	N			
	L			
<input type="checkbox"/> dx	P			
	N			
	L			
<input type="checkbox"/> med	P			
	N			
	L			

LATERAL COMPARTMENT



	Num.	Size (mm)	Pain	Ovarian Fixity
<input type="checkbox"/> dx	P			<input type="checkbox"/> yes
	N			<input type="checkbox"/> no
	L			
<input type="checkbox"/> dx	P			<input type="checkbox"/> yes
	N			<input type="checkbox"/> no
	L			

Figure 2. Continued

during examination, the perception of pain might vary significantly from individual to individual and in the same patient across different examinations. Moreover, the examiner might apply a pressure of

different intensity. Regarding the evaluation of pain, our group tried applying the “tenderness-guided” TV-US suggested by Guerriero *et al.* as a new method for the detection of deep endometriosis.<sup>29</sup> Patients



were asked to indicate during the ultrasonographic examination which points felt tender under gentle pressure of the probe, and examiners paid particular attention to evaluate those sites. Moreover, the same investigators observed that this technique showed high specificity and sensitivity in the detection of vaginal and rectovaginal endometriosis. Good specificity associated with lower sensitivity was obtained in the diagnosis of deep endometriosis of uterosacral ligaments, rectosigmoid involvements, and anterior deep endometriosis.<sup>29</sup> Notwithstanding these limitations, in our experience, evaluation of pain aroused during TV-US examination in the different compartments (anterior, posterior, and lateral) before and after treatment is useful for clinically assessing how intensely patients are feeling pain and for monitoring the effectiveness of treatments in time. As pain is a subjective experience, self-reported pain scores are used widely in clinical and research settings; the numeric rating scale has shown high accuracy for quantifying a patient's subjective pain.<sup>45</sup>

Our proposal is intended to provide a basis for future developments. Prospective data collection and review in large centers may provide a larger clinical base from which to derive empirical point scores and breakpoints in the classification scheme. As with any new examination, there will be a substantial learning curve with TV-US mapping, and intraobserver and interobserver variability should be evaluated. The results of further studies will determine whether preoperative ultrasonography mapping can lead to a decrease in the number of surgical procedures needed, in a change of the surgical procedure planned, in a more complete exeresis, and reduction of recurrences and of surgical complications.

## Conflicts of interest

The authors declare no conflicts of interest.

## References

- Practice Committee of the American Society for Reproductive Medicine. 2006. Endometriosis and infertility. *Fertil. Steril.* **86**(5 Suppl): S156–S160.
- Donnez, J., M. Nisolle, F. Casanas-Roux, *et al.* 1995. Stereometric evaluation of peritoneal endometriosis and endometriotic nodules of the rectovaginal septum. *Hum. Reprod.* **11**: 224–228.
- I. Brosens, P. Puttemans, R. Campo, *et al.* 2004. Diagnosis of endometriosis: pelvic endoscopy and imaging techniques. *Best Pract. Res. Clin. Obstet. Gynaecol.* **18**: 285–303.
- Scarselli, G., F. Rizzello, F. Cammilli, *et al.* 2005. Diagnosis and treatment of endometriosis. *Minerva Ginecol.* **57**: 55–78.
- Shaw, R.W. 1993. *Atlas of Endometriosis*, p. 16, The Parthenon Publishing Group, Casterton Hall, Carnforth.
- Cornillie, F.J., D. Oosterlynck, J.M. Lauweryns, *et al.* 1990. Deeply infiltrating pelvic endometriosis: histology and clinical significance. *Fertil. Steril.* **53**: 978–983.
- Koninckx, P.R., C. Meuleman, S. Demeyere, *et al.* 1991. Suggestive evidence that pelvic endometriosis is a progressive disease, whereas deeply infiltrating endometriosis is associated with pelvic pain. *Fertil. Steril.* **55**, 759–765.
- Fauconnier, A. & C. Chapron. 2005. Endometriosis and pelvic pain: epidemiological evidence of relationship and implications. *Hum. Reprod. Update*, **11**: 595–606.
- Porpora, M.G., P.R. Koninckx, J. Piazze, *et al.* 1999. Correlation between endometriosis and pelvic pain. *J. Am. Assoc. Gynecol. Laparosc* **6**: 429–434.
- Chapron, C., A. Fauconnier, J.B. Dubuisson, *et al.* 2003. Deeply infiltrating endometriosis: relation between severity of dysmenorrheal and extent of the disease. *Hum. Reprod.* **18**: 760–766.
- Chapron, C., A. Fauconnier, M. Vieira, *et al.* 2003. Anatomical distribution of deeply infiltrating endometriosis: surgical implications and proposition for a classification. *Hum. Reprod.* **18**: 157–161
- Nisolle, M. & J. Donnez. 1997. Peritoneal endometriosis, ovarian endometriosis, and adenomyotic nodules of the rectovaginal septum are three different entities. *Fertil. Steril.* **68**: 585–596.
- Vercellini, P., G. Aimi, S. Panazza, *et al.* 2000. Deep endometriosis conundrum: evidence in favor of a peritoneal origin. *Fertil. Steril.* **73**: 1043–1046.
- Chapron, C., N. Chopin, B. Borghese, *et al.* 2006. Deeply infiltrating endometriosis: pathogenetic implications of the anatomical distribution. *Hum. Reprod.* **21**: 1839–1845.
- American Society for Reproductive Medicine (ASRM). 1997. Revised American Society for reproductive Medicine classification of endometriosis: 1996. *Fertil. Steril.* **67**: 817–821.
- Giudice, L.C. 2010. Clinical practice. Endometriosis. *N. Engl. J. Med.* **362**: 2389–2398.
- Vercellini, P., G. Frontino, G. Pietropaolo, *et al.* 2004. Deep endometriosis: definition, pathogenesis and clinical management. *J. Am. Assoc. Gynecol. Laparosc.* **11**: 127–136.
- Koninckx, P.R. & D.C. Martin. 1992. Deep endometriosis: a consequence of infiltration or retraction or possibly adenomyosis externa? *Fertil. Steril.* **58**: 924–928.
- Adamyán, L. 1993. Additional international perspectives. In *Gynecologic and Obstetric Surgery*. D.H. Nichols, Ed.: 1167–1182. Mosby Year Book, St. Louis.
- Martin, D.C. & R.E. Batt. 2001. Retrocervical, rectovaginal pouch, and rectovaginal septum endometriosis. *J. Am. Assoc. Gynecol. Laparosc.* **8**: 12–17.
- Tuttles, F., J. Keckstein, U. Ulrich, *et al.* 2005. ENZIAN-score, a classification of deep infiltrating endometriosis. *Zentralbl. Gynäkol.* **127**: 275–281.

22. Guerriero, S., V. Mais, S. Ajossa, *et al.* 1995. The role of endovaginal ultrasound in differentiating endometriomas from other ovarian cysts. *Clin. Exp. Obstet. Gynecol.* **22**: 20–22.
23. Mais, V., S. Guerriero, S. Ajossa, *et al.* 1993. The efficiency of transvaginal ultrasonography in the diagnosis of endometrioma. *Fertil. Steril.* **60**: 776–780.
24. Ubaldi, F., A. Wisanto, M. Camus, *et al.* 1998. The role of transvaginal ultrasonography in the detection of pelvic pathologies in the infertility workup. *Hum. Reprod.* **13**: 330–333.
25. Volpi, E., T. De Grandis, G. Zuccaro, *et al.* 1995. Role of transvaginal sonography in the detection of endometriomata. *J. Clin. Ultrasound* **23**: 163–167.
26. Patel, M.D., V.A. Feldstein, D.C. Chen, *et al.* 1999. Endometriomas: diagnostic performance of US. *Radiology* **210**: 739–745.
27. Alcazar, J.L., C. Laparte, M. Jurado, *et al.* 1997. The role of transvaginal ultrasonography combined with color velocity imaging and pulsed Doppler in the diagnosis of endometrioma. *Fertil. Steril.* **67**: 487–491.
28. Bazot, M., R. Detchev, A. Cortez, *et al.* 2003. Transvaginal sonography and rectal endoscopic sonography for the assessment of pelvic endometriosis: a preliminary comparison. *Hum. Reprod.* **18**: 1686–1692.
29. Guerriero, S., S. Ajossa, M. Gerada, *et al.* 2008. Diagnostic value of transvaginal ‘tenderness-guided’ ultrasonography for the prediction of location of deep endometriosis. *Hum. Reprod.* **23**: 2452–2457.
30. Moore, J., S. Copley, J. Morris, *et al.* 2002. A systematic review of the accuracy of ultrasound in the diagnosis of endometriosis. *Ultrasound Obstet. Gynecol.* **20**: 630–634
31. Guerriero, S., S. Ajossa, M. Gerada, *et al.* 2007. “Tenderness-guided” transvaginal ultrasonography: a new method for the detection of deep endometriosis in patients with chronic pelvic pain. *Fertil. Steril.* **88**: 1293–1297.
32. Guerriero, S., J.L. Alcázar, S. Ajossa, *et al.* 2009. Three-dimensional sonographic characteristics of deep endometriosis. *J. Ultrasound Med.* **28**: 1061–1066.
33. Dessole, S., M. Farina, G. Rubattu, *et al.* 2003. Sonovaginography is a new technique for assessing rectovaginal endometriosis. *Fertil. Steril.* **79**: 1023–1027. PubMed PMID: 12749448.
34. Kinkel, K., K.A. Frei, C. Balleyguier, *et al.* 2006. Diagnosis of endometriosis with imaging: a review. *Eur. Radiol.* **16**: 285–298.
35. Rossmannith, W.G. 2009. Minimal endometriosis: a therapeutic dilemma? *Gynecol. Endocrinol.* **25**: 762–764.
36. Goncalves, M.O., S. Podgaec, J.A. Dias Jr., *et al.* 2010. Transvaginal ultrasonography with bowel preparation is able to predict the number of lesions and rectosigmoid layers affected in cases of deep endometriosis, defining surgical strategy. *Hum. Reprod.* **25**: 665–671.
37. Koga, K., Y. Osuga, T. Yano, *et al.* 2003. Characteristic images of deeply infiltrating rectosigmoid endometriosis on transvaginal and transrectal ultrasonography. *Hum. Reprod.* **18**: 1328–1333.
38. Chapron, C., I. Dumontier, B. Dousset, *et al.* 1998. Results and role of rectal endoscopic ultrasonography for patients with deep pelvic endometriosis. *Hum. Reprod.* **13**: 2266–2270.
39. Abrao, M.S., R.M. Neme, M. Averbach, *et al.* 2004. Rectal endoscopic ultrasound with a radial probe in the assessment of rectovaginal endometriosis. *J. Am. Assoc. Gynecol. Laparosc.* **11**: 50–54.
40. Valenzano Menada M., V. Remorgida, L.H. Abbamonte, *et al.* 2008. Does transvaginal ultrasonography combined with water-contrast in the rectum aid in the diagnosis of rectovaginal endometriosis infiltrating the bowel? *Hum. Reprod.* **23**: 1069–1075.
41. Biscaldi, E., S. Ferrero, E. Fulcheri, *et al.* 2007. Multislice CT enteroclysis in the diagnosis of bowel endometriosis. *Eur. Radiol.* **17**: 211–219.
42. Ghezzi, E., L. Raio, A. Cromi, *et al.* 2005. “Kissing ovaries”: a sonographic sign of moderate to severe endometriosis. *Fertil. Steril.* **83**: 143–147.
43. Abrao, M.S., M.O. Goncalves, J.A. Dias Jr., *et al.* 2007. Comparison between clinical examination, transvaginal sonography and magnetic resonance imaging for the diagnosis of deep endometriosis. *Hum. Reprod.* **22**: 3092–3097.
44. Vercellini, P., P.G. Crosignani, E. Somigliana, *et al.* 2009. Medical treatment for rectovaginal endometriosis: what is the evidence? *Hum. Reprod.* **24**: 2504–2514.
45. Jensen, M.P., P. Karoly & S. Braver. 1986. The measurement of clinical pain intensity: a comparison of six methods. *Pain* **27**: 117–126.