



Contents lists available at ScienceDirect

International Journal of Surgery Case Reports

journal homepage: www.casereports.com

A unique presentation of a renal clear cell carcinoma with atypical metastases



Staderini F. *, Cianchi F., Badii B., Skalamera I., Fiorenza G., Foppa C., Qirici E., Perigli G.

Unit of General and Endocrine Surgery, Department of Surgery and Translational Medicine, University of Florence, Florence, Italy

ARTICLE INFO

Article history:

Received 27 February 2015
Received in revised form 4 March 2015
Accepted 4 March 2015
Available online 9 April 2015

Keywords:

Kidney cancer
Renal clear cell carcinoma
Metastases
Nephrectomy
Metastasectomy
Targeted therapies

ABSTRACT

INTRODUCTION: Renal cancer is a relatively common neoplasia with renal clear cell carcinoma being the most frequent histological type. This tumor has a strong tendency to metastasize virtually to all organs. Today, new diagnostic tools allow physicians to distinguish between those patients with “incidental findings” and those with advanced metastatic disease.

PRESENTATION OF CASE: A 70-year-old male with multiple indolent subcutaneous masses underwent colonoscopy after a positive fecal screening test for colorectal carcinoma. A rectal lesion was discovered but biopsy was negative. CT scan revealed advanced renal cancer involving the peritoneal cavity, retroperitoneum and lung. Biopsy of subcutaneous masses confirmed the suspected metastases. The patient underwent surgery (an open left nephrectomy with rectosigmoid resection and metastases debulking) because of a high risk of bowel obstruction and increasing anemia. After three years of multi-targeted therapy and follow-up, the patient is still asymptomatic and in good general condition.

DISCUSSION: Treatment of metastatic renal cancer is still controversial even if more than 30% of patients have metastasis at the time of diagnosis. Recently introduced targeted therapies are encouraging but still present problems with side effects and an unlimited period of efficacy. Although there is no consensus, several studies and guidelines consider metastasectomy to be a valid option.

CONCLUSION: Recent series highlight surgery as a key-point in the management of advanced renal clear cell carcinoma. Our case demonstrates the validity of a surgical strategy supported by a multidisciplinary approach.

© 2015 The Authors. Published by Elsevier Ltd. on behalf of Surgical Associates Ltd. This is an open access article under the CC BY-NC-ND license (<http://creativecommons.org/licenses/by-nc-nd/4.0/>).

1. Introduction

Renal cancer is a relatively common neoplasia, with approximately 11,800 cases per year in Italy, amounting to 3% of all adult malignancies [1]. Renal clear cell carcinoma (RCC) is the most frequent histological type, representing 60% of cases with the highest incidence occurring in individuals between 50 and 70 years of age. Renal cancer is the urological tumor with the highest mortality rate. Its aggressive behavior, due to a strong tendency to metastasize (30% of cases are metastatic at time of diagnosis or during follow-up) is associated with 14,000 estimated deaths in 2015 in the USA [2].

While in the past, RCC typically presented as hematuria, flank pain or palpable mass in the abdomen, most cases today are asymptomatic at time of discovery, due to the availability of more accurate diagnostic tools. This trend has resulted in a greater separation between cases presenting as “incidental findings” and those with advanced metastatic disease.

RCC's strong tendency to metastasize is mainly due to complex and rich vascularization and its lymphatic drainage. The major sites of metastasis are lung [75%], bone [20%], lymph nodes [11%], liver [18%], and brain [8%] but virtually all organs can be affected [3].

2. Presentation of case

The patient, a 70-year-old man with a history of hypertension, diabetes and multiple indolent subcutaneous masses, after a positive screening fecal test for colorectal carcinoma, underwent colonoscopy. The patient was asymptomatic, with neither rectal bleeding nor hematuria.

The endoscopist described a smooth flat lesion occupying one-third of the colonic lumen extending for 5 cm, characterized by rich superficial vascularization with no mucosal ulceration, 20 cm from the anal verge. Biopsy samples showed non-specific lymphocytic inflammation with edema of the colonic mucosal wall. The main tumor markers were normal: CEA 1 ng/mL, Ca19-9 3.1 U/mL, PSA 0.39 ng/mL, CA-72.4 1.1 U/mL. Renal function was conserved. The patient underwent whole body CT scan which revealed multiple nodular masses occupying the entire peritoneal cavity, pelvis and retroperitoneum, ranging from a few millimeters up to 4 cm in the retroperitoneum and 8 cm in the pelvis (Fig. 1). Specifically,

* Corresponding author. Tel.: +39 3337240361.

E-mail address: staderini.fabio@gmail.com (F. Staderini).

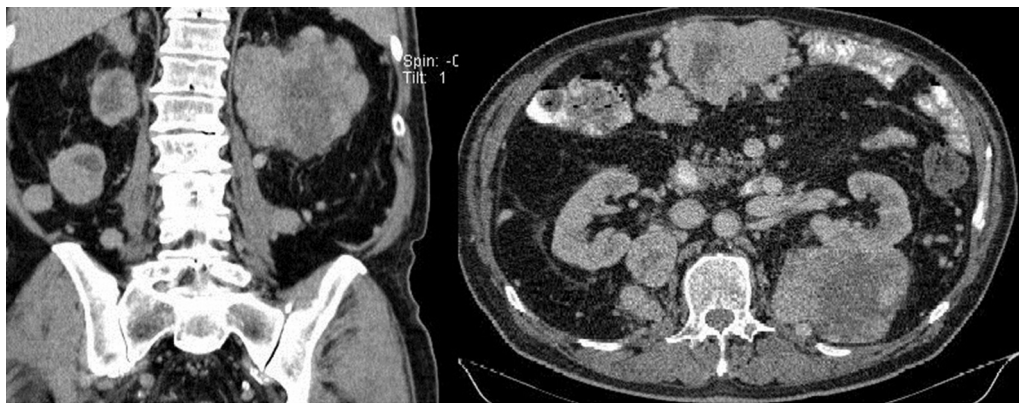

Fig. 1. Abdominal CT scan.

the posterior aspect of the left kidney was occupied by an expansive process penetrating the para- and perirenal space with a maximum transverse diameter of 11 cm. The lungs were involved with lesions of secondary aspect with intense contrast enhancement and subcutaneous tissue was characterized by multiple lumps ranging from 1 to 10 cm. Surprisingly, the liver, pancreas, spleen and bladder were free of pathologic findings.

Following the CT scan, the patient was sent to our department for surgical evaluation. Physical inspection confirmed the presence of palpable masses in the left abdomen and multiple subcutaneous lesions of parenchymatous consistency in the patient's arms, back and chest that he reported as having had for years and that were always considered as benign lipomas. We decided to biopsy one subcutaneous lesion, located in the left chest wall, and histology identified it as clear cell carcinoma of possible renal origin (AE1/AE3+, CDK7–/+, Vimentin+, CD10+, TTF1–).

Although there is no sure evidence of major clinical benefit of surgery in metastatic renal cancer [4] after consulting with the pathologist and the oncologist, we decided to proceed to surgery mainly because of a high risk of bowel obstruction and increasing anemia due to recurrent rectal bleeding. Another purpose was to permit subsequent chemotherapy after massive cytoreduction of the neoplasia with possibly better efficacy [5,6].

The operation performed was an open left nephrectomy with rectosigmoid resection, because of two hypervascularized soft masses of 5 and 7 cm involved in the rectosigmoid junction. We also proceeded with debulking of three omental macrometastases of about 5 cm each (Fig. 2). Peritoneal multiple metastasectomy

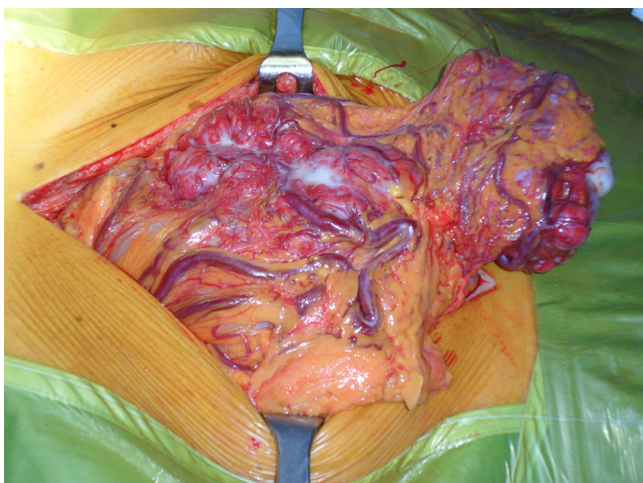


Fig. 2. Omental metastases.

completed the procedure (Fig. 3). No macroscopic radicality (R0) was achieved.

Surgical specimen examination revealed that the posterior of the kidney was completely substituted by a smooth hypervascularized 10 cm mass involving perirenal fat and retroperitoneal space (Fig. 4). Definitive histology confirmed a 10 cm renal clear cell carcinoma infiltrating perirenal fat, the left adrenal gland, omentum, sigmoid colon (Fig. 5), subdiaphragmatic stomas and subcutaneous tissues. The renal pedicle was free of metastatic infiltration as were surgical margins of the excised recto-sigmoid tract; pT4, pNx, pM1 (AJCC, TNM-2010).

The patient was referred to the oncologists for adjuvant chemotherapy. After 6 months of selective multi-target receptor tyrosine kinase inhibitor therapy (Pazopanib), the whole body CT scan demonstrated a diffuse reduction of thoraco-abdominal residual disease. After another 6 months of the same therapy, a new CT scan revealed no dimensional variation in the lesions. Almost 3 years after surgery, the patient is still asymptomatic, receiving home chemotherapy (Sunitinib) and is in good general condition. His most recent CT scan confirmed the stability of his neoplasia.

3. Discussion

Metastatic renal cancer is a relatively common event with more than 30% of patients presenting with a metastasis at the time of diagnosis, even with non-palpable and asymptomatic renal mass. As explained by Krumerman and Garret [7], the pattern of spread is almost always unpredictable, mainly due to deep angioinvasion

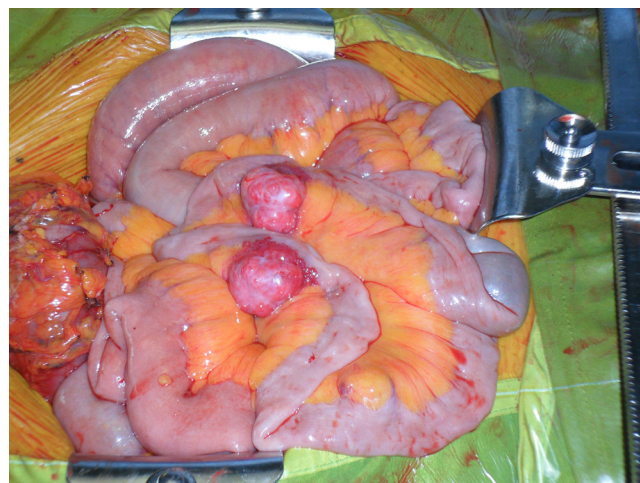

Fig. 3. Mesenteric metastases.

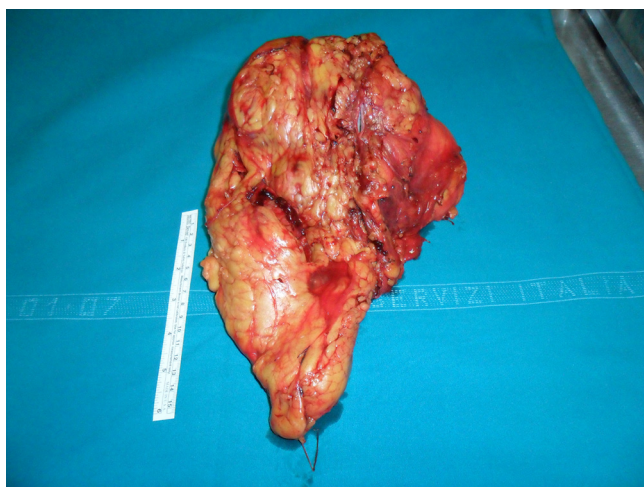

Fig. 4. Left kidney.

and complex lymphatic drainage. However, there is a predilection for certain metastatic sites such as the lung [75%], bone [20%], liver [18%], cutaneous sites [8%] and central nervous system [8%] [3]. As a result, atypical metastases are considered those localized in a site other than thoracic, skeletal, hepatic, adrenal or encephalic [8]. The peritoneum, gut, mesentery and omentum are atypical sites and extremely rare, affecting only 1% of patients with metastatic renal cancer upon autopsy examination. Peritoneal and retroperitoneal diffusion is associated with poor prognosis [9–11]. Our review of the literature was unable to find any cases of indolent diffuse renal cancer simultaneously involving the peritoneum, retroperitoneum, omentum, lung, subcutaneous tissue, colon and adrenal gland but with no liver and bone involvement. Our case is probably one of the first reported. In such cases, it is always challenging to decide which therapy is the best choice, especially when a surgeon is requested to perform a non-codified surgical procedure. The treatment of metastatic renal cancer is still controversial since large series of metastasectomies are reported in the literature, but little is known about the management of metastasis in atypical sites [8,12].

Although there is still no clear consensus about the use of metastasectomy, this would be a valid option, as supported by several studies and recent guidelines [8,4,13] and by the fact that until today, the treatment of metastatic renal carcinoma with systemic therapy has been rather unsuccessful. Recently introduced targeted therapies are problematic because of side effects and their need to

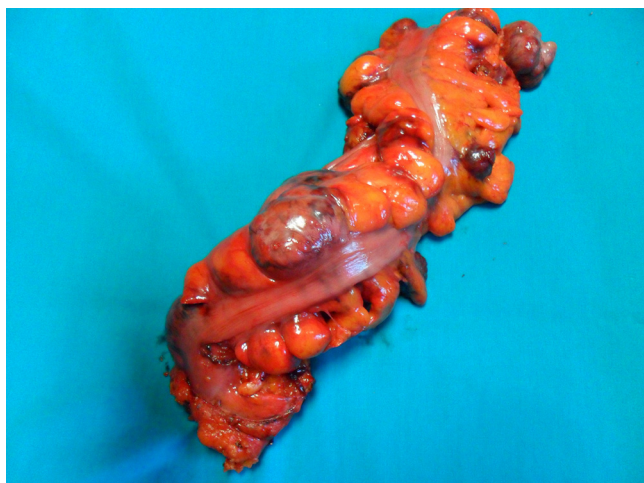

Fig. 5. Sigmoid colon metastases.

be taken for an unlimited period of time [14,15]. Ongoing phase 3 studies on targeted therapies are recruiting patients but the results are premature and require confirmation [16–18].

Cytoreductive metastasectomy associated with nephrectomy is an option but the main limitations are the need of good overall health and functional status of the patient. Patients with a single kidney, poor renal function or caval involvement are not candidates for surgery. In our opinion, there is a rationale for surgery in association with targeted therapies in the treatment of metastatic RCC, although the timing and treatment sequence are still to be established.

Available studies demonstrate the potential of long-term survival after complete surgical resection of multiple metastases in patients with metastatic RCC as well as clinical benefit even with incomplete surgical resection. Five-year survival rates were 45%, 23% and 8% in one series and 49.4%, 23.7% and 8.9% in another series for patients who underwent complete surgical resection, incomplete surgical resection, and no resection, respectively [13,19]. Surgical resection remains a critical mode of achieving control of long-term disease in metastatic RCC patients. However, prospective studies are recommended to define surgical indications.

4. Conclusion

Our case demonstrates the validity of this approach with the clinical evidence of our surgical and medical strategy. We hope that a multidisciplinary approach, with the advent of new targeted therapies, associated with complete surgical resection of the primary tumor and metastases will lead to advanced metastatic RCC becoming a more indolent and chronic disease [20].

Conflicts of interest

No.

Funding

No.

Ethical approval

Yes.

Consent

The patient signed a written consent approving the treatment of his personal medical data for scientific purpose.

Author contribution

Each author contributed in the preoperative, operative or post-operative management of the patient.

Guarantor

Prof. Giuliano Perigli.

References

- [1] Italian tumor register 2012.
- [2] R.L. Siegel, K.D. Miller, A. Jemal, Cancer statistics, 2015, *CA Cancer J. Clin.* 65 (January 1) (2015) 5–29.
- [3] J.D. Maldazys, J.B. deKernion, Prognostic factors in metastatic renal carcinoma, *J. Urol.* 136 (August 2) (1986) 376–379.
- [4] B. Ljungberg, K. Bensalah, S. Canfield, S. Dabestani, F. Hofmann, M. Hora, M.A. Kuczyk, T. Lam, L. Marconi, A.S. Merseburger, P. Mulders, T. Powles, M.

- Stahler, A. Volpe, A. Bex, EAU guidelines on renal cell carcinoma: the 14 update, *Eur. Urol.* 67 (5 January 20) (2015) 917–920.
- [5] T.M. de Reijke, J. Bellmunt, H. van Poppel, S. Marreaud, M. Aapro, EORTC-GU group expert opinion on metastatic renal cell cancer, *Eur. J. Cancer* 45 (March 5) (2009) 765–773.
- [6] R.C. Flanigan, G. Mickisch, R. Sylvester, C. Tangen, H. Van Poppel, E.D. Crawford, Cytoreductive nephrectomy in patients with metastatic renal cancer: a combined analysis, *J. Urol.* 171 (March 3) (2004) 1071–1076.
- [7] M.S. Krumerman, R. Garret, Carcinomas metastatic to the skin, *N.Y. State J. Med.* 77 (October 12) (1977) 1900–1903.
- [8] A. Antonelli, N. Arrighi, S. Corti, S. Legramanti, T. Zanotelli, A. Cozzoli, S.C. Cunico, C. Simeone, Surgical treatment of atypical metastasis from renal cell carcinoma (RCC), *BJU Int.* 110 (December 11 Pt B) (2012) E559–E563.
- [9] F.J. Pérez García, F.J. Regadera Sejas, F.J. Martínez Gómez, J.J. Rodríguez Martínez, J. Casasola Chamorro, M. Martín Fernández, Renal cell carcinoma. Clinical onset with peritoneal carcinomatosis. Report of a case, *Actas Urol. Esp.* 23 (February 2) (1999) 156–159.
- [10] N. Rodríguez García, A.M. García Tello, L. Lanes González, J.M. García Mediero, J. Angulo Cuesta, A. Berenguer Sánchez, Renal carcinoma metastatic to the peritoneum. Case report, *Arch. Esp. Urol.* 59 (November 9) (2006) 919–922.
- [11] V.E. Valdespino-castillo, A. Ruiz-Jaime, Renal cell carcinoma with colon metastases: an infrequent site for metastases, *Cir. Cir.* 76 (July–August 4) (2008) 339–342.
- [12] P. Sountoulides, L. Metaxa, L. Cindolo, Atypical presentations and rare metastatic sites of renal cell carcinoma: a review of case reports, *J. Med. Case Rep.* 5 (September 2) (2011) 429.
- [13] A.L. Alt, S.A. Boorjian, C.M. Lohse, B.A. Costello, B.C. Leibovich, M.L. Blute, Survival after complete surgical resection of multiple metastases from renal cell carcinoma, *Cancer* 117 (13 July 1) (2011) 2873–2882.
- [14] P. Russo, Multimodal treatment for metastatic renal cancer: the role of surgery, *World J. Urol.* 28 (June 3) (2010) 295–301.
- [15] J.A. Karam, B.I. Rini, L. Varella, J.A. Garcia, R. Dreicer, T.K. Choueiri, E. Jonasch, S.F. Matin, S.C. Campbell, C.G. Wood, N.M. Tannir, Metastasectomy after targeted therapy in patients with advanced renal cell carcinoma, *J. Urol.* 185 (February 2) (2011) 439–444.
- [16] L.M. Krabbe, A.Q. Haddad, M.E. Westerman, V. Margulis, Surgical management of metastatic renal cell carcinoma in the era of targeted therapies, *World Journal of Urology* 32 (June 3) (2014) 615–622.
- [17] CARMENA: Clinical trial to assess the importance of nephrectomy.
- [18] SURTIME: Immediate surgery or surgery after sunitinib malate in treating patients with metastatic kidney cancer.
- [19] U.M. Vogl, H. Zehetgruber, M. Dominkus, M. Hejna, C.C. Zielinski, A. Haitel, M. Schmidinger, Prognostic factors in metastatic renal cell carcinoma: metastasectomy as independent prognostic variable, *Br. J. Cancer* 95 (6 September 18) (2006) 691–698.
- [20] J. Larkin, M. Gore, Is advanced renal cell carcinoma becoming a chronic disease? *Lancet* 376 (9741) (2010) 574–575.

Open Access

This article is published Open Access at sciencedirect.com. It is distributed under the [IJSCR Supplemental terms and conditions](#), which permits unrestricted non commercial use, distribution, and reproduction in any medium, provided the original authors and source are credited.