


Available online at www.sciencedirect.com

SciVerse ScienceDirect

www.elsevier.com/locate/amjoto

Hypopharyngeal mucosal flap reconstruction in endoscopic supraglottic laryngectomy

Giuditta Mannelli, MD*, Giampiero Parrinello, MD, Oreste Gallo, MD

First Clinic of Otorhinolaryngology, Head and Neck Surgery, University of Florence, AOU-Careggi, Via Largo Brambilla 3, 50134 Florence, Italy

ARTICLE INFO

Article history:

Received 3 April 2013

ABSTRACT

Purpose: Preservation of voice, swallowing and airway is mandatory in early to moderately advanced supraglottic cancers. Here, we propose an endoscopic laryngoplasty to improve swallowing recovery in patients treated by extended CO₂ laser supraglottic laryngectomy.

Methods: We describe a new mucosal flap reconstruction technique in a cohort of seven laryngeal cancer patients with posterior extension, treated by CO₂ laser resection. Clinical endoscopic and videofluoroscopy postoperative exams were performed, and swallow function was tested by the MD Anderson Dysphagia Inventory (MDADI) questionnaire.

Results: No early complications were observed. Absence of aspiration after two days in all cases was confirmed, and MDADI mean value result was 98.

Conclusions: We suggest the harvest of a hypopharyngeal mucosal flap in all patients who require a laryngeal supraglottic posterior resection, with or without arytenoidectomy.

© 2013 Elsevier Inc. All rights reserved.

1. Introduction

Surgery for early to moderately advanced supraglottic cancer aims for the preservation of voice, deglutition and airway. Surgical organ preservation should be addressed to treat eligible cases; moreover, age of the patient, pulmonary function, family and social structures, as well as comorbidity factors should be considered too.

Partial laryngectomy by laser microsurgery has become in recent years a recognized alternative to transcervical approach for supraglottic laryngeal cancer treatment. The oncological results are comparable to those achieved by classic supraglottic laryngectomy; despite this, endoscopic approach offers several advantages, e.g., tracheotomies are frequently avoided, pharyngocutaneous fistula incidence is reduced, swallowing rehabilitation is faster, aspiration pneumonia are less frequent, and hospitalization is shorter [1–3].

Since supraglottic cancers are often associated to high incidence of regional lymph node metastases, most authors

agree that a selective neck dissection should be performed in patients with stage I and II disease [4,5].

Supraglottic partial laryngectomies require the resection of natural protective barriers, such as epiglottis, aryepiglottic folds and false vocal folds; this could lead towards penetration and/or aspiration in either latent or clinical manifestation. Moreover, surgical resection extended to the tongue base and/or arytenoid cartilage could expose patients to major risk of swallowing disturbances [6].

Although magnification supplied by the microscope and hemostatic cutting/ablation characteristics of the CO₂ laser help in cancer resection precision [7–9], delayed swallowing recovery and aspiration represent the most frequent postoperative complications which occur in endoscopic partial supraglottic surgery for tumors of the posterior supraglottic region, especially in those cases that require arytenoid partial or total removal.

We therefore suggest, in order to minimize these complications and to improve oral-feeding recovery in patients treated by CO₂ laser supraglottic laryngectomy, to perform

* Corresponding author. First Clinic of Otorhinolaryngology, Head and Neck Surgery, University of Florence, AOU-Careggi, Via Largo Brambilla 3, 50134, Florence, Italy. Tel.: +39 0557947988; fax: +39 055435649.

E-mail address: mannelli.giuditta@gmail.com (G. Mannelli).

Table 1 – Clinical characteristics of the seven patients.

Variables	Patients
Number of patients	7
Sex, male:female	6:1
Age, median (range). year	68 (60–79)
TNM classification	
T2N0	6
T2N2a	1
Type of endoscopic resection	
IVa ^a	5
IVb ^a	2
Ipsilateral selective neck dissection	3
MDADI, mean value 5 days after surgery	98
Early complications	
Bleeding with reoperation	0
Vocal fold immobility	0
Upper airway obstruction	0
Aspiration pneumonia	0
Temporary tracheotomy	1

^a In accordance with Remacle et al [11].

endoscopic laryngoplasty when tumor resection is extended to laryngeal posterior regions such as the posterior portion of the ary-epiglottic fold and arytenoid mucosal cap.

2. Materials and methods

The protocol for the prospective controlled clinical study was approved by the institutional review board, and it was conducted in accordance with all accepted standards for human clinical research. All patients gave written informed consent prior to study enrollment. All patients initially diagnosed with T2 squamous cell carcinoma of the supraglottis, according to 2010 American Joint Committee on Cancer (AJCC) guidelines [10], underwent transoral CO₂ laser surgery between September 2011 and February 2012, with associated selective neck dissection (see Table 1). No patient had history of prior surgery or chemioradiotherapy for other head and neck cancers. Patients who did not present a posterior laryngeal tumoral extension, involving structures such as the posterior portion of the ary-epiglottic fold and the arytenoid's mucosal cap, were excluded.

The study cohort consisted of 7 patients (6 men, 1 woman) with median age of 68 years (range 60–79 years). Patients' clinical characteristics are summarized in Table 1.

Clinical exam by indirect flexible and rigid laryngoscopy, together with imaging study (i.e., computed tomography or magnetic resonance exam) helped in preoperative tumor staging, and direct microlaryngoscopy completed the intraoperative diagnostic procedure by endoscopic magnification together with histopathological exam confirming the squamous cell carcinoma nature of the lesion.

Fig. 1 shows two examples of tumor series.

Videofluoroscopy was always performed before surgery in order to identify the presence of a predominant piriform sinus during oral intake.

In a meticulous fashion, all patients underwent, in general anesthesia, direct laryngoscopy, and the laryngoscope was maintained by a chest-torsion holder-stabilizer, which applied the primary force from the chest wall by obtaining an extension at the atlanto-occipital joint and flexion of the neck, in order to achieve a good laryngeal exposure.

Transoral laser microsection of the tumor was performed in accordance with the Remacle et al. classification of endoscopic supraglottic laryngectomy [12] (Table 1) (Fig. 2A). After having ruled out tumor infiltration of surgical resection margins by intraoperative frozen section histopathological analysis, a posterior laryngoplasty was performed. A posterior-based medial wall of piriform sinus cold-instrument microflap was harvested on the same side of the posterior resection (Fig. 2B). The healthy unfurled mucosal flap was rotated anteriorly in order to allow its advancement and affixed with one or two stitches 6.0 PDS passing through paraglottic space in order to cover the exposed cartilage or the posterior surgical defect (Fig. 2C).

Suture placement is facilitated by enhanced laryngoscopic exposure as well as the fact that paraglottic mucosa is preserved and stable to be penetrated by a small needle and suture without tearing [13].

This approach re-establishes the normal mucosal cover of the residual arytenoid cartilage preserved; moreover, it helps in keeping open the ipsilateral piriform sinus creating a physiological feeding chute and guarantees the preservation of posterior respiratory space without adversely affecting vocal fold mobility.

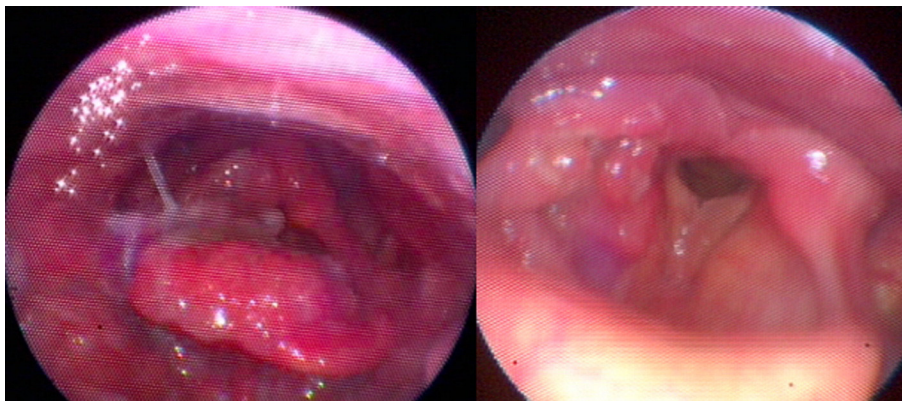


Fig. 1 – Two examples of laryngeal supraglottic cancers.

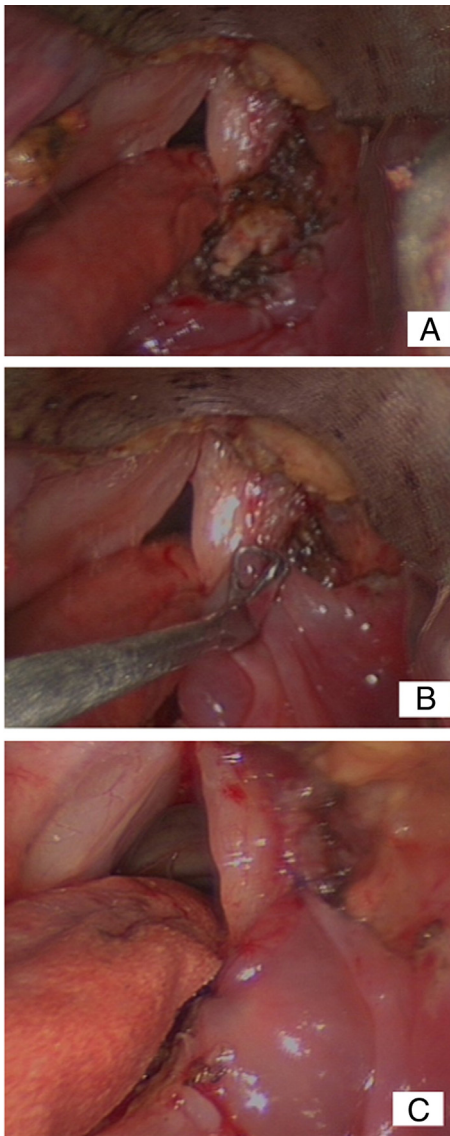


Fig. 2 – Surgical steps of hypopharyngeal flap harvested after having obtained transoral laser microsection of the tumor; here an endoscopic supraglottic laryngectomy, type IVa, was performed in accordance with Remacle et al [11]. (A) Arytenoid cartilage is seen. (B) A posterior-based medial wall of piriform sinus cold-instrument microflap was developed. (C) The healthy mucosal flap is rotated and affixed in an anterior position with 6-0 PDS suture.

Two surgeons independently judged wound healing, vocal fold mobility and swallow function by MD Anderson Dysphagia Inventory (MDADI) questionnaire and thickened water test under endoscopic view during the recovery since the first postoperative day (Fig. 3).

We performed temporary tracheotomy only in one case (number 7, Table 1) because the body mass index (BMI) of the patient was higher than 32.

All patients were fed through nasogastric feeding tube, and mean time of removal was 6 days (range 1–12 days).

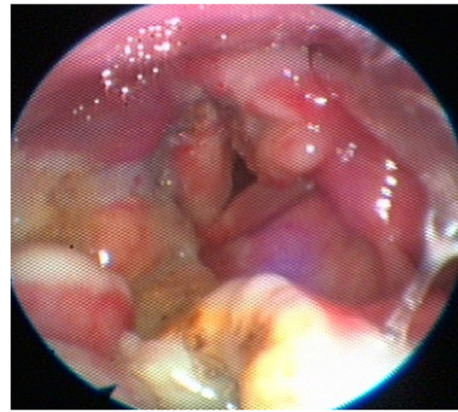


Fig. 3 – Endoscopic view during the first post-surgery day.

3. Results

All lesions were completely removed at the initial surgery as confirmed by pathological analysis. Enhanced exposure of the medial wall of the piriform sinus was achieved in all cases, which allowed its surgical management. This procedure has been done seven times, and we observed a good function of the healthy mucosal flap during the recovery, without any type of early complications. All patients started swallowing exercises with thickened liquids since one day after surgery, and videofluoroscopy exam confirmed the absence of aspiration after two days in all cases; all patients did not complain of any swallowing problems with oral intake after nasogastric feeding tube removal. MDADI results were always above 90 as a global score since the second day after surgery (Table 1).

Surgical wound recovered fast and healed within 3–6 weeks without any major complications including infection, necrosis and hemorrhage. Fig. 4 shows the final clinical result 8 weeks later after surgery.

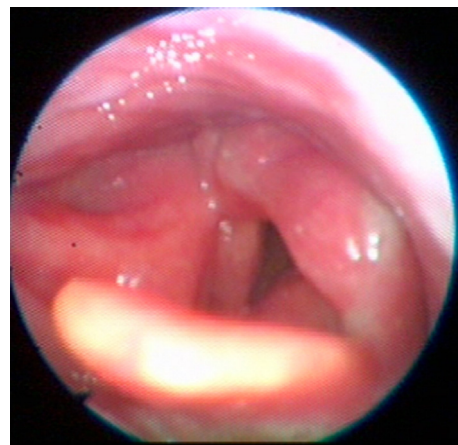


Fig. 4 – Endoscopic view after 8 weeks post-surgery.

4. Discussion

Complications occurring during or after laser microsurgery resection of supraglottic laryngeal tumors could be serious and sometimes fatal problems, more difficult to manage than in open laryngeal surgery [11,14]. In fact, patients with dysphagia or compromised airway protection present a major risk for postoperative consequences.

There are many advantages in performing CO₂ laser endoscopic surgery instead of traditional open procedures for the treatment of supraglottic carcinoma; despite this, transoral technique removes a large portion of the protective anatomy of the upper airway, which could result into a feared postoperative complication such as dysphagia. This supraglottic tissue loss may lead to improper timing of upper esophageal relaxation, which further lead to possible aspiration. Moreover, when dysphagia persists, patients need swallowing rehabilitation and keep on feeding through nasogastric tube also after discharge.

Regarding our cases, functional results were evaluated by the MD Anderson dysphagia test which showed a global good dysphagia index (see Table 1) and surgery have been well tolerated by all patients. In case of use of the predominant piriform sinus mucosa to perform the hypopharyngeal flap, we did not observe any significant changes in dysphagia results.

Despite that literature describes a mean time of removal of nasogastric-feeding tube within approximately the seventh postoperative day in this type of endoscopic surgery [6], we report a faster swallowing rehabilitation with a lower mean value of days of feeding through naso-gastric tube.

To the best of our knowledge, this type of microflap has not been previously described. An advancement-rotation mucosal microflap is successful when normal glottal mucosa is preserved and medial piriform sinus wall is not involved by the tumor. This procedure did not increase the duration of general anesthesia. Voice quality remains intact, even if the supraglottic mucosal edema during the first post-operative days could disguise the final voice outcome; on the other hand, it may help in avoiding aspiration. In addition, the microflap guarantees a wide and stable glottic posterior space.

In conclusion, according to our results, we suggest to harvest a mucosal flap in all patients who require a laryngeal supraglottic posterior resection, with or without arytenoidectomy. This procedure could be performed also in non oncological laryngeal diseases, i.e., bilateral adduction of vocal fold after total thyroidectomy, or after radiotherapy or other similar causes.

Acknowledgments

This manuscript is approved by all authors and all of them have participated in writing and correcting this work. Further, all authors assure that manuscript has not been published nor under approval by other journals or editors, and they have not any conflict of interest, financial or otherwise.

REFERENCES

- [1] Iro H, Waldfahrer F, Altendorf-Hofmann A, et al. Transoral laser surgery of supraglottic cancer: follow-up of 141 patients. *Arch Otolaryngol Head Neck Surg* 1998;124:1245-50.
- [2] Ambrosch P, Kron M, Steiner W. Carbon dioxide laser microsurgery for early supraglottic carcinoma. *Ann Otol Rhinol Laryngol* 1998;107:680-8.
- [3] Zeitels SM, Vaughan CW, Domanowski GF. Endoscopic management of early supraglottic cancer. *Ann Otol Rhinol Laryngol* 1990;99:951-6.
- [4] Myers EN, Alvi A. Management of carcinoma of the supraglottic larynx: evolution, current concepts, and future trends. *Laryngoscope* 1996;106:559-67.
- [5] Chiu RJ, Myers EN, Jhonson JT. Efficacy of routine bilateral neck dissection in the management of supraglottic cancer. *Otolaryngol Head Neck Surg* 2004;131:485-8.
- [6] Prgomet D, Bumber Z, Bilic M, et al. Videofluoroscopy of the swallowing act after partial supraglottic laryngectomy by CO₂ laser. *Eur Arch Otolaryngol* 2002;259:399-403.
- [7] Jako GJ, Kleinsasser O. Endolaryngeal micro-diagnosis and microsurgery. Reprint from the Annual Meeting of the American Medical Association 2006.
- [8] Jako GJ. Laser surgery of the vocal cords. *Laryngoscope* 1972;82:2204-15.
- [9] Strong MS, Jako GJ. Laser surgery of the larynx: early clinical experience with continuous CO₂ laser. *Ann Otol Rhinol Laryngol* 1972;81:791-8.
- [10] American Joint Committee on Cancer (AJCC). *Manual for Staging of Cancer* 7th edition. New York: Springer-Verlag; 2010.
- [11] Ellies M, Steiner W. Peri- and postoperative complications after laser surgery of tumor of the upper aerodigestive tract. *Am J Otolaryngol* 2007;28:168-72.
- [12] Remacle M, Hantzakos A, Eckel H, et al. Endoscopic supraglottic laryngectomy: a proposal for a classification by the working committee on nomenclature, European Laryngological Society. *Eur Arch Otorhinolaryngol* 2009;266:993-8.
- [13] Deganello A, Gallo O, Gitti G, et al. New surgical technique for endoscopic management of anterior glottic web. *B-ENT* 2010;6:261-4.
- [14] Vilaseca-Gonzalez I, Bernal-Sprekelsen M. Complication in transoral CO₂ laser surgery for carcinoma of the larynx and hypopharynx. *Head Neck* 2003;25:382-8.