



UNIVERSITÀ
DEGLI STUDI
FIRENZE

FLORE

Repository istituzionale dell'Università degli Studi
di Firenze

**Cyclooxygenase-2 and Inflammation Mediators Have a Crucial Role in
Reflux-Related Esophageal Histological Changes and Barrett's**

Questa è la Versione finale referata (Post print/Accepted manuscript) della seguente pubblicazione:

Original Citation:

Cyclooxygenase-2 and Inflammation Mediators Have a Crucial Role in Reflux-Related Esophageal Histological Changes and Barrett's Esophagus / Taddei A; Fabbroni V; Pini A; Lucarini L; Ringressi MN; Fantappiè O; Bani D; Messerini L; Masini E; Bechi P. - In: DIGESTIVE DISEASES AND SCIENCES. - ISSN 0163-2116. - ELETTRONICO. - 59:(2014), pp. 949-957. [10.1007/s10620-013-2975-4]

Availability:

This version is available at: 2158/848116 since: 2016-11-22T15:20:26Z

Published version:

DOI: 10.1007/s10620-013-2975-4

Terms of use:

Open Access

La pubblicazione è resa disponibile sotto le norme e i termini della licenza di deposito, secondo quanto stabilito dalla Policy per l'accesso aperto dell'Università degli Studi di Firenze (<https://www.sba.unifi.it/upload/policy-oa-2016-1.pdf>)

Publisher copyright claim:

(Article begins on next page)

Cyclooxygenase-2 and Inflammation Mediators Have a Crucial Role in Reflux-Related Esophageal Histological Changes and Barrett's Esophagus

Antonio Taddei · Valentina Fabbroni · Alessandro Pini ·
Laura Lucarini · Maria Novella Ringressi · Ornella Fantappiè ·
Daniele Bani · Luca Messerini · Emanuela Masini · Paolo Bechi

Received: 22 July 2013 / Accepted: 25 November 2013 / Published online: 20 December 2013
© Springer Science+Business Media New York 2013

Abstract

Background Gastroesophageal reflux (GER) causes injury of the esophageal squamous epithelium, a condition called reflux esophagitis. The sequence reflux-esophagitis-intestinal metaplasia-dysplasia-invasive cancer is widely accepted as the main adenocarcinogenetic pathway in the esophagus; however, the mechanisms of this progression need to be better defined.

Aims We evaluated COX-2 expression and activity in biopsies from patients affected with GER, and these parameters have been correlated with the stage of the disease, ceramide expression, apoptotic process, and angiogenesis. The effects of celecoxib on bile acid- and EGF-induced mucosal proliferation, apoptosis and angiogenesis have been also investigated.

Methods Four groups of patients were distinguished: non esophagitis, non erosive esophagitis, erosive esophagitis, and Barrett's esophagus. COX-2 expression, basal PGE₂ levels, proliferative activity, VEGF expression and apoptosis were evaluated in esophageal biopsies.

Results COX-2 expression, basal PGE₂ levels, proliferative activity, VEGF expression and apoptosis progressively

increase from non esophagitis patients to patients with non erosive and erosive esophagitis, to those with BE. Incubation of the cells with DCA/EGF increases PGE₂ production, proliferative activity and VEGF production, effects prevented by celecoxib pretreatment. Ceramide expression increased from non esophagitis patients to patients with non erosive and erosive esophagitis, and decreased in BE; caspase-3 activity progressively decreased from non esophagitis to BE patients, suggesting an impairment of the apoptotic process with disease progression.

Conclusion These results stand for a close relationship between progression of initial steps of gastroesophageal reflux disease (GERD) and COX-2, proliferative activity and EGF/VEGF expression and could have implications in GERD treatment in order to prevent its neoplastic evolution.

Keywords GERD · Barrett's esophagus · COX-2 · Celecoxib · VEGF · Apoptosis

Introduction

Two isoforms of cyclooxygenase enzyme (COX) have been identified. COX-1 is considered a housekeeping gene and is constitutively expressed in most normal tissues, whereas COX-2 is an inducible enzyme, which can be rapidly induced by cytokines, inflammatory mediators, growth factors and tumour promoters and is related to human inflammatory diseases and carcinogenesis in different tissues [1–5]. A large body of evidence suggests that induction of COX-2 plays a pivotal role in cancer development by promoting cell proliferation, decreasing apoptosis rate, stimulating angiogenesis and increasing invasive

A. Taddei · M. N. Ringressi · P. Bechi (✉)
Department of Surgery and Translational Medicine, Section of
General Surgery, University of Florence-Careggi General
Hospital, AOU Careggi, Largo Brambilla n. 3,
50134 Florence, Italy
e-mail: paolo.bechi@unifi.it

V. Fabbroni · L. Lucarini · E. Masini
Department of NEUROFARBA, Section of Pharmacology,
University of Florence-Careggi General Hospital, Florence, Italy

A. Pini · O. Fantappiè · D. Bani · L. Messerini
Department of Experimental and Clinical Medicine, University
of Florence-Careggi General Hospital, Florence, Italy

and metastatic potential of the primary tumour [6–9]. A role of COX-2 in carcinogenesis is also indirectly supported by a wealth of epidemiological data which have shown an association of the long-term use of non steroidal anti-inflammatory drugs (NSAIDs) with a decreased incidence of colorectal, gastric and oesophageal cancers [10]. The mechanism by which NSAIDs exert this possible cancer-preventing effect remains unclear; however, it is well known that the target of these drugs is COX and its effects on the metabolism of arachidonic acid to the various biologically active prostaglandins [11].

Gastroesophageal reflux (GER) often causes peptic injury and inflammation of the esophageal squamous epithelium, a condition called reflux esophagitis. Esophagitis in most cases heals through the regeneration of squamous cells in the distal oesophagus. Conversely, in some patients esophagitis heals through a columnar-metaplastic process, which seems to represent a temptatively protective reaction to reflux injury since the metaplastic epithelium is more resistant to the noxious agents than the native tissue. In a minority of these cases intestinal-type columnar cells are represented; this condition is called Barrett's esophagus (BE) and represents the most common esophageal precancerous lesion.

The sequence of events—reflux-esophagitis-intestinal metaplasia-dysplasia-invasive cancer—is widely accepted as the main carcinogenetic pathway in the esophagus. However, the fine mechanisms which underlie this progression need to be defined. In this respect, COX-2 has been widely studied and its involvement in some of the different steps of the sequence deeply investigated. It has been recently shown in *ex vivo* experiments that reflux components, acid and/or “alkaline” can affect COX-2 expression in isolated cells from BE and a relationship between COX-2 induction, dysplasia and adenocarcinoma has also been reported [12]. Moreover, in rats COX-2 inhibitors reduce inflammation and tendency to develop reflux-induced adenocarcinoma [13]. Clinical data suggest that alterations in the susceptibility to apoptosis underlie the neoplastic progression of Barrett's esophagus. In fact, in biopsy samples of Barrett's epithelium, altered staining for the antiapoptotic protein Bcl-2 and Bcl-xL has been found as metaplasia progresses through dysplasia to adenocarcinoma [14]. Moreover, COX-produced prostanoids have been shown to affect ceramide, an ubiquitous sphingolipid messenger that plays an important role in inflammation and in control of tumour cell fate [15].

In man, the only unexplored aspect of COX-2 in esophageal adenocarcinogenesis is represented by the earliest steps of the process and concerns the role of COX-2 induction, in the step from GER to esophagitis. In the present study we evaluated COX-2 expression and activity in biopsies of patients affected with gastroesophageal

Table 1 Characteristics of study cohort (33 patients)

Characteristic	Number (%)
Gender	
Male	20 (60.6)
Female	13 (39.4)
Endoscopic evidences	
Cardial incompetence	8 (24.2)
Pyloric incompetence	7 (21.2)
Hiatal hernia	8 (24.2)
Metaplastic columnar epithelium	13 (39.4)
Gastritis	2 (6.1)
Esophagitis	7 (21.2)
Reflux induced micropapilloma	1 (3.0)
Histopathological analysis (grade of esophagitis)	
Non esophagitis	5 (15.2)
Non erosive esophagitis	11 (33.3)
Erosive esophagitis	11 (33.3)
Barrett's esophagus	6 (18.2)

reflux disease (GERD) and these parameters were correlated with the stage (particularly the first steps) of the disease and with the apoptotic process and angiogenesis. Moreover, apoptosis, angiogenesis and the effects of a COX-2 inhibitor on bile acid and EGF-induced mucosal proliferation were also investigated.

Methods

Patients and Tissue Collection

Thirty-three patients (20 males; 13 females; median age 57.78, age range 21–81 years) undergoing upper endoscopy due to reflux symptoms (heartburn and/or regurgitation) and/or previous documented diagnosis of GERD were included in the study (Table 1). None of the patients had taken either NSAIDs or proton pump inhibitors (PPIs) in the last 2 months before endoscopy. All of them were thoroughly informed about the study and gave their written consent for the investigation according to the guidelines of the Ethical Committee of the University of Florence-Carreggi General Hospital.

In each of the patients three adjacent biopsy samples were taken in the oesophagus immediately above the gastroesophageal junction by means of grasp forceps during the endoscopic examination. One of the samples was fixed in 4 % formaldehyde for conventional histological and immunohistochemical evaluation. The two other biopsies were divided in half using an aseptic technique and washed in cold phosphate buffered saline (PBS). They were immediately frozen at -80°C until use for molecular analysis.

Histopathology

The formalin-fixed biopsies were routinely processed, paraffin embedded and stained with hematoxylin and eosin in order to evaluate esophagitis grading and BE using a standard light microscope. The findings of one or more alterations such as basal cell hyperplasia, elongation of the papillae, dilatation of the intercellular spaces, and scattered intraepithelial eosinophils were identified as macroscopic esophagitis without erosions. The finding of erosions or ulcers of the squamous epithelium, with or without intraepithelial neutrophils was identified as microscopic erosive esophagitis. For the diagnosis of BE it was considered mandatory that the histological presence of intestinal metaplasia occurred in an endoscopically visible columnar-lined oesophagus. Patients with none of the just mentioned histological characteristics were considered as patients without histological esophagitis although symptomatic for GER.

Immunostaining for COX-2, MIB-1

Immunohistochemical studies were performed on 4- μ m representative paraffin embedded tissue sections from each case, using the streptavidin–biotin immunoperoxidase complex method. Endogenous peroxidase activity was blocked by immersion in 3 % (v/v) hydrogen peroxide for 20 min. Sections were pre-treated in a microwave oven for 15 min in 10 mmol/L citrate buffer (pH 6.0) before immunostaining. The following antibodies were used: polyclonal antibody anti-COX-2 (Santa Cruz Biotechnology, CA, USA) at 1:100 dilution at room temperature for 1 h and MIB-1 monoclonal antibody (Immunotech, Marseille, France) at 1:100 dilution for 12 h at room temperature. Coloration was performed using diaminobenzidine (Bio-Genex, San Ramon, CA, USA).

MIB-1 value was determined counting 1,000 epithelial cells in ten randomly selected fields by a standard light microscope with an oil immersion objective (magnification 1,000 \times) and the results were expressed as a percentage of positive cells. For ceramide expression, tissue sections were treated with 3 % (v/v) hydrogen peroxide in water, to quench endogenous peroxidase, and incubated overnight with mouse monoclonal antibody anti-ceramide (clone MID 15B4, Alexis Biochemicals, working dilution 1:10 in PBS). Immune reaction was revealed by indirect immunoperoxidase method (Vectastain Elite kit, Vector, Burlingame, CA, USA), using 3,3'-diaminobenzidine as chromogen. As negative controls, sections incubated with only the primary or the secondary antisera were used. In each section, the number of ceramide positive cells were counted in ten randomly chosen microscopical fields at a 200 \times final magnification (test area, 72,346 μ m²).

Two of the authors (L.M. and D.B.) independently evaluated the immunostained specimens.

The extent of immunostaining for COX-2 was recorded semi-quantitatively. For this purpose staining of HT29 colon cancer cell line was considered as 100 % [16]. Study specimens staining was graded using a 3-grade system, based on the percentage of stained tumour epithelial cells: grade 0 = 1–20 %; grade 1 = 21–70 %; grade 2 = more than 70 % [17].

Mucosal Cell Cultures and Drugs

Samples were cultured as described by Shirvani et al. [12]. Briefly, mucosal biopsy specimens were placed on a sterilized stainless wire mesh within a Falcon center-well organ culture dish (DB Biosciences, NJ, USA) so that 1 ml of cultured medium just covered the surface of the biopsy. Organ culture dishes were then placed on racks in an incubator chamber oxygenated with 95 % O₂ and 5 % CO₂ at 37 °C. Cell culture was performed in RPMI 1640 supplemented with 10 % fetal calf serum in the presence of glutamine (2 mM), glucose (3.66 mg/mL), 500 units/mL streptomycin, and 250 units of penicillin. Mucosal biopsies were first equilibrated in the culture medium for 2 h, then washed twice and cultured in a fresh medium for further 24 h and finally utilized for the experiments. Deoxycholic acid (DCA) and epidermal growth factor (EGF) were purchased from Sigma (St. Louis, MO, USA); celecoxib was kindly provided by Monsanto (St. Louis, MO, USA).

Cell Viability Assay

The 3-(4,5-dimethylthiazol-2-yl)-2,5 diphenyltetrasolium bromide (MTT) assay was used to determine cell viability. MTT is a yellow-coloured tetrazolium salt that is taken up and cleared only by metabolically active cells, which reduce it to a coloured, water-insoluble formazan salt. The solubilized formazan product is quantified via absorbance at 750 nm, which is measured using a 96-well-format spectrophotometer. The absorbance correlates directly with the cell number. The basal viability of the cells obtained from the tissue fragment was 85–88 %. A significant loss in cell viability was only observed after the treatment both with DCA and celecoxib at concentrations >25 μ mol/L. Therefore, the experiments were done using non cytotoxic doses of drugs (1 μ mol/L).

Cell Proliferation Assay

Cell proliferation was determined by the ³[H]-thymidine incorporation assay in order to evaluate DNA synthesis. Briefly, cells from esophageal biopsy cultures were seeded in 24-well plates and maintained in DMEM medium for

24 h. After a 24-h incubation at 37 °C in a 5 % CO₂ atmosphere in steady-state medium (i.e. medium supplemented with 1 % FCS), the culture medium was replaced with 200 µL fresh culture medium containing 10 % FCS, with or without 1 µM DCA or 1 µM EGF. Cells cultured solely in media served as negative controls. After 24 h of incubation the cells were pulsed for 4 h with methyl-³[H] thymidine, 0.5 µCi per well (Amersham, UK; specific activity, 50 Ci/mmol).

The medium was then removed and DNA was precipitated with cold 3 % trichloroacetic acid and extracted with 1 mL of 0.3 N NaOH. The recovered radioactivity was measured in a β-counter (model 1900 TR; Packard Tricarl, Zurich, Switzerland). The experiments, when possible, were performed in duplicate and the values expressed as pmol/µg protein (mean ± SE).

COX-2 and VEGF Protein Expression

Tissue samples were processed as described previously [16]. The samples were mixed 1:1 with sample buffer/20 mmol/L Tris–HCl, pH 6.8, 20 % glycerol, 2 % sodium dodecyl sulphate (SDS), 5 % β-mercaptoethanol, and 0.025 % bromphenol blue. SDS-polyacrylamide gel electrophoresis (PAGE) was performed using 8 and 5 % acrylamide for the separating gel and the stacking gel, respectively. Proteins were transferred onto nitrocellulose membranes (Pierce, Chemical Co., IL, USA). Blots were blocked with bovine serum albumin 5 % in PBS (Pierce Chemical Co., IL, USA) and incubated overnight at 4 °C with human anti COX-2 and anti VEGF goat polyclonal antibodies and anti COX-1 monoclonal antibodies (Cayman Chemical Co., MI, USA) at 1:1,000 dilution; goat polyclonal anti-actin antibody (1:100, Santa Cruz Biotechnology, CA, USA) was used as standard. Blots were additionally incubated with secondary antibodies conjugated with horseradish peroxidase (1:5,000, Amersham, UK) for 2 h at room temperature and, finally, incubated with SuperSignal West Pico Chemiluminescent Substrate (Pierce, Chemical Co., IL, USA) for 5 min and then exposed to CL-X exposure film (Pierce, Chemical Co., IL, USA).

Prostaglandin E₂ (PGE₂) and Vascular Endothelial Growth Factor (VEGF) Production

Supernatants (100 µL each) were utilized for PGE₂ and VEGF determination using competitive enzyme immunoassay kits (Cayman Chemical Co, Ann Arbor, MI, USA) according to methods previously described (Cianchi et al. [8]). Celecoxib, 1 µmol/L, was added 30 min before adding EGF or DCA at 1 µM concentration. After 24 h of incubation, the supernatants were collected and prepared

according to the method described previously [16]. Determinations were performed in duplicate. PGE₂ and VEGF values were expressed as pg per mg and µg protein, respectively.

Protein concentration was determined according to the method described by Lowry et al. [18]; bovine serum albumin (BSA) was used as standard.

Determination of Caspase-3 Activity

The activity of caspase-3 (an index of cell susceptibility to apoptosis) was determined by the use of a fluorescent substrate following Stennicke and Salvesen [19]. The Ac-Asp-Glu-Val-Asp-AMC (AC-DEVD-ANC; Bachem) was used as a fluorescent substrate for caspase-3 [20].

Briefly, the frozen tissue samples were homogenized with 10 mM *N*-2-hydroxymethylpiperazine-*N*-2-ethansulfonic acid (HEPES, pH 7.4) containing 0.5 % [(3-cholamidopropyl) dimethylamino]-1-propane-sulfonate (CHAPS), 42 mM KCl, 5 mM NaCl₂, 1 mM dithiothreitol (DTT), 1 mM phenylmethylsulfonyl fluoride (PMSF), 2 µg/mL leupeptin and 1 µg/mL pepstatin A.

The homogenate was then centrifuged at 10,000g for 10 min. The activity of caspase-3 was determined in the supernatant by fluorometric assay using the substrate, AC-DEVD-AMC. Supernatant (containing about 70–80 µg total protein) was incubated with 40 µM of the caspase-3 substrate AC-DEVD-AMC for 60 min at 37 °C. At the end of incubation, substrate cleavage was monitored fluorometrically with a λ excitation at 380 nm and λ emission at 460 nm. Data are expressed as arbitrary mU/µg proteins. One unit of enzyme activity is defined as the amount of enzyme required to liberate 40 µmol of AC-DEVD-AMC for 60 min at 37 °C.

Statistical Analysis

The values were expressed as mean ± standard error (SE). Statistical analysis was done using GraphPad Prism Statistical (release 5.0; GraphPad Software Inc. CA, USA) using ANOVA analysis. P-values were calculated with the use of either one- or two-sided statistical tests, when not otherwise specified the one-way test was used; *p* < 0.05 was considered statistically significant.

Results

Patients

On the basis of the histopathologic findings of the endoscopic biopsy samples, four groups of symptomatic patients were distinguished: (1) five non esophagitis, (2)

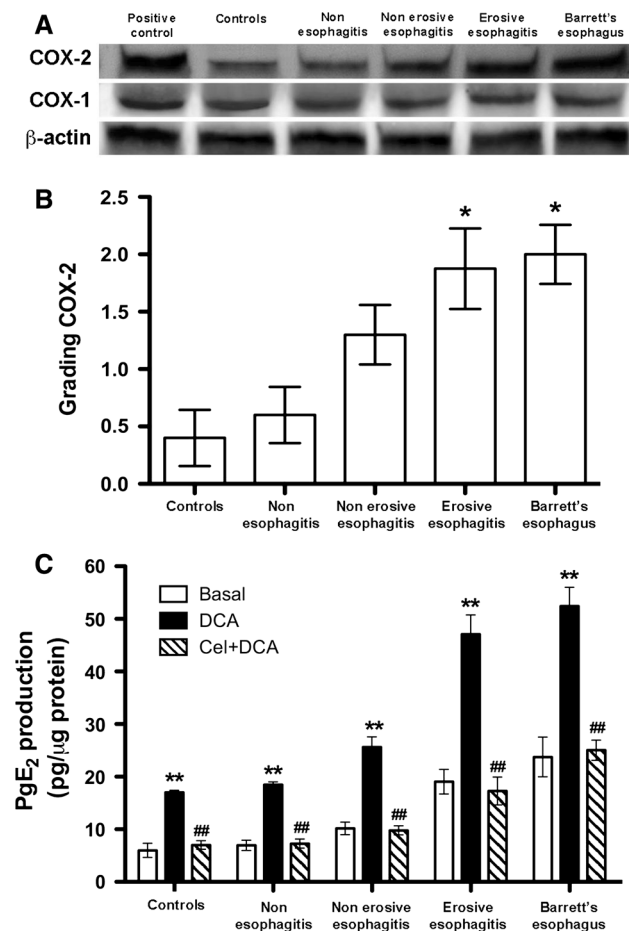


Fig. 1 Western blot analysis of COX-2 and COX-1 proteins in human specimens from controls, non esophagitis, non erosive and erosive esophagitis and BE patients. The samples were normalized with β -actin (a). The grading of COX-2 (b) showed significant differences (* $p < 0.05$) both in erosive esophagitis and BE patients when compared to controls and non esophagitis patients. COX-2 activity, evaluated as PGE₂ production (mean values \pm SEM) in the supernatant of tissue fragments before (basal) and after 24 h incubation with 1 μ M DCA (c). DCA incubation significantly increased PGE₂ production with significant differences when compared to basal levels in all the groups (two-way ANOVA, ** $p < 0.01$). Celecoxib pre-incubation (1 μ M) for 1 h reverted PGE₂ production to basal levels in all the groups (two-way ANOVA, ## $p < 0.01$)

11 non erosive esophagitis, (3) 11 erosive esophagitis, and (4) six BE (Table 1). Moreover, five patients undergoing endoscopy without symptoms and any endoscopic findings of GER were studied and considered as controls.

COX-1 and COX-2 Expression and PGE₂ Production

COX-2 expression in the biopsies, detected by Western blotting (relative molecular weight 72 kD), showed an increasing trend with the progression of the disease, whereas COX-1 expression (relative molecular weight 66 kD) is not different in the four groups (Fig. 1, panel A).

COX-2 staining increased with the stage of the disease; the mean values (\pm SE) of COX-2 grading of immunostaining are indicated in Fig. 1, panel B.

Basal PGE₂ production gradually increased accordingly with the progression of the disease, indicating a relevant COX-2 activation in erosive esophagitis and BE. PGE₂ basal values were significantly different in BE and erosive esophagitis groups when compared to non esophagitis patients and controls ($p < 0.05$) (Fig. 1, panel C).

A significant enhancement of PGE₂ in the supernatants is observed in each group after 24-h incubation of the cells with 1 μ M DCA when compared to basal levels ($p < 0.001$, two-way ANOVA). The pre-incubation of the cells for 60 min with 1 μ M celecoxib, a COX-2 selective inhibitor, prevented DCA-mediated increase in PGE₂ production (Fig. 1, panel C). The latter finding supports COX-2 as the main source of PGE₂ after DCA stimulation.

Cell Proliferative Activity

³[H]-thymidine incorporation showed an increasing trend accordingly with the stage of the disease. Basal levels of thymidine incorporation in BE was significantly different when compared to controls and the non esophagitis group ($p < 0.01$) (Fig. 2, panels A and B).

Twenty-four hour incubation of the cells both with DCA (1 μ M) (Fig. 2, panel A) or EGF (1 μ M) (Fig. 2, panel B) significantly stimulated the incorporation of ³[H]-thymidine in all the groups ($p < 0.01$ when compared with the respective basal values). Pretreatment with 1 μ M celecoxib did not affect the basal levels of ³[H]-thymidine incorporation, as reported in Fig. 2, whereas it almost completely prevented the effects of the two proliferative stimuli, confirming the COX-2 role in the enhancement of cell proliferation due both to DCA and EGF (Fig. 2, panels A and B).

MIB-1 was significantly over-expressed in non erosive, erosive esophagitis and BE patients when compared to controls and non esophagitis patients (* $p < 0.05$, ** $p < 0.01$ and *** $p < 0.001$ respectively) and gradually increased accordingly with the severity of the disease (Fig. 3, panels A and B).

These findings support the above-mentioned results concerning ³[H]-thymidine incorporation and confirm a link between the progression of the disease and cell proliferation.

VEGF Protein Expression and VEGF Production

The expression of VEGF correlated with the stage of the disease. In fact, both protein expression and VEGF production increased with the progression of the disease (Fig. 4, panels A and C, respectively). The production of

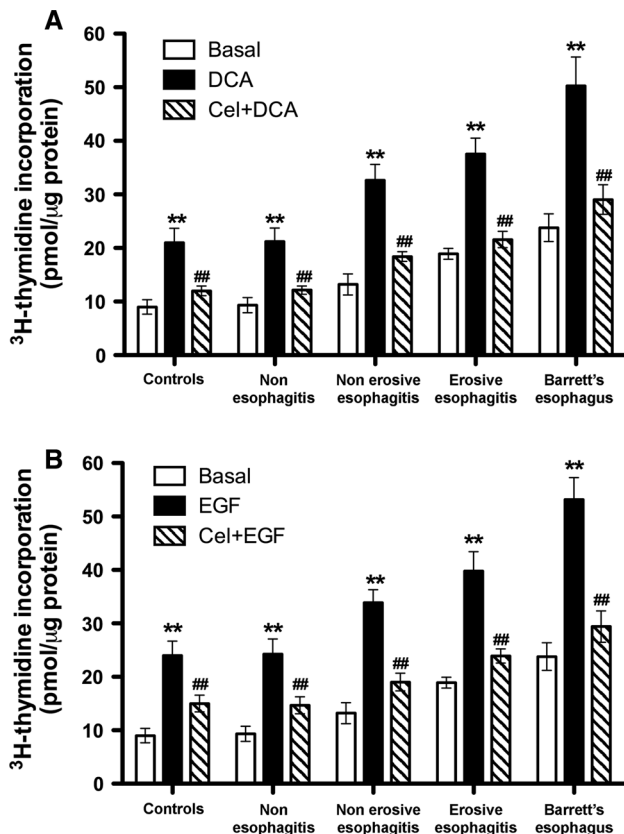


Fig. 2 ^3H thymidine incorporation in all studied groups (**a**, **b**). The basal and both DCA- (**a**) and EGF- (**b**) stimulated proliferative activity increased with the progression of the disease. Differences were significant between each group and the preceding one (two-way ANOVA, $**p < 0.001$). Pre-treatment of the cells with celecoxib significantly inhibited proliferation induced by DCA or EGF (two-way ANOVA, $##p < 0.001$)

VEGF in non erosive, erosive esophagitis and BE was significantly different from both controls and non esophagitis patients. Again pre-treatment of the cells with $1\ \mu\text{M}$ celecoxib prevents the DCA-induced increase in VEGF production (Fig. 4, panel C).

Caspase-3 Activity and Ceramide Expression as an Index of Apoptosis

Caspase-3 activity progressively decreased from non esophagitis to BE (Fig. 5, panel A), suggesting a progressively increasing impairment of the apoptotic process with the progression of the disease. When BE mucosal biopsies were cultured in the presence of $1\ \mu\text{M}$ celecoxib the activity of caspase-3 increases from 169.75 ± 27 to 295.38 ± 42 mU/ μg protein ($p < 0.01$). This finding confirms the pro-apoptotic effect of COX-2 inhibitors and a role for COX-2 through the inhibition of apoptosis in BE. The results of the assessment of ceramide expression are shown in Fig. 5, panel B. The

number of ceramide positive cells increased from non esophagitis to non erosive and erosive esophagitis, but it was low in BE.

Discussion

Our results clearly demonstrate the involvement of COX-2 in the pathogenesis of the reflux-related earliest histological modifications and therefore in the initial steps of the esophageal adenocarcinogenetic pathway. This datum represents a novelty in man and may have some important clinical implications.

It is well established that COX-2 plays a relevant role both in inflammatory and tumorigenic processes [21]. Whereas its mechanisms of action have been well elucidated for inflammation, less is known for cancer promotion. Some experimental studies demonstrated that COX-2 over-expression is associated with a significant decrease of apoptosis, an increase in malignant cell invasiveness and an enhancement of prostaglandin synthesis and cell proliferation [22]. Opposite effects together with decreased angiogenesis are associated with COX-2 inhibition [23].

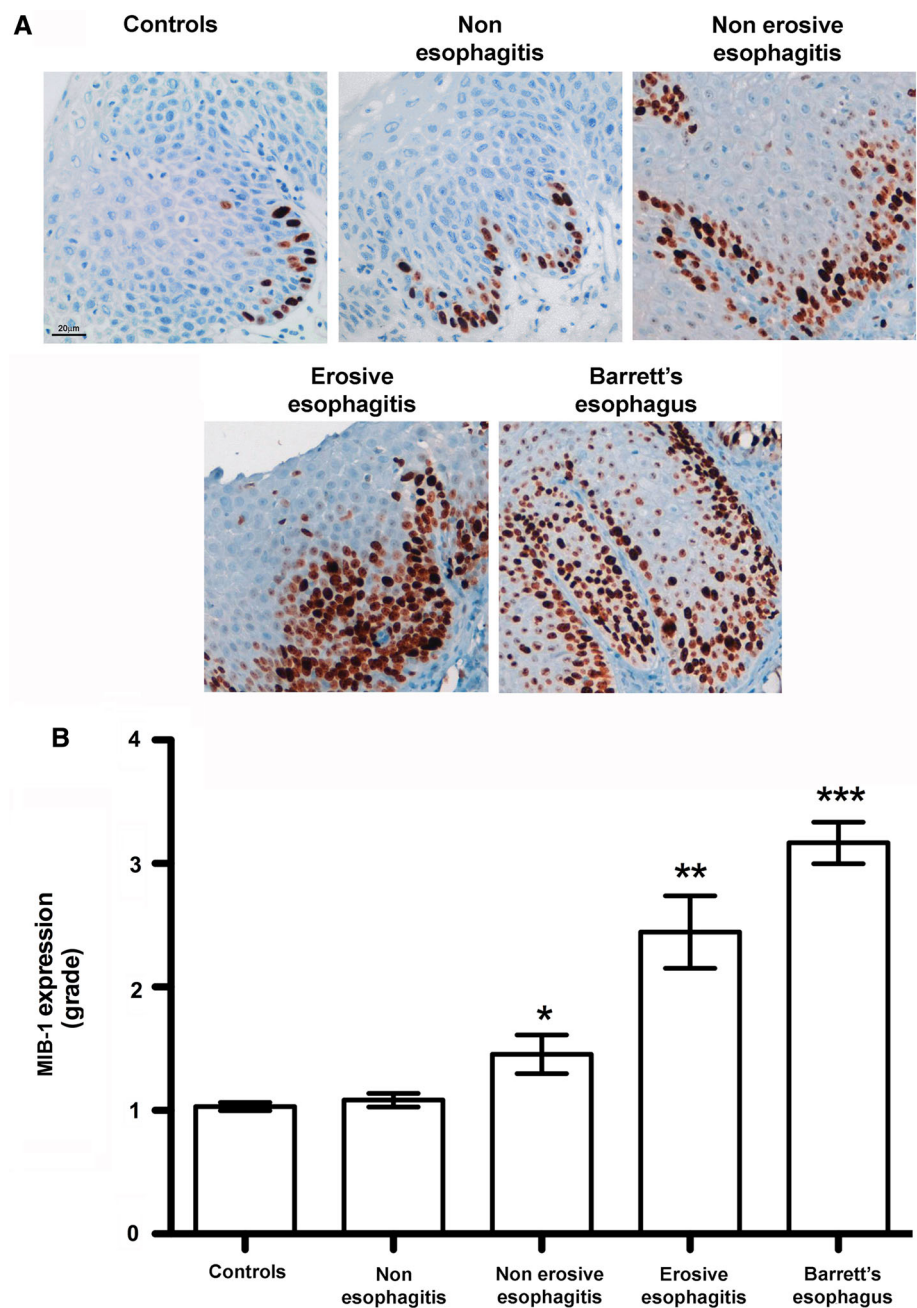
Both the proinflammatory and tumorigenic effects may contribute to explain why COX-2 has been considered involved in esophageal, gastric and colorectal carcinogenesis [24]. More specifically, as far as esophageal carcinogenesis is concerned, some epidemiological studies have suggested that COX-2 inhibitors play a protective effect, which may take place early in the inflammation-metaplasia-carcinoma sequence (i.e. before the occurrence of BE and even before the occurrence of esophagitis) [25].

On the contrary, results of clinical studies in BE appear to some extent conflicting. On one hand, 10-day therapy with specific COX-2 inhibitors reduced COX-2 expression, PGE₂ release and cell proliferation [26]; on the other hand, no differences in the progression of BE dysplasia to cancer seems to be produced by 48-week treatment with celecoxib [27].

More consistent data are produced by experimental findings which showed a reduction of both inflammation and tendency to develop adenocarcinoma induced by COX-2 inhibitors administration in rat [13].

In the present study, COX-2 expression, proliferative activity, VEGF expression/production and basal PGE₂ levels in esophageal biopsies progressively increase from patients without esophagitis to patients with non erosive and erosive esophagitis, to those with BE. Incubation of the cells with DCA determines a PGE₂ production increase, which is prevented by pretreatment with the selective COX-2 inhibitor celecoxib. This inhibitory effect of celecoxib also takes place on both DCA/EGF stimulated proliferative activity and VEGF production.

Fig. 3 Immuno-histochemistry expression of Mib-1 in human specimens from controls, non esophagitis, non erosive, erosive esophagitis and BE patients (a, b). Mib-1 gradually increased with the severity of the disease (significant differences of non erosive, erosive esophagitis and BE both versus controls and non esophagitis patients (* $p < 0.05$; ** $p < 0.01$; *** $p < 0.001$, respectively)



Therefore, our data are in agreement with previous reports and complete previous findings, showing a COX-2 involvement even in the early steps of the sequence leading to esophageal adenocarcinoma.

From previous epidemiological, experimental and clinical findings and from the present data a unitary interpretation of the effects of COX-2 inhibition on the esophageal progression from normal epithelium to BE and further to adenocarcinoma could be proposed. First of all, COX-2 inhibition could generically exert an anti-inflammatory effect throughout the process. Moreover, at a very early stage it may interfere with the progression of the sequence,

due to the prevention of the pro-inflammatory and angiogenic effects of PGE₂. This could downstage esophagitis and, consequently, prevent and/or slow-down intestinal metaplasia formation. Once intestinal metaplasia has occurred, it is likely that no reversion effect on it can be exerted by COX-2 inhibition, and for this item results of the ASPECT trial will be decisive. On the other hand, COX-2 inhibition could probably be relevant in avoiding or slowing-down the further step, i.e. the progression of metaplasia to dysplasia. Moreover, although dysplasia has probably an unavoidable tendency for further development to adenocarcinoma [28], this evolution could be restrained

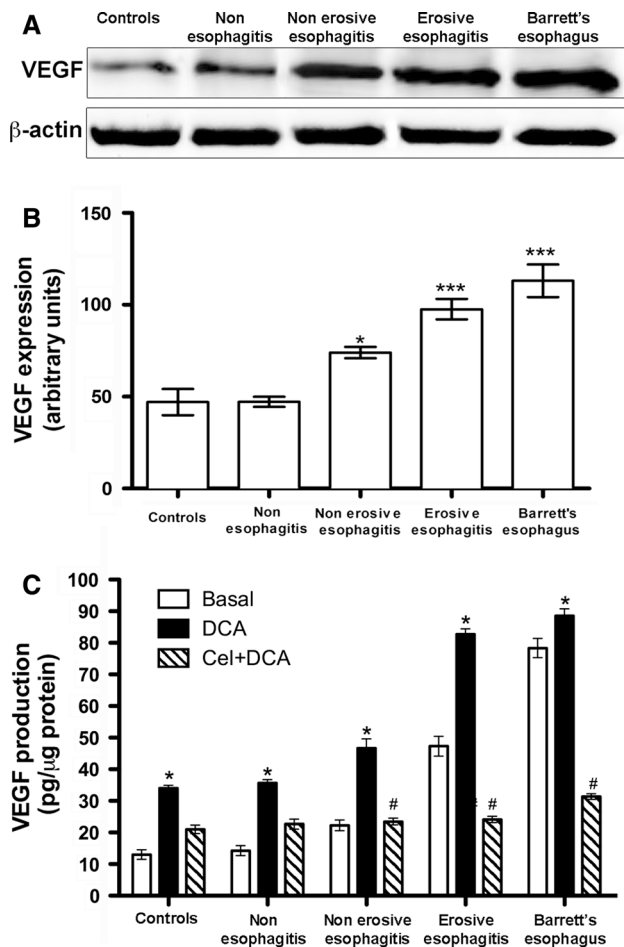


Fig. 4 Western blot analysis of VEGF protein in human specimens from controls, non esophagitis, non erosive, erosive esophagitis and BE patients. Samples were normalized with β -actin (a). The expression of VEGF increased from non erosive and erosive esophagitis to BE patients (b). The basal and DCA-stimulated VEGF production gradually increased with the stage of the disease ($*p < 0.01$). Celecoxib pre-incubation (1 μ M) for 1 h reduced DCA stimulated VEGF production in non erosive and erosive esophagitis and BE patients compared with controls and non esophagitis patients (c) (two-way ANOVA, $\#p < 0.05$)

by the inhibition of the antiapoptotic and cell proliferation promoting activities of COX-2.

Sphingolipids have been recently shown to be sources of important signaling molecules. Particularly the sphingolipid metabolites, ceramide and sphingosine-1-phosphate have emerged as a new class of potent bioactive molecules implicated in inflammation, cell proliferation and apoptosis regulation [29]. The “de novo” synthetic pathway of intracellular ceramide can be elicited by a few different stimuli among which also inflammatory conditions, such as esophagitis, are represented.

It has been recently demonstrated that spinal formation of ceramide determines neuroimmune activation, nitrosative stress and increased apoptosis [29, 30].

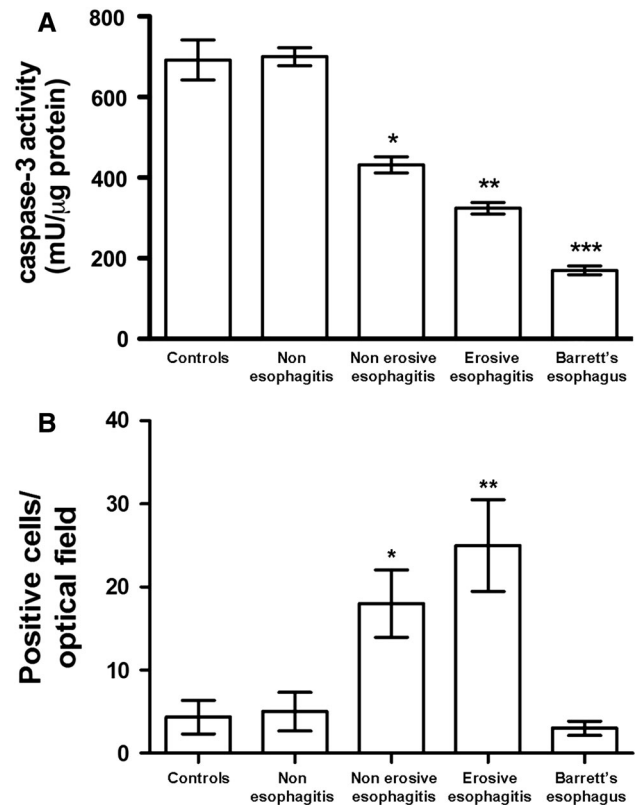


Fig. 5 a The activity of caspase-3 progressively decreased from non esophagitis to BE patients ($*p < 0.05$; $**p < 0.01$; $***p < 0.001$ among groups). The number of positive cells of ceramide (b) was significantly greater in non erosive and erosive esophagitis in comparison to controls and non esophagitis patients ($*p < 0.05$; $**p < 0.01$). No differences were shown between BE and both controls and non esophagitis (b)

In our study ceramide positive cells gradually increase from non erosive esophagitis to erosive esophagitis patients. This finding is in line with previous experimental data [29–32]. On the contrary, in our BE patients ceramide levels were significantly lower than in non erosive and erosive esophagitis and similar to those in controls and non esophagitis patients. The latter finding is hardly explainable, even considering BE as a complex condition in which a multifactorial impairment of different pro-inflammatory and apoptotic pathways are involved [14].

In conclusion, although further studies and larger series are needed, our findings of a close relationship between progression of GERD from its very initial steps and COX-2, proliferative activity and EGF/VEGF expression might have important implications in the strategy of management/treatment of GERD in order to prevent its neoplastic evolution.

Acknowledgments This work was supported by grants from the University of Florence and Ente Cassa di Risparmio di Firenze (E.M. and P.B.).

Conflict of interest None.

References

- DuBois RN, Eberhart CF, Williams CS. Introduction to eicosanoids and the gastroenteric tract. *Gastroenterol Clin North Am*. 1996;25:267–277.
- Smith WL, DeWitt DL, Garavito RM. Cyclooxygenases: structural, cellular, and molecular biology. *Annu Rev Biochem*. 2000;69:145–182.
- Fu S, Ramanujam KS, Wong A, et al. Increased expression and cellular localization of inducible nitric oxide synthase and cyclooxygenase 2 in *Helicobacter pylori* gastritis. *Gastroenterology*. 1999;116:1319–1329.
- Boolbol SK, Dannenberg AJ, Chadburn A, et al. Cyclooxygenase-2 overexpression and tumor formation are blocked by sulindac in a murine model of familial adenomatous polyposis. *Cancer Res*. 1996;56:2556–2560.
- Nataraj C, Thomas DW, Tilley SL, et al. Receptors for prostaglandin E(2) that regulate cellular immune responses in the mouse. *Clin Invest*. 2001;108:1229–1235.
- Tsuji M, Kawano S, Tsuji S, et al. Cyclooxygenase regulates angiogenesis induced by colon cancer cells. *Cell*. 1998;94:273.
- Chiarugi V, Magnelli L, Gallo O. Cox-2, iNOS and p53 as playmakers of tumor angiogenesis (review). *Int J Mol Med*. 1998;2:715–719.
- Cianchi F, Cortesini C, Fantappiè O, et al. Cyclooxygenase-2 activation mediates the proangiogenic effect of nitric oxide in colorectal cancer. *Clin Cancer Res*. 2004;10:2694–2704.
- Jones DJ, Lamb JH, Verschoyle RD, et al. Characterisation of metabolites of the putative cancer chemopreventive agent quercetin and their effect on cyclo-oxygenase activity. *Br J Cancer*. 2004;91:1213–1219.
- Thun MJ. NSAID use and decreased risk of gastrointestinal cancers. *Gastroenterol Clin North Am*. 1996;25:333–348.
- Williams CS, Mann M, DuBois RN. The role of cyclooxygenases in inflammation, cancer, and development. *Oncogene*. 1999;18:7908–7916.
- Shirvani VN, Ouatu-Lascar R, Kaur BS, et al. Cyclooxygenase 2 expression in Barrett's esophagus and adenocarcinoma: ex vivo induction by bile salts and acid exposure. *Gastroenterology*. 2000;118:487–496.
- Buttar NS, Wang KK, Leontovich O, et al. Chemoprevention of esophageal adenocarcinoma by COX-2 inhibitors in an animal model of Barrett's esophagus. *Gastroenterology*. 2002;122:1101–1112.
- Iravani S, Zhang HQ, Yuan ZQ, et al. Modification of insulin-like growth factor 1 receptor, c-Src, and Bcl-XL protein expression during the progression of Barrett's neoplasia. *Hum Pathol*. 2003;34:975–982.
- Ogretmen B, Hannun YA. Biologically active sphingolipids in cancer pathogenesis and treatment. *Nat Rev Cancer*. 2004;4:604–616.
- Liu W, Reinmuth N, Stoeltzing O, et al. Cyclooxygenase-2 is up-regulated by interleukin-1 beta in human colorectal cancer cells via multiple signaling pathways. *Cancer Res*. 2003;1:3632–3636.
- Cianchi F, Cortesini C, Bechi P, et al. Up-regulation of cyclooxygenase 2 gene expression correlates with tumor angiogenesis in human colorectal cancer. *Gastroenterology*. 2001;121:1339–1347.
- Lowry OH, Rosebrough NJ, Farr AL, et al. Protein measurement with the Folin phenol reagent. *J Biol Chem*. 1951;193:265–275.
- Stennicke HR, Salvesen GS. Biochemical characteristics of caspases-3, -6, -7, and -8. *J Biol Chem*. 1997;272:25719–25723.
- Thornberry NA, Rano TA, Peterson EP, et al. A combinatorial approach defines specificities of members of the caspase family and granzyme B. Functional relationships established for key mediators of apoptosis. *J Biol Chem*. 1997;272:17907–17911.
- Kristinsson JO, van Westerveld P, te Morsche RH, et al. Cyclooxygenase-2 polymorphisms and the risk of esophageal adenocarcinoma. *World J Gastroenterol*. 2009;15:3493–3497.
- Jiménez P, Piazuolo E, Cebrian C, et al. Prostaglandin EP2 receptor expression is increased in Barrett's oesophagus and oesophageal adenocarcinoma. *Aliment Pharmacol Ther*. 2010;31:440–451.
- Li S, Tong Q, Zhang W, et al. Mechanism of growth inhibitory effects of cyclooxygenase-2 inhibitor-NS398 on cancer cells. *Cancer Invest*. 2008;26:333–337.
- Wu WK, Sung JJ, Lee CW, et al. Cyclooxygenase-2 in tumorigenesis of gastrointestinal cancers: an update on the molecular mechanisms. *Cancer Lett*. 2010;295:7–16.
- Fujimura T, Ohta T, Oyama K, et al. Cyclooxygenase-2 (COX-2) in carcinogenesis and selective COX-2 inhibitors for chemoprevention in gastrointestinal cancers. *J Gastrointest Cancer*. 2007;38:78–82.
- Triadafilopoulos G, Kaur B, Sood S, et al. The effects of esomeprazole combined with aspirin or rofecoxib on prostaglandin E₂ production in patients with Barrett's oesophagus. *Aliment Pharmacol Ther*. 2006;23:997–1005.
- Heath EI, Canto MI, Piantadosi S, et al. Secondary chemoprevention of Barrett's esophagus with celecoxib: results of a randomized trial. *J Natl Cancer Inst*. 2007;99:545–557.
- Lanas A, Ortego J, Sopeña F, et al. Effects of long-term cyclooxygenase 2 selective and acid inhibition on Barrett's oesophagus. *Aliment Pharmacol Ther*. 2007;26:913–923.
- Ndengele MM, Cuzzocrea S, Masini E, et al. Spinal ceramide modulates the development of morphine antinociceptive tolerance via peroxynitrite-mediated nitroxidative stress and neuro-immune activation. *J Pharmacol Exp Ther*. 2009;329:64–75.
- Bryant L, Doyle T, Chen Z, et al. Spinal ceramide and neuronal apoptosis in morphine antinociceptive tolerance. *Neurosci Lett*. 2009;463:49–53.
- Muscoli C, Cuzzocrea S, Ndengele MM, et al. Therapeutic manipulation of peroxynitrite attenuates the development of opiate-induced antinociceptive tolerance in mice. *J Clin Invest*. 2007;117:3530–3539.
- Petrache I, Medler TR, Richter AT, et al. Superoxide dismutase protects against apoptosis and alveolar enlargement induced by ceramide. *Am J Physiol Lung Cell Mol Physiol*. 2008;295:L44–L53.