

## CASE REPORT

### Prenatal diagnosis of X-linked adrenoleukodystrophy associated with isolated pericardial effusion

Giovanna Traficante<sup>1</sup>, Roberto Biagiotti<sup>2</sup>, Elena Andreucci<sup>3</sup>, Mariarosaria Di Tommaso<sup>4</sup>, Aldesia Provenzano<sup>1</sup>, Ettore Cariatì<sup>2</sup> & Sabrina Giglio<sup>1,3</sup>

<sup>1</sup>Medical Genetics Unit, Department of Clinical and Experimental Biomedical Sciences "Mario Serio", University of Florence, Florence, Italy

<sup>2</sup>Medical and Surgical Feto-Neonatal Department, Meyer Children's University Hospital, Florence, Italy

<sup>3</sup>Medical Genetics Unit, Meyer Children's University Hospital, Florence, Italy

<sup>4</sup>Department of Health Sciences, University of Florence, Florence, Italy

#### Correspondence

Sabrina Giglio, Department of Clinical and Experimental Biomedical Sciences and Medical Genetics Unit, Meyer Children's University Hospital, viale Pieraccini, 24 50139 Firenze Italy. Tel:+390555662216; Fax: +390555662849; E-mails: s.giglio@meyer.it; sabrinarita.giglio@unifi.it

#### Funding information

No sources of funding were declared for this study.

Received: 26 January 2015; Revised: 10

March 2015; Accepted: 19 March 2015

*Clinical Case Reports* 2015; 3(7): 643–645

doi: 10.1002/ccr3.283

#### Case Report

A 26-year-old healthy was referred to our tertiary center at 17+5 weeks of gestation with a diagnosis of pericardial effusion (PE) seen at a routine ultrasound examination. The pregnancy was developing normally and there was no history of exposure to medical or toxic substances.

Fetal echocardiography revealed a small PE of about 3 mm in end-diastole, normal fetal heart structure, rhythm, and function. There was no evidence of extracardiac malformations or hydrops.

Fetal biometry and the volume of amniotic fluid were normal. Fetal anemia was excluded by evaluating middle cerebral artery Doppler velocimetry. Viral screening (TORCH complex and parvovirus B19) in maternal serum was negative.

The patient was counseled that the presence of isolated PE could result in chromosomal aneuploidies or some genetic disease and then recommended to genetic counseling. This was the first pregnancy of a nonconsanguineous

#### Key Clinical Message

This is the first reported case of fetal pericardial effusion in association with X-linked adrenoleukodystrophy and hypocortisolism from a nonautoimmune cause. Our hypothesis is that in experienced hands and after accurate genetic counseling, isolated pericardial effusion can constitute an indication for a severe metabolic disease.

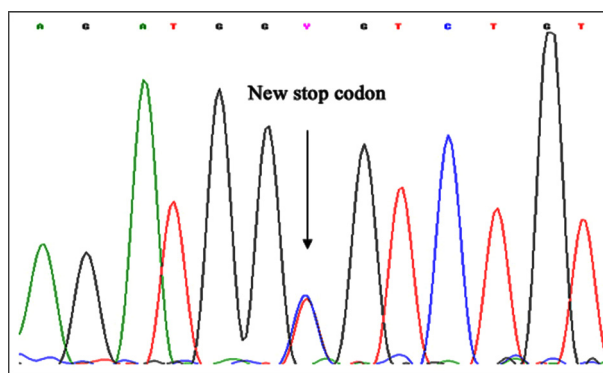
#### Keywords

Genetic counseling, hypocortisolism, pericardial effusion, X-linked adrenoleukodystrophy.

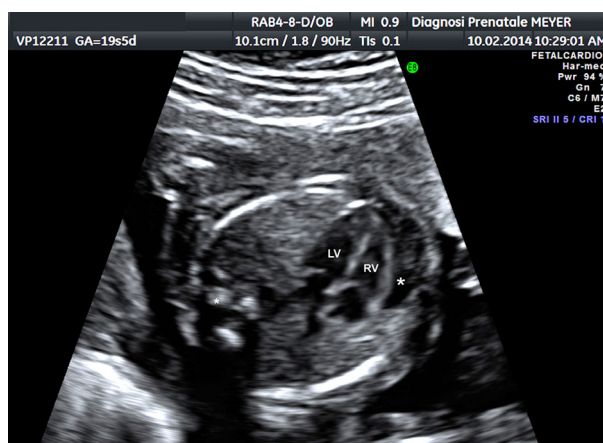
couple and they reported negative history for congenital malformations. The woman referred that a maternal uncle died in the young age for unknown reason, but he suffered of intellectual disability and spasticity. Her brother presented the following clinical signs: progressive neurodegeneration, paraparesis, cognitive decline, seizures, and ataxia.

Family history revealed the presence of possible X-linked genetic disease and we suspected X-linked adrenoleukodystrophy (X-ALD). In the same time, we performed the entire gene sequence of *ABCD1* gene in the mother and fetus. The woman resulted carrier of the c.919 C>T (p.Gln307\*) mutation.

The male fetus presented the same mutation identified in his mother (Fig. 1); fetal karyotyping after amniocentesis was normal (46,XY). The parents opted to continue the pregnancy in anticipation of a possible hematopoietic stem cell transplantation. Serial fetal echocardiography showed a constant small PE not requiring pericardiocentesis (Fig. 2).



**Figure 1.** Sanger sequencing of *ABCD1* gene in the carrier mother that identified the heterozygous mutation C>T. The arrow indicate the base pair substitution.



**Figure 2.** Two dimensional echocardiography with four-chamber view demonstrating the pericardial effusion (asterisk) in the woman at 19 weeks' gestation. LV, left ventricle; RV, right ventricle.

At 39+2 weeks of gestation, a male infant was delivered. His weight was 3350 g, length 49 cm and the Apgar score 9/10. He had a normal clinical examination and the postnatal echocardiography showed same value of PE (3 mm).

Venous blood spot measurement of C26:0 lysophosphatidylcholine (26:0-lyso-PC) was performed by tandem mass spectrometry (MS/MS) demonstrating an altered level, even if the boy was asymptomatic.

## Discussion

PE is defined as a pericardial fluid collection larger than 2 mm; generally, PEs measuring < 4 mm are categorized as small, while those measuring  $\geq$  4 mm are categorized as large [1]. Isolated PE without other fluid collections covers

a wide spectrum of etiologies from transient forms to genetic and chromosomal anomalies.

A high incidence (30%) of chromosomal anomalies, mainly trisomy 21, has been reported in isolated PE [2]. Infections (toxoplasma, cytomegalovirus, rubella virus, herpes virus, parvovirus B19) can also cause PEs [3]. Cardiac etiologies of PE can be tumors (teratoma, rhabdomyoma), a pericardial capillary hemangioma and ventricular outpouchings such as diverticula and aneurysms [4,5]. The etiology, therefore, is diverse and PE can also be a benign finding in milder forms in the absence of sonographic abnormalities and it may also be present in otherwise normal, healthy fetuses [1]. In isolated PE, the inflammation of pericardium as a possible cause of this sonographic finding must also be considered [2].

We describe a case of isolated PE, not related to structural heart anomalies or fetal arrhythmias.

Genetic counseling revealed familiarity for X-linked adrenoleukodystrophy (X-ALD) (OMIM #300100), one of the most frequent peroxisomal diseases affecting the adrenal cortex, the central nervous system, and testicular function [6]. The incidence in males with X-ALD is estimated to be about 1:21,000. There is a broad phenotype of X-ALD, which ranges from the childhood cerebral form characterized by rapid progression to a vegetative state or death within 1–2 years (31–35%), to the slowly progressive adrenomyeloneuropathy (AMN) in adults (40–46%) [6]. Primary adrenal insufficiency (AI), or Addison's disease, may precede overt neurological involvement, particularly when X-ALD manifests at a younger age [7]. X-ALD results from pathogenetic variants including deletions, missense, nonsense, frameshift, and splice defects involving the *ABCD1* gene.

To date, the only identified storage products in this disorder consist of very long chain fatty acids (VLCFA) in the serum, brain, and adrenal glands [6] leading to hypocortisolism, which presents typical addisonian features such as dehydration, hypoglycemia, hyperkalemia, etc. [7].

We report, for the first time (to our knowledge), PE in a fetus affected by X-ALD. He inherited the mutation c.919 C>T (p.Gln307\*) in the *ABCD1* gene from the mother. This mutation was described by Montagna et al. [8] in an Italian family. The pathogenicity is quite straightforward because it leads to premature translation termination.

In order to define the pathogenicity of variant, all the following criteria were applied: variant was not included in dbSNP142; variant was reported in HGMD (www.hgmd.cf.ac.uk); variant did not occur in healthy controls within the "1000 Genomes Project" database (www.1000genomes.org); variant did not occur within

the Kaviar-hg19 database (<http://db.systemsbiology.net/kaviar/>).

In the light of the family history, we might consider that maternal uncle died for X-ALD, and that the affected brother of the fetus' mother has severe phenotype, and apparently no PE.

At the moment we have no information about the possible association of this variant with pericarditis. Recently, Taxter et al. [9] for the first time described a small PE in the absence of autoimmunity or particular infectious etiologies in a pediatric patient affected by X-ALD. They suppose that, even in the absence of autoimmunity, chronic hypocortisolism itself might provoke pericarditis. Our hypothesis is that also fetal PE could be the consequence of fetal adrenal insufficiency that appeared early in the development and that inflammation may induce PE.

Tumor necrosis factor (TNF) as a mediator of inflammation is a potent regulator of steroidogenesis and cell viability in adrenocortical cells, and may also inhibit adrenocorticotropin-induced cortisol production [10]. Consequently, we speculate that the subsequent fetal hypocortisolism in turn may prevent to remove PE which is the expression of pericardial inflammation. PE could be an echographic marker of X-ALD and hypocortisolism itself may be one of possible causes of isolated fetal PE.

In conclusion, in these circumstances an appropriated genetic counseling and multidisciplinary approach are the most effective goals to achieve a given diagnosis even in the absence of a specific ultrasound phenotype.

## Conflict of Interest

None declared.

## References

1. Slesnick, T. C., N. A. Ayres, C. A. Altman, L. I. Bezold, B. W. Eidem, J. K. Fraley, et al. 2005. Characteristics and outcomes of fetuses with pericardial effusions. *Am. J. Cardiol.* 96:599–601.
2. Azancot, A., R. Diehl, S. Dorgeret, G. Sebag, C. Baumann, E. Vuillard, et al. 2003. Isolated pericardial effusion in the human fetus: a report of three cases. *Prenat. Diagn.* 23:193–197.
3. Marton, T., W. L. Martin, and M. J. Whittle. 2005. Hydrops fetalis and neonatal death from human parvovirus B19: an unusual complication. *Prenat. Diagn.* 25:543–545.
4. Bernasconi, A., A. L. Delezoide, F. Menez, E. Vuillard, J. F. Oury, and A. Azancot. 2004. Prenatal rupture of a left ventricular diverticulum: a case report and review of the literature. *Prenat. Diagn.* 24:504–507.
5. Sepulveda, W., E. Gomez, and J. Gutierrez. 2000. Intrapericardial teratoma. *Ultrasound Obstet. Gynecol.* 15:547–548.
6. Kemp, S., J. Berger, and P. Aubourg. 2012. X-linked adrenoleukodystrophy: clinical, metabolic, genetic and pathophysiological aspects. *Biochim. Biophys. Acta* 1822:1465–1474.
7. Polgreen, L. E., S. Chahla, W. Miller, S. Rothman, J. Tolar, T. Kivisto, et al. 2011. Early diagnosis of cerebral X-linked adrenoleukodystrophy in boys with Addison's disease improves survival and neurological outcomes. *Eur. J. Pediatr.* 170:1049–1054.
8. Montagna, G., A. Di Biase, M. Cappa, M. A. Melone, C. Piantadosi, D. Colabianchi, et al. 2005. Identification of seven novel mutations in ABCD1 by a DHPLC-based assay in Italian patients with X-linked adrenoleukodystrophy. *Hum. Mutat.* 25:222.
9. Taxter, A. J., M. D. Bellin, and B. A. Binstadt. 2011. Pericarditis as the presenting feature of adrenoleukodystrophy. *Pediatrics* 127:777–780.
10. Mikhaylova, I. V., T. Kuulasmaa, J. Jaaskelainen, and R. Voutilainen. 2007. Tumor necrosis factor-alpha regulates steroidogenesis, apoptosis, and cell viability in the human adrenocortical cell line NCI-H295R. *Endocrinology* 148:386–392.