

Morphometric Analysis of the Transverse Dentoskeletal Features of Class II Malocclusion in the Mixed Dentition

Muhieddin Alarashi, DDS^a; Lorenzo Franchi, DDS, PhD^b; Andrea Marinelli, DDS^c; Efisio Defraia, MD, DMD^d

Abstract: The aim of the present study was to evaluate the dentoskeletal features of Class II malocclusion in the transverse plane by means of a morphometric analysis (thin-plate spline analysis [TPS]) applied to posteroanterior cephalograms. A sample of 49 subjects (24 males, 25 females; mean age 7 years, 9 ± 5 months) with Class II Division 1 malocclusion was compared with a control group of 50 subjects (17 males, 33 females; mean age 8 years, 4 ± 3 months) with Class I occlusion. Subjects of both groups were in the mixed dentition and had no history of orthodontic treatment. Average craniofacial configurations were subjected to TPS analysis to compare the differences in shape between the two groups. The results of the present study showed that subjects with Class II malocclusion exhibited significant shape differences in craniofacial configuration in the frontal plane when compared with subjects with normal occlusion; these differences mainly consisted of a contraction of the maxilla at both the skeletal and the dentoalveolar levels and a narrowing of the base of the nose. The reduction in maxillary dentoskeletal width was associated with an increase in the vertical height of the maxilla. (*Angle Orthod* 2003;73:21–25.)

Key Words: Posteroanterior cephalometrics; Thin-plate spline analysis

INTRODUCTION

Class II malocclusion is the most common orthodontic problem in the white Caucasian population.¹ Traditionally, occlusal and craniofacial characteristics of growing subjects with Class II molar relationship have been studied in the sagittal and vertical plane.^{2–10} But Class II malocclusion is a complex clinical entity that entails a combination of different three-dimensional dental and skeletal components.

Interestingly, studies on the transverse relationship of the maxilla to the mandible in Class II subjects in the mixed dentition have been limited to the analysis of the arch widths measured on the dental casts. Fröhlich¹¹ compared the intercanine and intermolar widths of the upper and lower arches of 51 children with Class II malocclusion with

the data collected by Moorrees¹² on children with normal occlusion. He found that the absolute arch widths of Class II children did not differ appreciably from those of children with normal occlusion.

On the other hand, Tollaro et al¹³ have shown that an underlying negative posterior transverse interarch discrepancy (PTID) (ie, a narrow maxillary arch when compared with the mandibular arch) exists in dental arches with Class II malocclusion (–3.4 mm on average) and seemingly normal buccal relationships. This underlying transverse discrepancy can be unmasked clinically by having the patient posture the mandible in an anterior position so that the canines are positioned in a Class I relationship.¹⁴

In 1997 Baccetti et al¹⁵ demonstrated that a negative PTID is recorded consistently in Class II subjects in the deciduous dentition and that the negative PTID is maintained or worsens in the transition to the mixed dentition. In a recent study Varrela¹⁶ confirmed that children with distal occlusion have narrower intermolar and intercanine distance from the age of 3 years when compared with normal subjects and that this difference increases with age. All these studies have been performed on dental casts, which allows for an evaluation of the width of the dental arches regardless of the transverse skeletal dimensions of both jaws. To our knowledge no data are available in the literature on the evaluation of transverse dentoskeletal characteristics of Class II subjects in the mixed dentition by analysis of posteroanterior (PA) cephalograms.

^a PhD Program in Clinical Pediatrics and Orthodontics, Department of Orthodontics, Università degli Studi di Firenze, Firenze, Italy.

^b Research Associate, Department of Orthodontics, Università degli Studi di Firenze, Firenze, Italy.

^c PhD Program in Preventive Orthodontics, Department of Orthodontics, Università degli Studi di Firenze, Firenze, Italy.

^d Assistant Professor, Department of Orthodontics, Università degli Studi di Firenze, Firenze, Italy.

Corresponding author: Lorenzo Franchi, DDS, PhD, Università degli Studi di Firenze, Via del Ponte di Mezzo, 46-48, 50127 Firenze, Italy (e-mail: l.franchi@odonto.unifi.it).

Accepted: July 2002. Submitted: July 2002.

© 2003 by The EH Angle Education and Research Foundation, Inc.

Conventional cephalometrics based on linear and angular measurements has shown an increasing number of limitations¹⁷ along with the proposal and implementation of new biometric analyses of landmark data (eg, elliptic Fourier analysis, finite element analysis, tensor and shape-coordinate analysis).¹⁸⁻²⁴ Major advantages of these still evolving methods include the separate evaluation of shape (or shape change) and size, an optimal superimposition of landmarks for analysis of shape change in complex skeletal configurations without the use of conventional reference lines, and an explanation of the morphological changes by viewing them using transformation grids.

A recent morphometric approach to the comparison of configurations of landmarks in two or more specimens is known as thin-plate spline (TPS) analysis, developed by Bookstein.²⁵ In TPS analysis the differences in the two configurations of landmarks are expressed as a continuous deformation by using regression functions in which homologous points are matched between forms to minimize the bending energy.²⁶ Bending energy can be defined as the energy required to bend an infinitely thin metal plate over one set of landmarks so that the height over each landmark is equal to the coordinates of the homologous point in the other form. TPS analysis enables the construction of transformation grids that capture the shape differences and are available for visual interpretation. For a more detailed review of the theoretical bases, calculation procedures, assumptions, and limitations of TPS morphometrics, see Bookstein,²⁵⁻²⁹ Rohlf and Marcus,³⁰ Rohlf et al,³¹ and Dryden and Mardia.³² In recent times TPS analysis has been gaining increasing importance in orthodontic literature for investigating modifications in shape related both to facial growth and to treatment.³³⁻⁴¹

The aim of the present study was to evaluate the dentoskeletal features of subjects with Class II malocclusion in the mixed dentition by means of a morphometric analysis (TPS analysis) applied to PA cephalograms.

MATERIALS AND METHODS

A sample of 49 subjects (24 males, 25 females; mean age 7 years, 9 ± 5 months) was selected and classified as Class II Division 1 malocclusion group according to the following inclusionary criteria: bilateral Class II molar relationship in centric occlusion, bilateral Class II deciduous/permanent canine relationship in centric occlusion, and buccal inclination of upper incisors. As a control group 50 subjects (17 boys, 33 girls; mean age 8 years, 4 ± 3 months) with bilateral molar and deciduous/permanent canine Class I relationship in centric occlusion, and without anterior or lateral cross-bites, were selected. All subjects were taken from the files of the Department of Orthodontics, University of Florence before any orthodontic intervention. Subjects of both groups were in the mixed dentition, did not show missing teeth (due to aplasia, trauma, or

deep caries), had no history of orthodontic treatment, and did not present with craniofacial syndromes.

PA cephalograms were of good quality for all the subjects in both groups. All cephalograms were taken with the Frankfurt plane parallel to the floor, with the head front and the nose tip in contact with the radiographic cassette. PA cephalograms were hand-traced with a 0.5-mm lead on a 0.003-mm matte acetate tracing paper. All tracings were performed by one investigator and were subsequently verified by another investigator. The traced PA cephalograms were analyzed using a digitizing tablet (Numonics, Landsdale, Pennsylvania) and a digitizing software (Viewbox ver. 2.6). All the cephalograms were converted to a 10% enlargement to standardize the magnification data. A description of the cephalometric landmarks used in this study is given in Figure 1.

To analyze the combined error of landmark location and digitization, 25 randomly selected PA cephalograms were retraced and redigitized. The standard error deviation for each dimension was calculated from the double determinations using Dahlberg's formula.⁴² The mean value for the method error was 0.55 ± 0.23 mm.

In the present study the TPS program⁴³ computed the orthogonal least-squares Procrustes average configuration of landmarks both in the Class II group and in the control group. Following this method every object's coordinates are translated, rotated, and scaled iteratively until the least-squared fit of all configurations cannot be improved any more.⁴⁴ Therefore, all configurations are scaled to an equivalent size (centroid size = 1) and registered with respect to one another.

The average craniofacial configurations were subjected to TPS analysis to compare the differences in shape between the two groups. Statistical analysis of shape differences was performed by means of permutation tests with 1000 random permutations on Wilk's lambda statistics.⁴³

RESULTS

TPS analysis applied to PA cephalograms revealed significant shape differences in the craniofacial configuration of subjects with Class II malocclusion when compared with subjects with normal occlusion in the mixed dentition ($P < .0001$) (Figure 2). Significant shape differences were localized in the maxillary region and in the nasal region. The greatest deformation could be described as a contraction of the maxilla at both the skeletal and the dental levels, ie, a bilateral compression in the horizontal plane at point Mx and at point Um bilaterally. The contraction on the transverse plane was associated with an extension of the maxilla in the vertical plane due to a downward displacement of point Mx bilaterally. A slight contraction of the base of the nose was also evident. No significant difference in shape could be detected in the orbital region and in the mandible when comparing Class II subjects with Class I

controls, with the exception of a slight upward dislocation of point Me.

DISCUSSION

Studies on transverse dimension in subjects with Class II malocclusion in the mixed dentition have been usually performed on dental casts measuring dental arch characteristics, regardless of the transverse skeletal dimensions of both jaws. Most authors agree that transverse interarch discrepancy due a narrow maxillary arch can be considered a typical feature of Class II malocclusion from the early developmental phases.¹³⁻¹⁶

Interestingly, no data are available on both dental and skeletal aspects of transverse dimension in Class II malocclusion using PA cephalograms. The aim of the present study was to evaluate the dentoskeletal features of Class II malocclusion in the transverse plane with the help of a morphometric analysis (TPS analysis) applied to PA cephalograms. Major advantages of TPS analysis applied to cephalometric landmark configurations with respect to both conventional cephalometrics and previous morphometric techniques (eg, shape-coordinate analysis) include (1) an optimal superimposition of landmarks for analysis of shape change in complex skeletal configurations without the use of any conventional reference line, and (2) a visual interpretation of the craniofacial shape differences independent of size variations using transformation grids.²⁶

The results of the present study showed that subjects with Class II malocclusion exhibited significant shape differences in craniofacial configuration in the frontal plane when compared with subjects with normal occlusion; these differences mainly consisted of a contraction of the maxilla at both the skeletal and the dentoalveolar levels and a narrowing of the base of the nose. The reduction in skeletal width of the maxilla was associated with an increase in vertical height due to a downward displacement of point Mx bilaterally. No significant difference in shape could be detected in the mandible on the transverse plane when comparing Class II subjects with Class I controls.

The findings of the current study have obvious clinical implications. Because transverse deficiency in the maxilla at both the skeletal and the dentoalveolar levels appears to be a typical feature of Class II malocclusion in the mixed dentition phase, an initial goal of treatment might be early correction of the transverse occlusal relationships by rapid maxillary expansion (RME). Early treatment with RME is further supported by the findings of a recent investigation,³⁸ which showed that patients treated before the pubertal growth spurt exhibit significant and more effective long-term changes at the skeletal level in both maxillary and circummaxillary structures. When RME treatment is performed after the pubertal peak, maxillary adaptations to expansion therapy shift from the skeletal level to the dentoalveolar level. In another study⁴⁵ that analyzed by means of

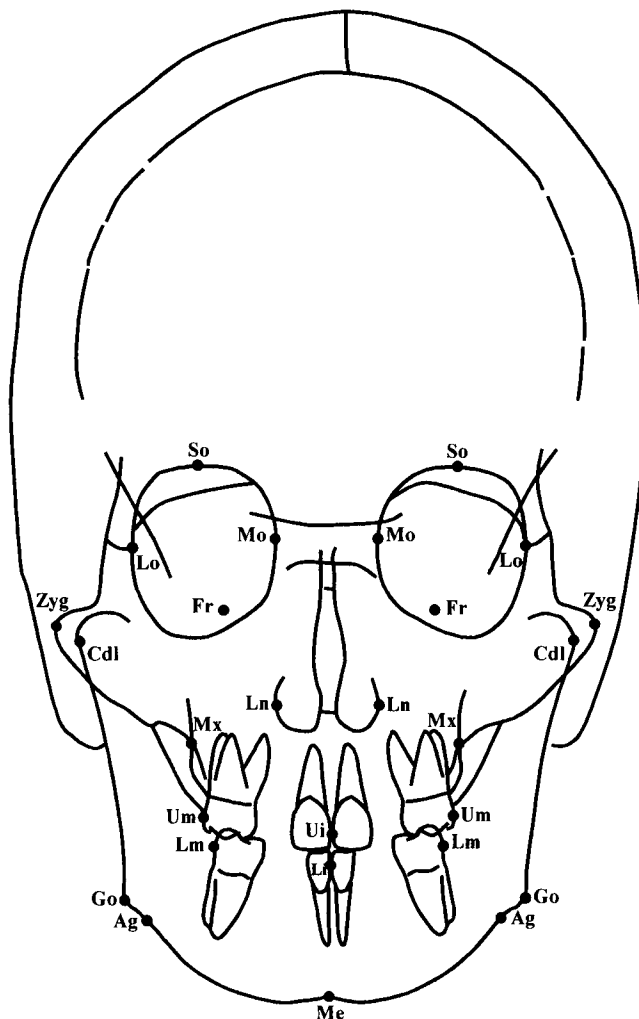


FIGURE 1. Cephalometric landmarks. Skeletal landmarks: supra-orbitale (So), the superior point of the orbital contour; medio-orbitale (Mo), the most medial point of the orbital contour; latero-orbitale (Lo), the mesial point of the frontal-zygomatic suture; foramen rotundum (Fr), the foramen rotundum of the sphenoid bone; zygomatic (Zyg), the most lateral point of the zygomatic arch; condylar lateral (Cdl), the point located at the lateral pole of the condylar head; maxillare (Mx), the point located at the depth of the concavity of the lateral maxillary contour, at the junction of the maxilla and the zygomatic buttress; lateronasal (Ln), the most lateral point of the nasal cavity; gonion (Go), the point located at the gonial angle of the mandible; antegonion (Ag), the point located at the antegonial notch; menton (Me), the central point on the lower border of the mandibular symphysis. Dental landmarks: upper molar (Um), the most prominent lateral point on the buccal surface of the upper first molar; lower molar (Lm), the most prominent lateral point on the buccal surface of the lower first molar; upper interincisal point (Ui), the contact point between the upper incisors; lower interincisal point (Li), the contact point between the lower incisors.

TPS analysis the long-term effects induced by RME, it was noted that RME is able to normalize the shape of the maxillary complex in subjects presenting with transverse deficiency of the maxilla during the early developmental phases. In particular, RME is able to induce transverse incre-

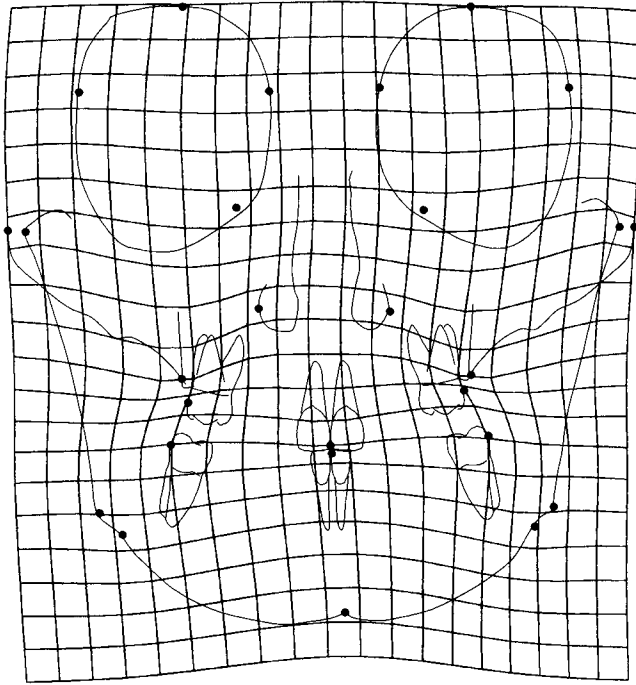


FIGURE 2. Thin-plate spline graphical display of the shape differences between the Class II group and the control group (magnification 4 \times).

ments of the naso-maxillary complex, which remain stable in the long term.

It is not uncommon, from a clinical point of view, to observe a spontaneous correction of the Class II occlusal relationship in patients with mild to moderate Class II problems treated in the early mixed dentition with RME followed by a palatal stabilization plate, even though no definitive Class II therapy (eg, extra oral traction, functional jaw orthopedics) has been provided.¹⁴ McNamara and Brudon¹⁴ hypothesize that expansion of the maxillary dentition may create an “endogenous functional appliance” in that lingual cusps of the maxillary dental arch, overexpanded after RME relative to the mandibular dental arch, will encourage the growing patient to posture his or her jaw in a more protrusive position when establishing comfortable contact in centric occlusion, ultimately leading to a stable occlusal change.

If a spontaneous correction is not observed, and in patients with more severe skeletal and muscular problems, a functional jaw orthopedic appliance (eg, bionator, FR-2 of Fränkel, twin block) or extra oral traction can be used after an initial phase of expansion, during or slightly after the onset of the pubertal peak in growth velocity,⁴⁶ to address the underlying anteroposterior skeletal discrepancy.

CONCLUSIONS

Subjects with Class II malocclusion in the mixed dentition present with significant shape differences in craniofa-

cial configuration in the frontal plane when compared with subjects with normal occlusion. Shape variations in Class II subjects mainly consisted of a contraction of the maxilla at both the skeletal and the dentoalveolar levels and a narrowing of the base of the nose at the maxilla.

REFERENCES

1. Moyers RE. *Handbook of Orthodontics*. 4th ed. Chicago, Ill: Year Book Med Publishers; 1988: 191.
2. Drellich RC. A cephalometric study of untreated Class II, Division 1 malocclusion. *Angle Orthod*. 1948;18:70–75.
3. Craig CE. The skeletal pattern characteristics of Class I and Class II, Division 1 malocclusion in norma lateralis. *Angle Orthod*. 1951;21:44–56.
4. Fisk GV, Culbert MR, Grainger RM, Hemrend B, Moyers R. The morphology and physiology of distocclusion. *Am J Orthod*. 1953; 39:3–11.
5. Altemus LA. Horizontal and vertical dentofacial relationships in normal and Class II division I malocclusion in girls 11–15 years. *Angle Orthod*. 1955;25:120–137.
6. Hitchcock HP. A cephalometric description of Class II, Division 1 malocclusion. *Am J Orthod*. 1973;63:414–423.
7. Moyers RE, Riolo ML, Guire KE, Wainright RL, Bookstein FL. Differential diagnosis of Class II malocclusions. Part 1. Facial types associated with Class II malocclusion. *Am J Orthod*. 1980; 78:477–494.
8. McNamara JA Jr. Components of Class II malocclusion in children 8–10 years of age. *Angle Orthod*. 1981;51:177–202.
9. Karlsen AT. Craniofacial morphology in children with Angle Class II-1 malocclusion with and without deepbite. *Angle Orthod*. 1994;64:437–446.
10. Rothstein T, Yoon-Tarlie C. Dental and facial skeletal characteristics of males and females with Class II, Division 1 malocclusion between the ages of 10 and 14 (revisited). Part I: characteristics of size form and position. *Am J Orthod Dentofacial Orthop*. 2000; 117:320–32.
11. Frölich FJ. A longitudinal study of untreated Class II type malocclusion. *Trans Eur Orthod Soc*. 1961;37:137–159.
12. Moorrees CFA. *The Dentition of the Growing Child: A Longitudinal Study of Dental Development Between 3 and 18 Years of Age*. Cambridge, Mass: Harvard University Press; 1959.
13. Tollaro I, Baccetti T, Franchi L, Tanasescu CD. Role of posterior transverse interarch discrepancy in Class II, Division 1 malocclusion during the mixed dentition phase. *Am J Orthod Dentofacial Orthop*. 1996;110:417–422.
14. McNamara JA Jr, Brudon WL. *Orthodontics and Dentofacial Orthopedics*. Ann Arbor, Mich: Needham Press; 2001;55–67.
15. Baccetti T, Franchi L, McNamara JA Jr, Tollaro I. Early dentofacial features of Class II malocclusion: a longitudinal study from the deciduous through the mixed dentition. *Am J Orthod Dentofacial Orthop*. 1997;111:502–509.
16. Varrela J. Early developmental traits in Class II malocclusion. *Acta Odontol Scand*. 1998;56:375–377.
17. Moyers RE, Bookstein FL. The inappropriateness of conventional cephalometrics. *Am J Orthod*. 1979;75:599–617.
18. Blum H. Biological shape and visual science. *J Theor Biol*. 1973; 38:205–287.
19. Bookstein FL. On the cephalometrics of skeletal change. *Am J Orthod*. 1982;82:177–182.
20. Cheverud JM, Lewis JL, Bachrach W, Lew WD. The measurement of form and variation in form: an application of three-dimensional quantitative morphology by finite-element methods. *Am J Phys Anthropol*. 1983;62:151–165.
21. Lestrel PE. A Fourier analytic procedure to describe complex

- morphological shapes. In: Dixon AD, Sarnat BG, eds. *Factors and Mechanisms Influencing Bone Growth*. New York, NY: Alan R. Liss; 1982:393–409.
22. Lavelle CLB. A preliminary study of mandibular shape. *J Craniofac Genet Dev Biol*. 1985;5:159–165.
 23. Moss ML, Skalak R, Pateli H, Sen K, Moss-Salentijn L, Shinozuka M, Vilmann H. Finite element method modeling of craniofacial growth. *Am J Orthod*. 1985;87:453–472.
 24. Lestrel PE, Roche AF. Cranial base shape variation with age: a longitudinal study of shape using Fourier analysis. *Hum Biol*. 1986;58:527–540.
 25. Bookstein FL. Principal warps: thin-plate splines and the decomposition of deformations. *IEEE Trans Pattern Anal Mach Intell*. 1989;11:567–585.
 26. Bookstein FL. *Morphometric Tools for Landmark Data*. New York, NY: Cambridge University Press; 1991:26–39.
 27. Bookstein FL. Biometrics, biomathematics, and the morphometric synthesis. *Bull Math Biol*. 1996; 313–365.
 28. Bookstein FL. Shape and the information in medical images: a decade of the morphometric synthesis. *Comput Vis Image Underst*. 1997;66:97–118.
 29. Bookstein FL. A hundred years of morphometrics. *Acta Zool*. 1998;44:7–59.
 30. Rohlf FJ, Marcus LF. A revolution in morphometrics. *Trends Ecol Evol*. 1993;8:129–132.
 31. Rohlf FJ, Loy A, Corti M. Morphometric analysis of Old World Talpidae (Mammalia, Insectivora) using partial-warp scores. *Syst Biol*. 1996;45:344–362.
 32. Dryden IL, Mardia KV. *Statistical Shape Analysis*. New York, NY: John Wiley; 1998.
 33. Pae EK, Lowe AA, Fleetham JA. A thin-plate spline analysis of the face and tongue in obstructive sleep apnea patients. *Clin Oral Invest*. 1997;1:178–184.
 34. Singh GD, McNamara JA Jr, Lozanoff S. Thin-plate spline analysis of the cranial base in subjects with Class III malocclusion. *Eur J Orthod*. 1997;19:341–353.
 35. Singh GD, McNamara JA Jr, Lozanoff S. Spline analysis of the mandible in human subjects with Class III malocclusion. *Arch Oral Biol*. 1997;42:345–353.
 36. Singh GD, McNamara JA Jr, Lozanoff S. Components of soft-tissue deformations in subjects with untreated angle's Class III malocclusions: thin-plate spline analysis. *J Craniofac Genet Dev Biol*. 1998;18:219–227.
 37. Singh GD, McNamara JA Jr, Lozanoff S. Soft tissue thin-plate spline analysis of pre-pubertal Korean and European-Americans with untreated angle's Class III malocclusions. *J Craniofac Genet Dev Biol*. 1999;19:94–101.
 38. Baccetti T, Franchi L, McNamara JA Jr. Thin-plate spline analysis of treatment effects of rapid maxillary expansion and face mask therapy in early Class III malocclusions. *Eur J Orthod*. 1999;21:275–281.
 39. Baccetti T, Franchi L, McNamara JA Jr. Thin-plate spline analysis of mandibular growth. *Angle Orthod*. 2001;71:83–92.
 40. Lux CJ, Rübél J, Starke J, Conradt C, Angelika S, Komposch G. Effects of early activator treatment in patients with Class II malocclusion evaluated by thin-plate spline analysis. *Angle Orthod*. 2001;71:120–126.
 41. Franchi L, Baccetti T, Cameron CG, Kutcipal EA, McNamara JA Jr. Thin-plate spline analysis of short-term and long-term effects of rapid maxillary expansion. *Eur J Orthod*. 2002;24:143–150.
 42. Dahlberg G. *Statistical Methods for Medical and Biological Students*. New York, NY: Interscience Publications; 1940.
 43. Rohlf FJ. *Tpsregr, Ver. 1.25*. Stony Brook, NY: University of New York; 2000. Available at: <http://life.bio.sunysb.edu/morph>.
 44. Rohlf FJ, Slice DE. Extensions of the Procrustes method for the optimal superimposition of landmarks. *Systematic Zool*. 1990;39:40–59.
 45. Baccetti T, Franchi L, Cameron CG, McNamara JA Jr. Treatment timing for rapid maxillary expansion. *Angle Orthod*. 2001;71:343–350.
 46. Baccetti T, Franchi L, Toth LR, McNamara JA Jr. Treatment timing for twin block therapy. *Am J Orthod Dentofacial Orthop*. 2000;118:159–170.