

Introduction: With the introduction of photosensitizing drugs allowing photodynamic diagnostic (PDD) for the bladder cancer, diagnosis has become more accurate. The main limitation of the procedure is the false-positive detection rate, which ranges from 12% to 60%. The onset of multifocal transitional cell carcinoma has been described as a panurothelial disease as it evolves because of genetic defects that are present also in histological negative urothelial tissue. **Objective:** We analyzed chromosomal patterns of false-positive lesions in the PDD and compared them with the findings of random biopsies with the intent to observe if hexaminolevulinate detects chromosomal aberrations in histological healthy tissue. **Patients and Methods:** Included in the study were 18 patient, 16 men and 2 women, with a mean age of 70.5 (range=47-83) years. All had false-positive PDD confirmed in the histology. A random sample was taken from all patients. The chromosomal patterns of all samples were analyzed with fluorescence *in situ* hybridization (FISH). **Results:** From January 2012 until November 2014, a total of 266 bladder biopsies were performed in 30 patients with a positive PDD finding. Eighteen patients had false-positive biopsies in a total of 40 biopsies. In these patients, a total of 25 random biopsies were also performed. Seven out of 18 patients showed chromosomal aberration in 10 (25%) of the false-positive biopsies. All 10 biopsies showed aneusomy of the Locus 9p21 (p16), 6 (13%) aneusomy of chromosome 3 and 5 biopsies (12,5%) aneusomy of chromosome 7 and chromosome 17. In 4 patients, the FISH of the control random biopsy was positive. One had an aneusomy of Locus 9p21 (p16), the other three had aneusomy also for chromosomes 3, 7 and 17. **Conclusion:** In our trial, over a third of the patients with a false-positive PDD finding already express chromosomal aberrations in these lesions.

120
SIMPLE ENUCLEATION FOR THE TREATMENT OF HIGHLY COMPLEX RENAL TUMORS: PERIOPERATIVE, FUNCTIONAL AND ONCOLOGICAL RESULTS

Gianni Vittori, Andrea Mari, Riccardo Campi, Jacopo Frizzi, Tommaso Jaeger, Andrea Chindemi, Riccardo Fantechi, Andrea Cocci, Mauro Gacci, Alberto Lapini, Sergio Serni, Marco Carini and Andrea Minervini

Department of Urology, Careggi Hospital, University of Florence, Florence, Italy

Aim: To assess perioperative, functional and oncological results of simple enucleation (SE) in patients with highly complex renal tumors (PADUA score 10-13). **Materials and Methods:** Data of 510 patients treated with SE for renal cell carcinoma (RCC) between July 2006 and August 2013 in our Department were gathered in a prospectively maintained database. Of these, 96 had highly complex renal tumors (PADUA 10-13, Figure 1A) and were selected for this study, including 76 treated open and 20 with robotic SE (endoscopic robotic-assisted simple enucleation (ERASE)). Conventional perioperative variables were collected and compared between open and robotic approach with univariate analysis. Survival status and functional data were gathered at follow-up. The probability of survival was estimated by the Kaplan-Meier method. **Results:** Mean (range) clinical tumor diameter was 4.8 cm (interquartile range (IQR)=3-10). PADUA score was 10, 11, 12 and 13 in 57.3%, 29.2%, 11.5% and 2.1% of tumors, respectively. Overall, 19.8% of

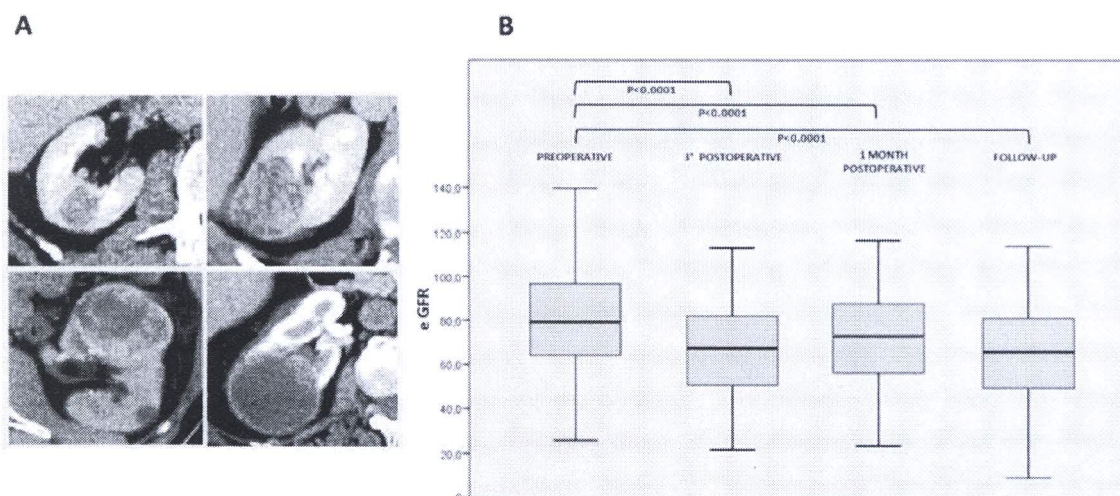


Figure 1. (Abstract 120).

patients had stage ≥ 3 chronic kidney disease (CKD) and 17.7% an imperative/relative indication. Clamping of renal pedicle was used for almost all patients (99%) with a mean warm ischemia time (WIT) of 19.2 ± 5.7 minutes. Mean operative time was 126 minutes, mean estimated blood loss (EBL) 200 cc and median length of stay (LOS) 6 days (IQR=5-7). Percentage of patients with postoperative complications was 26.1% (2.1% Clavien 1, 14.6% Clavien 2, 8.3% Clavien 3, 1% Clavien 4). Benign tumors accounted for 12.5% of patients. Positive surgical margin (PSM) rate was 3.6% (3/84). The trifecta outcome was accomplished in 56.2% of patients. The mean \pm SD (range) follow-up was 54 ± 26 (14-96) months. The 5-year cancer-specific survival (CSS), recurrence-free survival (RFS) and overall survival (OS) rates resulted 96.1%, 90.8% and 88.0%, respectively. Preoperative, 3rd postoperative day, one month postoperative and follow-up median (IQR) estimated glomerular filtration rate (eGFR) was 79 (64-97), 68 (51-82), 76 (56-88) and 66 (50-81) ml/min/1.73 m², respectively (Figure 1B). *Discussion and Conclusion:* The optimal oncological and functional results of SE suggest that ERASE is particularly appropriate to treat highly complex renal masses, minimizing the loss of healthy renal volume and widening the indications of NSS according to the latest European Association of Urology (EAU) guidelines.

122

ASAP AND HGPIN PREDICTIVE VALUE OF PROSTATE CANCER DIAGNOSIS: CAN WE IMPROVE IT?

Marco Agnello¹, Maurizio Barale¹, Marco Oderda¹, Simone Giona¹, Giancarlo Marra¹, Lorenzo Daniele², Donatella Pacchioni², Luisa Delsedime², Paola Dalmaso³, Nathalie Nicolaiew⁴, Alexandre De La Taille⁵, Bruno Frea¹, Hendrik Van Poppel⁶, Steven Joniau⁶ and Paolo Gontero¹

Departments of ¹Urology, ²Pathology, and ³Epidemiology, San Giovanni Battista Hospital, Turin, Italy;

⁴Faculty of Medicine, Université Paris-Est Créteil Val De Marne, Paris, France;

⁵Department of Urology, CHU Mondor, Créteil Val De Marne, Paris, France;

⁶Department of Urology, University Hospital Gasthuisberg, Leuven, Belgium

Introduction and Objectives: Operator-dependency and lack of standardized diagnostic criteria may affect ability of high grade prostatic intraepithelial neoplasia (HGPIN) and atypical small acinar proliferation (ASAP) to predict prostate cancer (PCa). We assessed the long-term predictive ability of

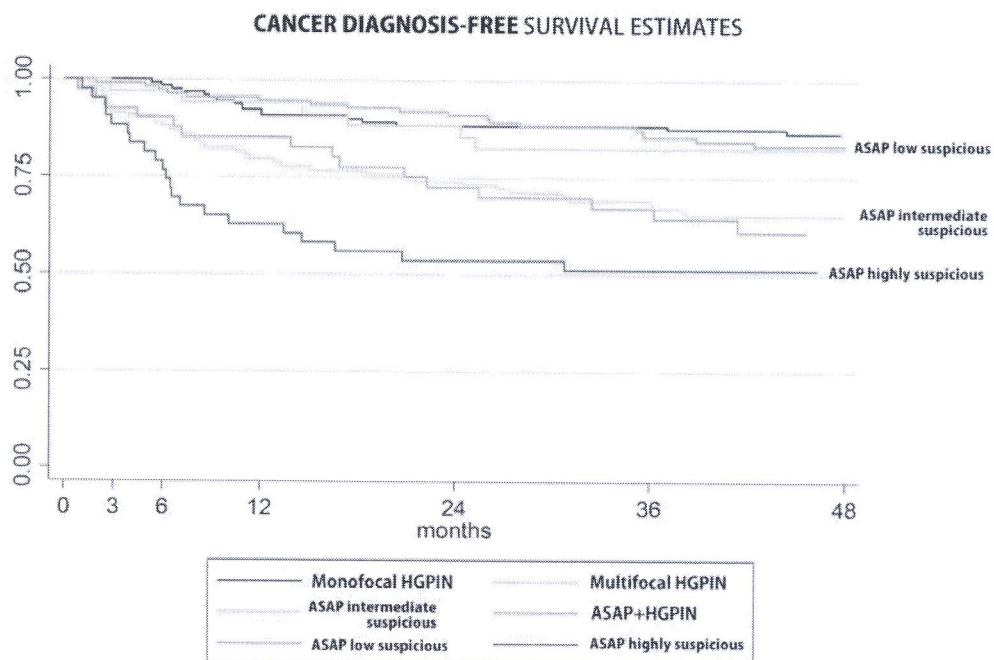


Figure 1. (Abstract 122).