

Semen apoptotic M540 body levels correlate with testis abnormalities: a study in a cohort of infertile subjects

F. Lotti[†], L. Tamburrino[†], S. Marchiani, M. Muratori, G. Corona, M.G. Fino, S. Degl'Innocenti, G. Forti, M. Maggi, and E. Baldi*

Department of Clinical Physiopathology, Sexual Medicine and Andrology and Endocrinology Units, University of Florence, viale Pieraccini 6, 50139 Florence, Italy

*Correspondence address. E-mail: elisabetta.baldi@unifi.it

Submitted on June 13, 2012; resubmitted on August 13, 2012; accepted on August 17, 2012

STUDY QUESTION: What are the associations between semen apoptotic M540 bodies and other parameters of semen quality and sonographic alterations of the male genital tract in a cohort of infertile subjects?

SUMMARY ANSWER: In infertile subjects, semen M450 bodies are highly correlated with ultrasound and clinical signs of testis abnormalities but not with alterations of other parts of the male genital tract, suggesting a testicular origin of M540 bodies.

WHAT IS KNOWN ALREADY: We have reported the presence in semen of round nucleate elements, named 'M540 bodies', resembling apoptotic bodies as they contain several apoptotic markers.

STUDY DESIGN AND SIZE: A consecutive series of 130 males with couple infertility were evaluated, during the same day session, for clinical, scrotal and transrectal color-Doppler ultrasound characteristics, and hormonal and semen parameters, including interleukin 8 (sIL-8) and M540 body levels.

PARTICIPANTS/MATERIALS, SETTING METHODS: Semen parameters were analyzed by WHO recommended procedures. CDU was performed using the ultrasonographic console Hitachi H21. sIL-8 and serum hormones were evaluated by ELISA methods.

MAIN RESULTS AND THE ROLE OF CHANCE: The average percentage value of M540 bodies was 24.6 ± 18.3 . After adjusting for possible confounders (age, waist, calculated free testosterone and smoking habit), M450 body levels negatively correlated with sperm number/ejaculate, progressive motility, normal morphology and sIL-8 levels ($\text{adj.}r = -0.455, P < 0.0001$; $\text{adj.}r = -0.464, P < 0.0001$; $\text{adj.}r = -0.430, P < 0.001$; $\text{adj.}r = -0.236, P < 0.05$, respectively). In a subset of patients with a history of cryptorchidism ($n = 8$), M540 bodies were higher than in non-cryptorchid men (40.5 ± 14.8 versus $23.6 \pm 18.2\%$; $P < 0.02$). A negative correlation was found between M540 and ultrasound testis volume ($\text{adj.}r = -0.241, P < 0.05$), whereas a positive association was found with testis inhomogeneity [$\text{HR} = 1.06$ (1.02–1.09); $P = 0.002$], hypoechogenicity [$\text{HR} = 1.05$ (1.01–1.08); $P < 0.02$] and FSH levels ($\text{adj.}r = 0.309, P < 0.01$). No relationships were found with CDU characteristic of the prostate, seminal vesicles, epididymis and vas deferens. In a multivariate model, testis inhomogeneity and history of cryptorchidism were independently associated with M540 body levels ($\text{adj.}r = 0.355, P < 0.01$ and $\text{adj.}r = 0.223, P < 0.05$, respectively). Receiver operating characteristic analysis demonstrated that at the threshold of 27%, M540 bodies discriminate subjects with testis inhomogeneity with a sensitivity of 72% and specificity of 73%.

LIMITATIONS, REASONS FOR CAUTION: The increased M540 body semen levels in men with a history of cryptorchidism should be confirmed in a larger number of patients.

WIDER IMPLICATIONS OF THE FINDINGS: M540 bodies may be considered a semen marker of altered testis function and thus their evaluation may be helpful in the diagnosis of male infertility.

STUDY FUNDING/COMPETING INTEREST(S): This work was supported by grants from Ministry of University and Scientific Research (Prin project to E.B. and FIRB project to S.M.) and Regione Toscana (to G.F.).

Key words: semen analysis / scrotal and transrectal ultrasound / apoptotic bodies / testis apoptosis / cryptorchidism

[†]The first two authors contributed equally to the study.

Introduction

In most cases, male infertility is due to defects in spermatogenesis, the complex, dynamic process that leads to the maturation of spermatogonia into mature spermatozoa. Spermatogenesis is regulated by several hormonal and local factors which control all the steps of the sperm maturation process. The number of cells in the seminiferous tubules is finely regulated by a balance between cell proliferation and apoptotic cell death. The apoptotic process, which occurs at a high rate in the testis, is required not only to maintain an adequate ratio between proliferating germ cells and Sertoli cells but also to guarantee the quality control of the mature gamete. Several studies in animal models have documented the physiological relevance of apoptosis in the testis (Shaha et al., 2010). Apoptosis in the testis may occur through both the intrinsic and the extrinsic pathway (Shaha et al., 2010). The intrinsic pathway is triggered by Bcl-X and Bax (Rucker et al., 2000; Shaha et al., 2010), whereas the extrinsic is mediated by the Fas/FasL system (Francavilla et al., 2000; Shaha et al., 2010). Evidence in human subjects suggests that Fas expression in the testis is confined to Leydig cells and degenerating germ cells and its expression in the latter is increased in subjects with late maturation arrest or Sertoli cell only syndrome (Francavilla et al., 2000, 2002; Kim et al., 2004). In addition, Fas/FasL expression appears to be regulated by gonadotrophins (Francavilla et al., 2000). Moreover, exposure to excess testosterone or deprivation causes apoptosis in the testis (reviewed in Shaha, 2008). Overall, these data indicate that any alteration of the apoptotic process in both the meiotic and post-meiotic stages of male germ cell maturation may cause a derangement of spermatogenesis. In this context, evaluation of apoptotic markers in semen may be of help in establishing the rate of apoptosis in the testis. Apoptotic markers, such as caspase activity, Fas and Bcl-X, may be evaluated by immunocytochemistry in ejaculated spermatozoa but such determination is time-consuming and quite expensive.

Some years ago, our group described the occurrence in semen of round anucleated elements of variable dimensions, named M540 bodies because of their stainability with merocyanine (Muratori et al., 2004). Later on, our group has characterized M540 bodies as apoptotic bodies by evaluating a series of apoptotic markers (Fas, p53, Bcl-X and caspase activity; Marchiani et al., 2007). M540 bodies are present in larger amounts in semen from oligoasthenoteratozoospermic and asthenospermic men (Marchiani et al., 2007) where the highest levels of semen apoptotic signs have been found (Sakkas et al., 1999) and are strictly negatively associated with poor seminal parameters (Muratori et al., 2005). M450 bodies may be thus considered a semen marker of apoptosis. Although we have clearly demonstrated the apoptotic nature of M540 bodies and that they contain fragmented DNA (Marchiani et al., 2007), whether they reflect testis apoptosis or derive from other parts of the male genital tract is presently unknown.

Taking the advantage of the diagnostic protocol applied to newly referred subjects in the Andrology Outpatient Clinic at the University of Florence (see below), the aim of this study was to evaluate the possible association between male genitalia tract ultrasound characteristics and M540 body levels in the semen of male partners of infertile couples. We report here consistent evidence that M540 bodies originate in the testis and may be considered a semen trait of testis apoptosis.

Materials and Methods

Patients

We studied a consecutive series of 130 male patients (mean age 34.1 ± 8.4 years) attending our outpatient clinic for the first time from January 2008 to July 2011 and seeking medical care for couple infertility. The clinical characteristics of the sample are summarized in the [Supplementary data, Table S1](#).

All patients were evaluated before beginning any treatment. All patients underwent a complete andrological and physical examination, and their previous and current genito-urinary diseases, including positive urine and seminal cultures, were assessed. In addition, scrotal and transrectal ultrasounds were routinely performed. This procedure followed our Regional Health Care System rules which do not allow us to perform any genetic analysis on infertile patients unless the possible occurrence of an obstruction has been excluded. Hence, all patients enrolled underwent the usual diagnostic protocol applied to newly referred subjects at the Andrology Outpatient Clinic for infertility. All the data provided were collected as part of a routine clinical procedure, and therefore, according to the Italian law, approval from the local Ethical Committee was not required. In addition, at the time of the first visit, all patients gave their written informed consent to have their clinical records included in a dedicated database and they were aware that their data, after having been made anonymous, would be used for clinical research purposes.

Color-Doppler ultrasonography

All patients underwent scrotal and transrectal color-Doppler ultrasound, performed before and after ejaculation during the same CDU session, using the ultrasonographic console Hitachi H21 (Hitachi Medical System, Tokyo, Japan). The CDU characteristics of the patients are summarized in the [Supplementary data, Table S1](#).

Prostate and seminal vesicles CDU features were studied by scanning the organs at 5 mm intervals in various longitudinal, transverse and oblique scans according to previous studies (Behre et al., 1995; Vicari, 1999; Lotti et al., 2011, 2012a,b), using a transrectal biplanar probe to study the prostate (linear transducer U533L 7.5 MHz; convex transducer U533C 6.5 MHz) and an 'end-fire' probe to study the seminal vesicles and the deferential ampullae (V53W 6.5 MHz, field of view 50–200°). Prostate echogenicity and hyperemia were defined according to previous studies (Behre et al., 1995; Vicari, 1999; Lotti et al., 2011, 2012b). Prostate vascularization and arterial prostatic peak systolic velocity were evaluated before ejaculation, in order to avoid post-ejaculatory changes in the vascular flow pattern, as previously reported (Lotti et al., 2011, 2012b). Seminal vesicles ultrasound features and abnormalities were defined according to previous studies (Colpi et al., 1997; Vicari, 1999; Lotti et al., 2011, 2012a). Ejaculatory duct CDU characteristics were evaluated after ejaculation, in order to better emphasize indirect CDU signs of subobstruction (Colpi et al., 1997; Lotti et al., 2011, 2012a).

Scrotal CDU was performed in various longitudinal, transverse and oblique scans (Behre et al., 1995; Vicari, 1999; Lotti et al., 2011, 2012a) using a 7.5-MHz high-frequency linear probe (L54M 6–13 MHz). Testicular and epididymal CDU features were examined according to previous studies (Behre et al., 1995; Vicari, 1999; Isidori and Lenzi, 2008; Lotti et al., 2011, 2012a; Bertolotto and Trombetta, 2012). In particular, testis inhomogeneity (striated pattern) and hypoechogenicity were defined according to previous studies (Cohn et al., 1996; Christiansen and Dogra, 2007; Isidori and Lenzi, 2008; Loberant et al., 2010; Bertolotto and Trombetta, 2012). The [Supplementary data, Fig. S1](#) shows the appearance of a normal testis echopattern (A), testis inhomogeneity (B) and hypoechogenicity (C).

Semen analysis and determination of seminal plasma interleukin 8 levels

Semen parameters were assessed by optical microscopy, according to World Health Organization criteria (World Health Organization, 1999, 2010). Sperm morphology was evaluated by determining the percentage of normal and abnormal forms after Diff-Quik staining, by scoring at least 100 spermatozoa/slide. Sperm motility was scored by determining the percentage of progressive motile, non-progressive motile and immotile spermatozoa by scoring at least 100 sperm/slide. Seminal plasma aliquots were stored frozen to quantify seminal plasma interleukin 8 (sIL-8) levels. sIL-8, a reliable surrogate marker of prostatitis (Penna *et al.*, 2007), was quantified by conventional two-site ELISA using a human IL-8 ELISA set (BD Biosciences, San Diego, CA, USA) according to the manufacturer's instructions (Penna *et al.*, 2007). Each seminal plasma sample was diluted from 1:5 to 1:625. Assay sensitivity for sIL-8 was <1 pg/ml.

Hormone evaluation

LH, FSH, total testosterone and sex hormone-binding globulin (SHBG) were evaluated. Blood samples were drawn in the morning, after an overnight fast, for the determination of LH, FSH and total testosterone by the electrochemiluminescent method (Modular Roche, Milan, Italy) and determination of SHBG by modular E170 platform electrochemiluminescence immunoassay (Roche Diagnostics, Mannheim, Germany). Calculated free testosterone was derived according to the Vermeulen' formula (available at <http://www.issam.ch/freetesto.htm>; Vermeulen *et al.*, 1999).

Chemicals

Diff-Quick kit was purchased from CGA, Diasint (Florence, Italy). Human tubal fluid (HTF) medium was purchased from Celbio (Milan, Italy). Propidium iodide (PI) was from Invitrogen Calbiochem (Nottingham, UK). Paraformaldehyde (PFA) was obtained from Merck Chemicals (Milan, Italy). Testsimplets slides were from Waldeck GmbH & Co. (Muenster, Germany).

Evaluation of M540 Bodies

The percentage of M540 bodies was determined in rough semen samples according to a previously published protocol (Marchiani *et al.*, 2007). Semen was washed twice with HTF medium and fixed with PFA [500 μ L, 4% in phosphate-buffered saline (PBS), pH 7.4] for 30 min at room temperature. Fixed spermatozoa (2×10^6) were washed (500 g for 5 min), resuspended in 500 ml of PBS, stained with 10 μ L of PI (30 mg/ml in PBS) and incubated in the dark for 10 min at room temperature. Samples were acquired by a FACScan flow cytometer (Becton-Dickinson, Mountain View, CA, USA) equipped with a 15-mW argon-ion laser for excitation. Red fluorescence of PI was detected by an FL-2 (563–607 nm wavelength band) detector. For each patient, two sperm suspensions were prepared for instrumental setting and data analysis with (sample test) and without (negative control) PI staining.

For each sample, 10 000 events were recorded within the enlarged flame-shaped region in the forward scattering/side scattering dot plot which excludes debris (RI region, Marchiani *et al.*, 2007). In order to quantify M540 bodies, a marker was set in the histogram of distribution of PI fluorescence of the sample in negative control, including 99% of total events. This marker was translated in the histogram of the corresponding test sample. All the events outside this marker were considered PI positive events, and all the events inside the marker were considered PI negative events. The percentage of M540 bodies was determined by counting the PI negative events in the RI region.

Statistical analysis

Data were expressed as the mean \pm SD when normally distributed, and as median (quartiles) for parameters with non-normal distribution. Correlations were assessed using Spearman's or Pearson's method whenever appropriate. Unpaired two-sided Student's *t*-tests were used for comparisons of means of normally distributed parameters. Stepwise multiple linear or logistic regressions were applied for multivariate analysis, whenever appropriate. Since age (Brinkworth *et al.*, 1997), waist (Attaman *et al.*, 2012), testosterone levels (Shaha, 2008) and smoking habit (Rajpurkar *et al.*, 2002) may influence testis apoptosis and affect seminal quality, data have been also adjusted for these parameters. All statistical analysis was performed on SPSS (Statistical Package for the Social Sciences, Chicago, USA) for Windows 17.0. In univariate analyses (unadjusted correlations of Table I), we considered the *P*-value of <0.02 as statistically significant, whereas a *P*-value of <0.05 was considered as significant in all the other regression analyses.

Results

Appearance of M540 bodies and relation with semen parameters

The Supplementary data, Fig. S1 (panel D) shows the appearance of M540 bodies in semen after staining with Testsimplets. As can be observed, these round elements have variable dimensions and can be easily distinguished from other non-sperm elements present in semen due to the lack of a nucleus. In the latest version of the WHO manual for processing of human semen (World Health Organization, 2010), such elements are indicated as cytoplasm.

In the present study, we confirm and extend previous findings of our group (Muratori *et al.*, 2004; Marchiani *et al.*, 2007), reporting a negative association between M540 bodies and sperm concentration, number per ejaculate, progressive motility and normal morphology (Table I), even after adjusting for age, waist, calculated free testosterone and smoking habit (Fig. 1A–D, respectively). After adjusting for confounders, no correlation was found with ejaculate volume, duration of sexual abstinence, semen pH and the presence of semen viscosity (Table I). Levels of M540 bodies were not associated with the presence of current positive urine or semen cultures or with a positive history of genito-urinary diseases (Table I). A negative association between M540 bodies and sIL-8 levels was observed after adjustment for age, waist, calculated free testosterone and smoking habit (Table I).

Relation between M540 bodies and medical history-derived parameters

The average percentage value of semen M540 bodies in the study population was 24.6 ± 18.3 . Among the 130 patients studied, 8 (6.2%) reported a history of cryptorchidism. In these patients, the mean M540 body value was significantly higher respect to subjects without cryptorchidism (40.5 ± 14.8 versus $23.6 \pm 18.2\%$, respectively; $P < 0.02$). After adjusting for age, waist, calculated free testosterone and smoking habit, a positive association between M540 bodies and the presence of a positive history of cryptorchidism were still observed (Fig. 2A).

Table 1 Associations between M540 body levels and main clinical and extra-testicular CDU features of the male genital tract.

	Unadjusted correlations	Adjusted correlations
Clinical and laboratory parameters		
Mean testis volume (Prader, ml)	$r = -0.291, P = 0.001$	Adj.r = -0.287, P < 0.02
History of cryptorchidism	$r = 0.245, P = 0.005$	HR = 1.16 (1.03–1.31), P < 0.02
History of genito-urinary diseases	$r = 0.009, P = 0.926$	HR = 1.01 (0.97–1.03), P = 0.909
Current positive urine and/or semen culture	$r = 0.007, P = 0.938$	HR = 0.99 (0.94–1.05), P = 0.784
LH	$r = 0.097, P = 0.324$	Adj.r = -0.005, P = 0.967
FSH	$r = 0.237, P = 0.015$	Adj.r = 0.309, P < 0.01
Total testosterone (nmol/L) ^a	$r = 0.088, P = 0.369$	Adj.r = 0.102, P = 0.708
Calculated free testosterone (nmol/L) ^a	$r = 0.138, P = 0.192$	Adj.r = 0.109, P = 0.364
Log ₁₀ (sIL-8) (ng/ml)	$r = -0.161, P = 0.05$	Adj.r = -0.236, P < 0.05
Sexual abstinence (days)	$r = -0.030, P = 0.736$	Adj.r = -0.111, P = 0.345
pH	$r = 0.010, P = 0.909$	Adj.r = 0.115, P = 0.331
Semen viscosity	$r = 0.148, P = 0.092$	HR = 1.00 (0.97–1.03), P = 0.950
Semen volume (ml)	$r = 0.243, P = 0.005$	Adj.r = 0.175, P = 0.127
Sperm concentration ($\times 10^6$ /ml)	$r = -0.657, P < 0.0001$	$r = -0.591, P < 0.0001$
Spermatozoa per ejaculate ($\times 10^6$ /ml)	$r = -0.572, P < 0.0001$	$r = -0.455, P < 0.0001$
Sperm progressive motility (%)	$r = -0.378, P < 0.0001$	$r = -0.464, P < 0.0001$
Sperm morphology (% normal forms)	$r = -0.336, P < 0.0001$	$r = -0.430, P = 0.001$
Leukocytospermia	$r = -0.011, P = 0.899$	HR = 0.99 (0.95–1.03), P = 0.691
CDU parameters		
Prostate		
Prostate volume (ml)	$r = 0.037, P = 0.676$	Adj.r = 0.029, P = 0.832
Prostate macro-calcifications ^b	$r = -0.079, P = 0.373$	HR = 0.98 (0.97–1.03), P = 0.857
Inhomogeneous prostatic texture	$r = 0.032, P = 0.718$	HR = 1.01 (0.97–1.04), P = 0.931
Hypochoic prostatic texture	$r = -0.101, P = 0.365$	HR = 0.98 (0.92–1.04), P = 0.460
Prostatic hyperemia (before ejaculation)	$r = -0.013, P = 0.883$	HR = 1.00 (0.96–1.03), P = 0.765
Mean arterial peak systolic velocity (cm/s)	$r = 0.003, P = 0.976$	Adj.r = -0.003, P = 0.977
Mean prostatic venous plexus (mm)	$r = -0.036, P = 0.685$	Adj.r = -0.088, P = 0.477
Seminal vesicles		
Total volume before ejaculation (ml) ^c	$r = 0.060, P = 0.500$	Adj.r = 0.070, P = 0.541
Total volume after ejaculation (ml) ^c	$r = 0.068, P = 0.445$	Adj.r = 0.103, P = 0.375
Ejection fraction (%) ^d	$r = -0.099, P = 0.262$	Adj.r = -0.109, P = 0.334
Areas of endocapsulation before ejaculation	$r = 0.016, P = 0.871$	HR = 0.99 (0.95–1.02), P = 0.413
Areas of endocapsulation after ejaculation	$r = -0.014, P = 0.887$	HR = 0.98 (0.93–1.03), P = 0.324
Wall thickening and septa	$r = -0.042, P = 0.639$	HR = 1.01 (0.97–1.05), P = 0.853
Testis		
Mean testis volume (ml)	$r = -0.251, P = 0.004$	Adj.r = -0.241, P < 0.05
Testicular inhomogeneity	$r = 0.375, P < 0.0001$	HR = 1.06 (1.02–1.09), P = 0.002
Testicular hypoechoogenicity	$r = 0.282, P = 0.001$	HR = 1.05 (1.01–1.08), P < 0.02
Testicular microcalcifications	$r = 0.124, P = 0.161$	HR = 1.04 (0.99–1.09), P = 0.114
Varicocele ^e	$r = -0.061, P = 0.491$	HR = 0.99 (0.96–1.03), P = 0.693
Epididymis and vas deferens		
Mean size of the head (mm)	$r = 0.037, P = 0.676$	Adj.r = -0.014, P = 0.898
Mean size of the tail (mm)	$r = -0.012, P = 0.893$	Adj.r = -0.106, P = 0.344
Mean size of the deferential ampulla (mm)	$r = 0.0112, P = 0.203$	Adj.r = -0.192, P = 0.083
Inhomogeneous tail	$r = 0.066, P = 0.453$	HR = 1.00 (0.98–1.03), P = 0.760

Continued

Table 1 *Continued*

	Unadjusted correlations	Adjusted correlations
Hypoechoic tail	$r = 0.061$, $P = 0.489$	HR = 1.01 (0.97–1.04), $P = 0.761$
Hyperechoic tail	$r = 0.144$, $P = 0.102$	HR = 1.02 (0.98–1.05), $P = 0.386$
Coarse tail calcifications	$r = 0.089$, $P = 0.311$	HR = 1.01 (0.96–1.06), $P = 0.761$
Hyperemia	$r = -0.029$, $P = 0.741$	HR = 0.96 (0.87–1.04), $P = 0.346$

Unadjusted data are expressed as r and P -value (in bold when significance is present). Age, waist, calculated free testosterone and smoking habit adjusted data are expressed as adjusted r (adj. r) or as hazard ratio (HR) when appropriate.

^aTestosterone and calculated free testosterone have been adjusted for age, waist and smoking habit.

^bCalcifications with size >3 mm (according to Lotti *et al.*, 2011).

^cCalculated using the 'ellipsoid/prolate ($d1 > d2 = d3$) spheroid' formula ($d1 \times d2 \times d3 \times 4/3\pi$, considering $d1 =$ half of the maximum longitudinal diameter of the SV and both $d2$ and $d3 =$ half of the anterior-posterior maximum diameter) (according to Lotti *et al.*, 2012a).

^dCalculated as $[(\text{pre-ejaculatory total volume} - \text{post-ejaculatory total volume})/\text{pre-ejaculatory volume}] \times 100$ (according to Lotti *et al.*, 2012a).

^eSevere echographic-defined varicocele with basal venous reflux increasing after Valsalva's maneuver (according to Isidori and Lenzi, 2008).

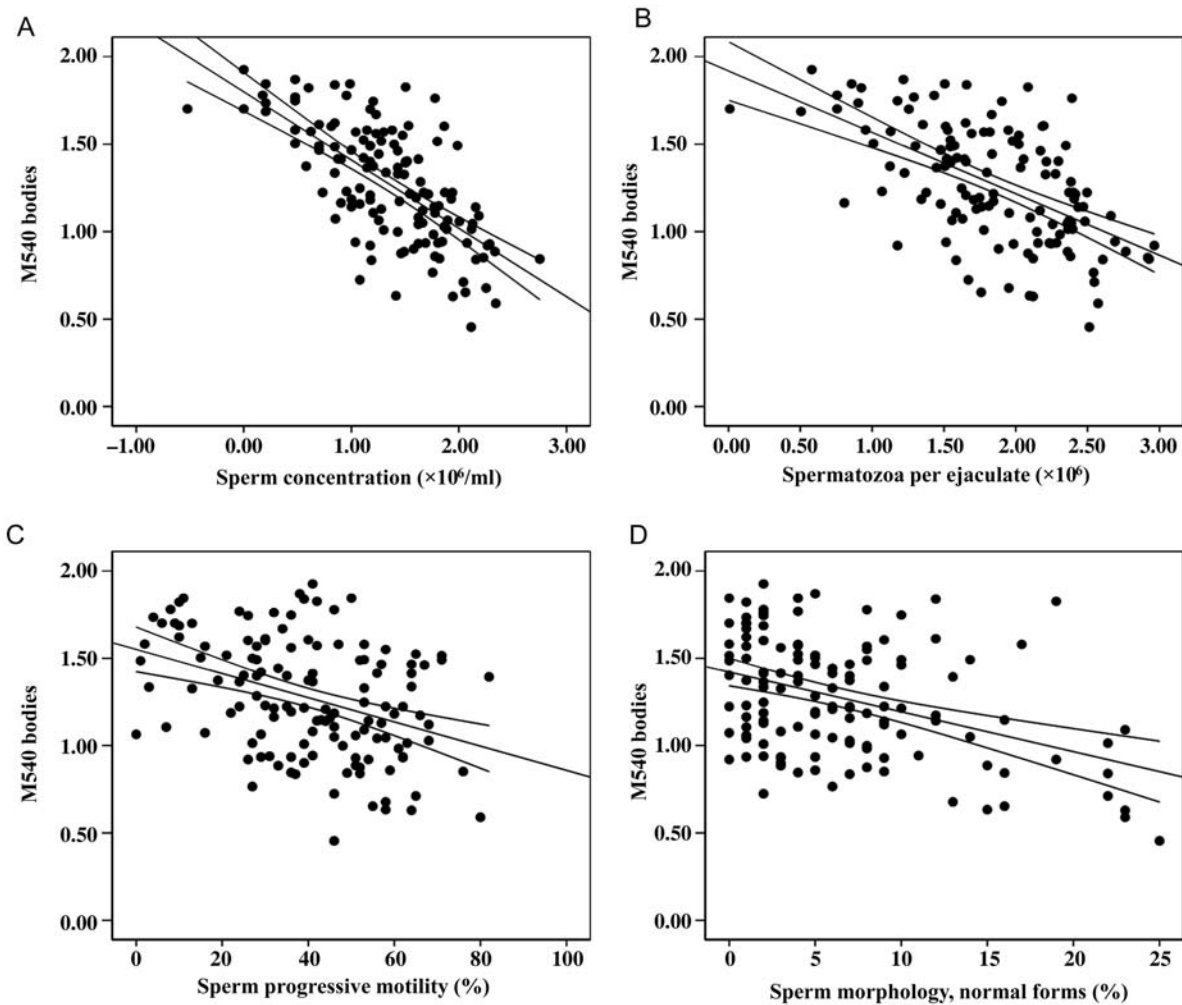


Figure 1 Correlations between M540 body levels and sperm parameters. Correlations between M540 bodies and sperm concentration (**A**), total sperm count (**B**), sperm progressive motility (**C**) and normal morphology (**D**). Results have been adjusted for age, waist, calculated free testosterone and smoking habit. M540 body levels are reported in a log-scale. In (A) and (B), sperm number per milliliter or per ejaculate, respectively, is expressed on the abscissa as a log-scale. In (C) and (D), sperm progressive motility and normal morphology, respectively, are expressed as continuous variables. Adjusted regression coefficients for the different parameters are shown in Table 1.

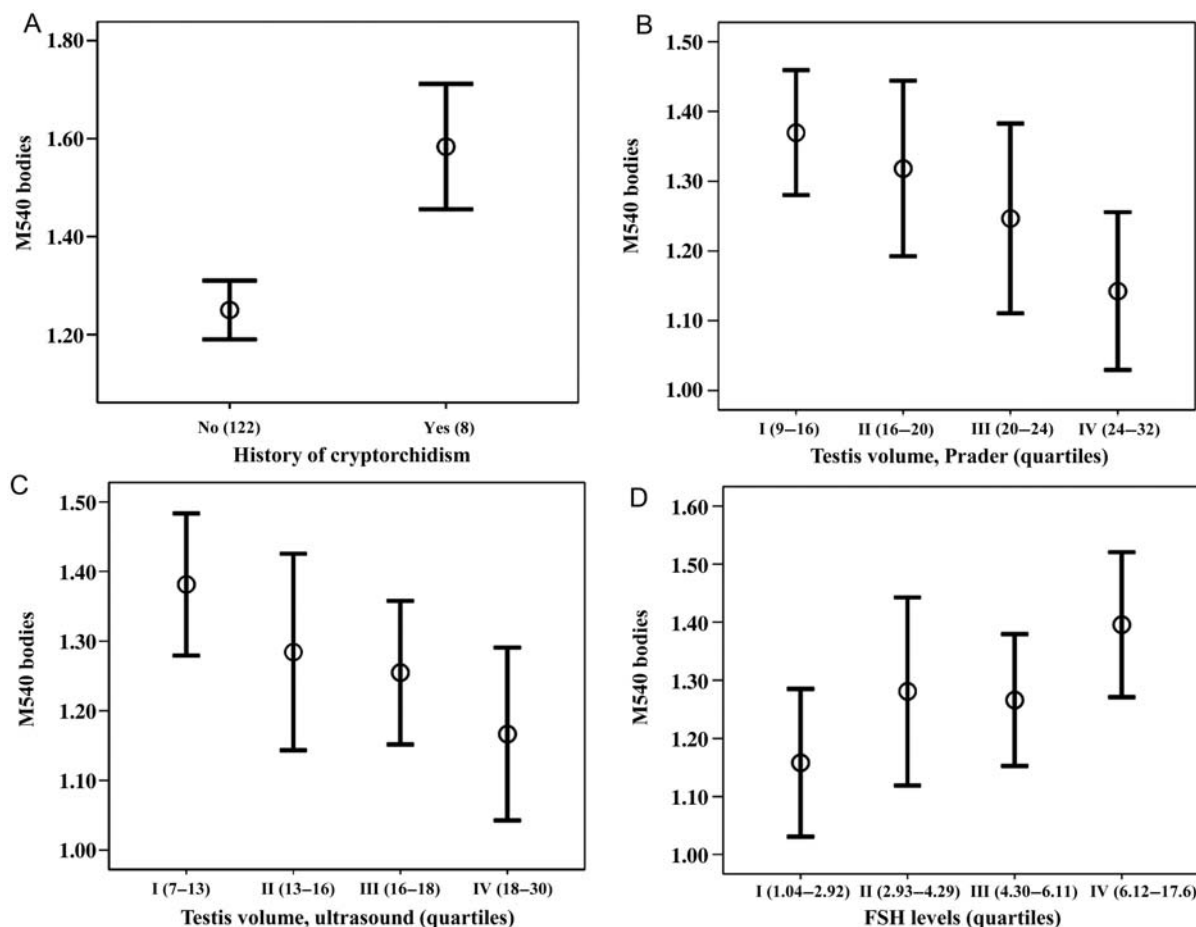


Figure 2 Relationship between M540 body levels, history of cryptorchidism, testicular volume and FSH serum levels. (A) M540 body levels in subjects with and without history of cryptorchidism. M540 body levels and testicular volume assessed by Prader orchidometer (B) and ultrasound (C). (D) M540 body levels and serum FSH levels. Results have been adjusted for age, waist, calculated free testosterone and smoking habit. M540 body levels are expressed as a log-scale. In (B), (C) and (D), the testicular volume assessed by Prader or ultrasound and the FSH levels, respectively, are expressed on the abscissa as quartiles. Adjusted regression coefficients for the testis volume (Prader and ultrasound) and FSH levels and hazard ratio values for the history of cryptorchidism are shown in Table I.

Relation between M540 bodies and clinical and hormonal parameters

M540 body levels were negatively correlated with mean testis volume, as assessed by both Prader orchidometer and ultrasound (Table I and Fig. 2B and C). When hormone parameters were considered, a significant correlation between M540 bodies and FSH levels was found (Fig. 2D). Conversely, no correlation with testosterone or calculated free testosterone levels was observed, even after adjustment for age, waist and smoking habit (Table I).

Relation between M540 bodies and ultrasound parameters

When scrotal and transrectal CDU parameters were considered, a significant association between M540 body levels and the detection of testis inhomogeneity or hypoechogenicity (Fig. 3A and B) was evident. Conversely, levels of M540 bodies in the seminal plasma were not related to any CDU characteristic of the prostate, seminal

vesicles, epididymis and vas deferens, even after adjustment for confounders (Table I).

In a multivariate model, when testicular ultrasound parameters (volume, inhomogeneity and hypoechogenicity) were introduced as putative predictors for M540 body levels in semen along with age, waist, calculated free testosterone and smoking habit, we found that only inhomogeneity was independently associated with M540 bodies ($\text{adj.}r = 0.397$, $P = 0.02$). When also the history of cryptorchidism and FSH levels were introduced in the same multivariate model, we found that testis inhomogeneity and history of cryptorchidism were independently associated with M540 body levels ($\text{adj.}r = 0.355$, $P < 0.01$ and $\text{adj.}r = 0.223$, $P < 0.05$ for testis inhomogeneity and history of cryptorchidism, respectively). Receiver operating characteristic, a graphical plot of the sensitivity and specificity or true positive rate versus false positive rate, was used as a binary classifier system to identify the accuracy of M540 bodies in predicting testis inhomogeneity. At the threshold of 27%, M540 bodies predict the occurrence of testis inhomogeneity with an accuracy of $77.4 \pm 4.4\%$ ($P < 0.0001$),

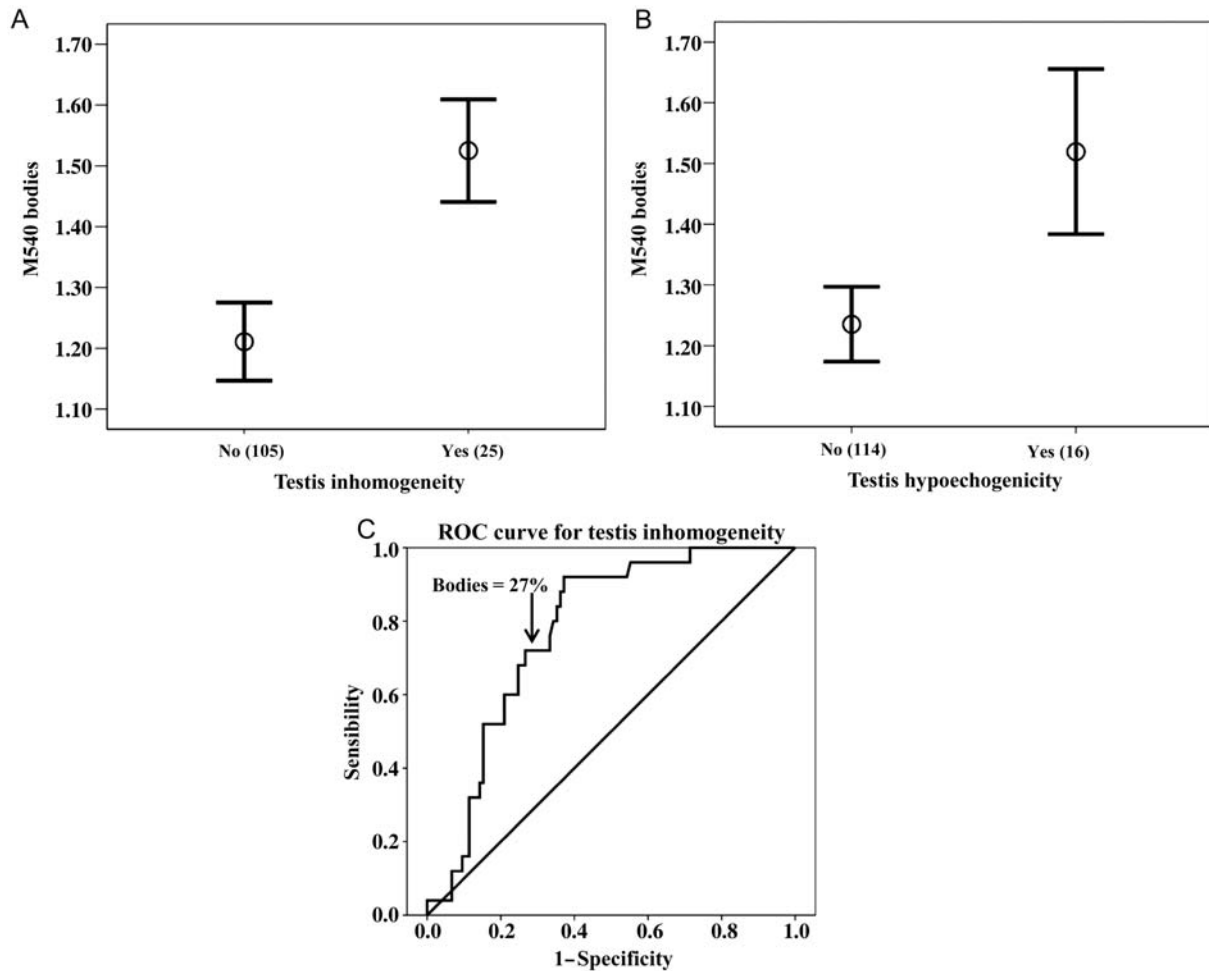


Figure 3 Correlations between M540 body levels and the testicular echo-pattern. M540 bodies and testicular inhomogeneity (A) or hypoechoogenicity (B). Results have been adjusted for age, waist, calculated free testosterone and smoking habit. M540 body levels are expressed as a log-scale. (C) Receiver operating characteristic curve for M540 body levels as a function of testis inhomogeneity. Hazard ratio values for testis inhomogeneity and hypoechoogenicity are shown in Table I.

showing a sensitivity and specificity of 72 and 73%, respectively (Fig. 3C). At the same threshold, M540 body levels were associated with an elevated FSH level (>8 U/l; Andersson *et al.*, 2004) and a history of cryptorchidism with specificity of 68.5 and 66.9% and sensitivity of 57.1 and 75% and HR of 3.9 (1.1–14), $P < 0.05$, and 12.6 (1.4–113), $P < 0.05$, respectively.

To evaluate whether the observed associations between levels of M540 bodies and testis ultrasound characteristics or semen parameters were confirmed in subjects without cryptorchidism, patients with a positive history ($n = 8$) were excluded from the analysis. The associations between levels of M540 bodies, FSH levels, testis volume and inhomogeneity were confirmed even when subjects with a positive history of cryptorchidism were excluded from the analysis (not shown).

Discussion

The results of this study strongly suggest that apoptotic M540 bodies present in semen (Muratori *et al.*, 2004; Marchiani *et al.*, 2007) are

specifically associated with testis abnormalities and not with abnormalities of other portions of the male genital tract (epididymis, vas deferens, prostate and seminal vesicles). Hence, M540 bodies most probably originate from the testis and may be considered a reliable readout of testis apoptosis and disrupted spermatogenesis. Indeed, we now show that semen M540 body levels are strictly correlated with several clinical and CDU parameters suggestive of a testicular damage, including high FSH levels, testicular hypotrophy, inhomogeneity or hypoechoogenicity, but are not related to abnormalities of other parts (epididymis, seminal vesicles and prostate) of the male genital tract. In addition, M540 body levels were 2-fold higher in patients with a history of cryptorchidism.

We have previously shown that M540 body levels are negatively correlated with total sperm number, being particularly elevated in oligoasthenoteratozoospermic subjects (Muratori *et al.*, 2005; Marchiani *et al.*, 2007). In the present study, we extend such findings by showing a negative relationship between M540 bodies and parameters of sperm quality in a wider study population (130 subjects). However,

the occurrence of a negative relationship between M540 bodies and sperm quality does not necessarily imply impairment of testis function, as apoptotic bodies may also derive from other parts of male genital tract, including epididymis, prostate or seminal vesicles. But the lack of association between M540 bodies and extra-testicular CDU abnormalities or signs of infection (current positive urine or sperm cultures) argues against this possibility. In addition, seminal levels of IL-8, a surrogate marker of inflammation of the prostate (Penna et al., 2007) or epididymis, but not of the testis (Lotti et al., 2011), were even negatively associated with M540 bodies, further suggesting their testicular origin.

We here report for the first time that semen M540 bodies are associated with a reduced testicular volume and occur at higher levels when testis inhomogeneity or hypoechogenicity are present. Testis inhomogeneity and hypoechogenicity at ultrasonography are suggestive of atrophy and fibrosis (Loberant et al., 2010) and considered important signs of a reduced testicular function and overall impairment of spermatogenesis (Lenz et al., 1993; Behre et al., 1995). In addition, testicular volume is generally accepted as a parameter positively related to sperm count (Lenz et al., 1993; Behre et al., 1995, 2000). Seminal levels of M540 bodies are also positively associated with higher FSH serum levels, an index of primitive testicular damage (Bergmann and Guthoff, 1994; Forti and Krausz, 1998). Overall, these results indicate that M540 bodies may be considered a sign of a derangement of spermatogenesis due to testicular damage.

In our previous studies, we have clearly demonstrated that M540 bodies are apoptotic bodies, as they stain for merocyanine 540 (which reveals apoptosis-related membrane modifications) and contain several apoptotic markers, including Fas and caspase activity (Muratori et al., 2004; Marchiani et al., 2007). In the testis, the process of apoptosis is considered a physiological event which regulates the ratio between germ cells and Sertoli cells in the seminiferous tubule and may occur both by intrinsic and extrinsic pathways (Shaha et al., 2010; Shukla et al., 2012). In testis from patients with meiotic and post-meiotic arrest of spermatogenesis, apoptotic cells are mostly primary spermatocytes and, to a lesser extent, round or early elongating spermatids (Francavilla et al., 2002). Interestingly, degenerated germ cells demonstrate an increased expression of Fas (Francavilla et al., 2000, 2002), suggesting a link between Fas expression, testis apoptosis and efficiency of spermatogenesis (Francavilla et al., 2000). Thus, a derangement of testis apoptosis is associated with a reduction in sperm quality and the occurrence of high levels of M540 bodies may indicate such a derangement. Interestingly, we show here that at the level of 27%, M540 body semen levels are able to discriminate subjects with and without testis inhomogeneity, suggesting that this CDU sign might be related to alterations of spermatogenesis and of the apoptotic process in the testis.

The apoptotic process is usually followed by dead cell/residual body removal by macrophages or other tissue resident cells involved in phagocytosis. In the testis, apoptotic germ cells appear to be eliminated either in the seminiferous lumen or may be phagocytated by Sertoli cells (Francavilla et al., 2002). Recently, it has been shown that the disruption of Sertoli cell-mediated removal of apoptotic germ cells and apoptotic bodies in the testis in an animal model leads to loss of normal testis tubule architecture due to an increase in multinucleated giant cells and apoptotic germ cells, which ultimately leads to loss of spermatogenesis (Elliott and Ravichandran, 2010).

The occurrence of apoptotic (M540) bodies in semen suggests that they escape the Sertoli cell-mediated phagocytotic process. It is possible that if a great number of cells undergoes the apoptotic process, as may be in the case of subjects with a derangement of testis apoptosis, the number of apoptotic bodies that are formed is greater than those that can be removed, as occurs in the animal model of disrupted Sertoli cell-mediated phagocytosis (Elliott and Ravichandran, 2010). In our previous study (Muratori et al., 2004), we demonstrated that M540 bodies do not express phosphatidylserine on their surface. Although phosphatidylserine is not the only 'eat-me' signal in apoptotic cells, it is the most universally seen alteration on the surface of apoptotic cells, observed in several cell types and even after different pathways of apoptotic induction (Ravichandran, 2011). It is thus possible to postulate that M540 bodies escape the Sertoli cell-mediated phagocytosis process also because they lack such an 'eat-me' signal on their surface. However, whether the occurrence of M540 bodies in semen is to be ascribed to escape from Sertoli cell-mediated phagocytosis or increased testis apoptosis remains to be determined. The occurrence of M540 (apoptotic) bodies in semen supports the abortive apoptosis theory (Sakkas et al., 1999), according to which the occurrence of apoptosis-like signals in the ejaculate may be also explained by an escape from the phagocytotic process.

Infertile males with a history of testicular maldescent are often characterized by lower semen quality due to an irreversible damage of the tubular compartment despite orchidopexy (Toppari and Kaleva, 1999). Our study demonstrates a positive association between M540 bodies and a history of cryptorchidism. Moreover, at the previously established level of 27%, M540 bodies are associated with a consistent increased risk of cryptorchidism and of elevated FSH. The mechanism responsible for decreased semen quality in men with a positive history of cryptorchidism are not entirely known; in particular, it is not clear whether the degeneration of gonocytes is caused by a higher temperature in the maldescent testis compared with scrotal testis or by other mechanisms (Shaha et al., 2010; Agoulnik et al., 2012). In experimental models of cryptorchidism, an increase in testicular expression of apoptotic markers has been demonstrated (Xu et al., 2000; Yin et al., 2002; Zhang et al., 2003). Moreover, electron microscopy analysis of spermatozoa from a group of patients with a history of cryptorchidism demonstrates the presence of signs of apoptosis and necrosis (Moretti et al., 2007).

In the present study, we used a fluorescent technique coupled to flow cytometry for the assessment of M540 body levels in semen. This technique allows a precise measure of their levels which may be particularly important when testicular damage is suspected. Indeed, in cases where these levels are higher than 27%, testis ultrasound could show an inhomogeneous echopattern. However, as shown in Supplementary Fig. S1 and in previous studies from our group (Muratori et al., 2004; Marchiani et al., 2007), M540 bodies can be easily distinguished and evaluated during semen analysis after staining of the sample (World Health Organization, 2010) because of their lack of nuclei.

We must recognize as a limitation of the present study the fact that our conclusions are based only on associations and not on interventions; hence, the described relationships should be considered more as correlates than as proofs.

In conclusion, this study indicates that high levels of apoptotic M540 bodies in semen are suggestive of the disruption of spermatogenesis

efficiency and are uniquely associated with testicular abnormalities, suggesting a testicular origin for these apoptotic bodies.

Supplementary data

Supplementary data are available at <http://humrep.oxfordjournals.org/>.

Acknowledgements

We thank Dr E. Filimberti (Semen analysis laboratory, Sexual Medicine and Andrology Unit) for technical assistance.

Authors' roles

F.L.: patients recruitment, anamnesis, ultrasound performance, data collection and analyses; L.T.: evaluation of M540 bodies in semen, data collection and analyses; S.M.: evaluation of M540 bodies and data collection; M.M.: data collection and analyses, contribution to data interpretation, writing and critical revision of the MS; M.G.F. and S.D.: semen analyses and evaluation of IL-8 semen levels; G.F.: patient recruitment and visiting for inclusion in the study; M.M. and E.B.: conception of design of the study, drafting of the article and data interpretation; all the authors contributed to conception, writing, revision and final approval of the MS. G.C.: statistical analysis, revision of the manuscript.

Funding

This work was supported by grants from Ministry of University and Scientific Research (Prin project to E.B. and FIRB project to S.M.) and Regione Toscana to G.F.

Conflict of interest

None declared.

References

- Agoulnik AI, Huang Z, Ferguson L. Spermatogenesis in cryptorchidism. *Methods Mol Biol* 2012;**825**:127–147.
- Andersson AM, Petersen JH, Jørgensen N, Jensen TK, Skakkebaek NE. Serum inhibin B and follicle-stimulating hormone levels as tools in the evaluation of infertile men: significance of adequate reference values from proven fertile men. *J Clin Endocrinol Metab* 2004;**89**:2873–2879.
- Attaman JA, Toth TL, Furtado J, Campos H, Hauser R, Chavarro JE. Dietary fat and semen quality among men attending a fertility clinic. *Hum Reprod* 2012;**27**:1466–1474.
- Behre HM, Kliesch S, Schädel F, Nieschlag E. Clinical relevance of scrotal and transrectal ultrasonography in andrological patients. *Int J Androl* 1995;**2**:27–31.
- Behre HM, Yeung CH, Holstein AF, Weinbauer GF, Gassner P, Nieschlag E. Diagnosis of male infertility and hypogonadism. In: Nieschlag E, Behre HM (eds). *Andrology: Male Reproductive Health and Dysfunction*, 2nd edn. Heidelberg: Springer, 2000,90–124.
- Bergmann U, Guthoff R. Clinical decision aids using ultrasound biomicroscopy. *Klin Monbl Augenheilkd* 1994;**205**:361–363.
- Bertolotto M, Trombetta C. *Scrotal Pathology. Medical Radiology. Diagnostic Imaging*. Berlin: Springer-Verlag, 2012.
- Brinkworth MH, Weinbauer GF, Bergmann M, Nieschlag E. Apoptosis as a mechanism of germ cell loss in elderly men. *Int J Androl* 1997;**20**:222–228.
- Christiansen JD, Dogra VS. The undescended testis. *Semin Ultrasound CT MRI* 2007;**28**:307–316.
- Cohn EL, Watson L, Older R, Moran R. Striated pattern of the testicle on ultrasound: an appearance of testicular fibrosis. *J Urol* 1996;**156**:180–181.
- Colpi GM, Negri L, Nappi RE, China B. Is transrectal ultrasonography a reliable diagnostic approach in ejaculatory duct sub-obstruction? *Hum Reprod* 1997;**12**:2186–2191.
- Elliott MR, Ravichandran KS. ELMO1 signaling in apoptotic germ cell clearance and spermatogenesis. *Ann N Y Acad Sci* 2010;**1209**:30–36.
- Forti G, Krausz C. Clinical review 100: Evaluation and treatment of the infertile couple. *J Clin Endocrinol Metab* 1998;**83**:4177–4188.
- Francavilla S, D'Abrizio P, Rucci N, Silvano G, Properzi G, Straface E, Cordeschi G, Necozone S, Gnessi L, Arizzi M et al. Fas and Fas ligand expression in fetal and adult human testis with normal or deranged spermatogenesis. *J Clin Endocrinol Metab* 2000;**85**:2692–2700.
- Francavilla S, D'Abrizio P, Cordeschi G, Pelliccione F, Necozone S, Ulisse S, Properzi G, Francavilla F. Fas expression correlates with human germ cell degeneration in meiotic and post-meiotic arrest of spermatogenesis. *Mol Hum Reprod* 2002;**8**:213–220.
- Isidori AM, Lenzi A. *Scrotal CDU: Morphological and Functional Atlas*. Geneva: Forum Service Editore s.r.l., 2008.
- Kim SK, Lee HJ, Yang H, Kim HS, Yoon YD. Prepubertal exposure to 4-tert-octylphenol induces apoptosis of testicular germ cells in adult rat. *Arch Androl* 2004;**50**:427–441.
- Lenz S, Giwercman A, Elsborg A, Cohr KH, Jelnes JE, Carlsen E, Skakkebaek NE. Ultrasonic testicular texture and size in 444 men from the general population: correlation to semen quality. *Eur Urol* 1993;**24**:231–238.
- Loberant N, Bhatt S, McLennan GT, Dogra VS. Striated appearance of the testes. *Ultrasound Q* 2010;**26**:37–44.
- Lotti F, Corona G, Mancini M, Filimberti E, Degli Innocenti S, Colpi GM, Baldi E, Noci I, Forti G, Adorini L et al. Ultrasonographic and clinical correlates of seminal plasma interleukin-8 levels in patients attending an andrology clinic for infertility. *Int J Androl* 2011;**34**:600–613.
- Lotti F, Corona G, Colpi G, Filimberti E, Degli Innocenti S, Mancini M, Baldi E, Noci I, Forti G, Maggi M. Seminal vesicles ultrasound features in a cohort of infertility patients. *Hum Reprod* 2012a;**27**:974–982.
- Lotti F, Corona G, Rastrelli G, Forti G, Jannini EA, Maggi M. Clinical correlates of erectile dysfunction and premature ejaculation in men with couple infertility. *J Sex Med* 2012b. [Epub ahead of print].
- Marchiani S, Tamburrino L, Maoggi A, Vannelli GB, Forti G, Baldi E, Muratori M. Characterization of M540 bodies in human semen: evidence that they are apoptotic bodies. *Mol Hum Reprod* 2007;**13**:621–631.
- Moretti E, Di Cairano G, Capitani S, Scapigliati G, Baccetti B, Collodel G. Cryptorchidism and semen quality: a TEM and molecular study. *J Androl* 2007;**28**:194–199.
- Muratori M, Porazzi I, Luconi M, Marchiani S, Forti G, Baldi E. AnnexinV binding and merocyanine staining fail to detect human sperm capacitation. *J Androl* 2004;**25**:797–810.
- Muratori M, Marchiani S, Forti G, Baldi E. Sperm ubiquitination positively correlates to normal morphology in human semen. *Hum Reprod* 2005;**20**:1035–1043.
- Penna G, Mondaini N, Amuchastegui S, Degli Innocenti S, Carini M, Giubilei G, Fibbi B, Colli E, Maggi M, Adorini L. Seminal plasma cytokines and chemokines in prostate inflammation: interleukin 8 as a

- predictive biomarker in chronic prostatitis/chronic pelvic pain syndrome and benign prostatic hyperplasia. *Eur Urol* 2007;**51**:524–533.
- Rajpurkar A, Jiang Y, Dhabuwala CB, Dunbar JC, Li H. Cigarette smoking induces apoptosis in rat testis. *J Environ Pathol Toxicol Oncol* 2002;**21**:243–248.
- Ravichandran KS. Beginnings of a good apoptotic meal: the find-me and eat-me signaling pathways. *Immunity* 2011;**35**:445–455.
- Rucker EB 3rd, Dierisseau P, Wagner KU, Garrett L, Wynshaw-Boris A, Flaws JA, Hennighausen L. Bcl-x and Bax regulate mouse primordial germ cell survival and apoptosis during embryogenesis. *Mol Endocrinol* 2000;**14**:038–052.
- Sakkas D, Mariethoz E, St John JC. Abnormal sperm parameters in humans are indicative of an abortive apoptotic mechanism linked to the Fas-mediated pathway. *Exp Cell Res* 1999;**251**:350–355.
- Shaha C. Estrogens and spermatogenesis. *Adv Exp Med Biol* 2008;**636**:42–64.
- Shaha C, Tripathi R, Mishra DP. Male germ cell apoptosis: regulation and biology. *Philos Trans R Soc Lond B Biol Sci* 2010;**365**:1501–1515.
- Shukla KK, Mahdi AA, Rajender S. Apoptosis, spermatogenesis and male infertility. *Front Biosci (Elite Ed)* 2012;**4**:746–754.
- Toppari J, Kaleva M. Maldescendus testis. *Horm Res* 1999;**51**:261–269.
- Vermeulen A, Verdonck L, Kaufman JM. A critical evaluation of simple methods for the estimation of free testosterone in serum. *J Clin Endocrinol Metab* 1999;**84**:3666–3672.
- Vicari E. Seminal leukocyte concentration and related specific reactive oxygen species production in patients with male accessory gland infections. *Hum Reprod* 1999;**14**:2025–2030.
- World Health Organization. *WHO Laboratory Manual for the Examination of Human Semen and Sperm-Cervical Mucus Interaction*, 4th edn. New York: Cambridge University Press, 1999.
- World Health Organization. *WHO Laboratory Manual for the Examination and Processing of Human Semen*, 5th edn. Switzerland: WHO Press, 2010.
- Xu J, Xu Z, Jiang Y, Qian X, Huang Y. Cryptorchidism induces mouse testicular germ cell apoptosis and changes in bcl-2 and bax protein expression. *J Environ Pathol Toxicol Oncol* 2000;**19**:25–33.
- Yin Y, Stahl BC, DeWolf WC, Morgentaler A. P53 and Fas are sequential mechanisms of testicular germ cell apoptosis. *J Androl* 2002;**23**:64–70.
- Zhang ZH, Jin X, Zhang XS, Hu ZY, Zou RJ, Han CS, Liu YX. Bcl-2 and Bax are involved in experimental cryptorchidism-induced testicular germ cell apoptosis in rhesus monkey. *Contraception* 2003;**68**:297–301.