

This is an Open Access article licensed under the terms of the Creative Commons Attribution-NonCommercial 3.0 Unported license (CC BY-NC) (www.karger.com/OA-license), applicable to the online version of the article only. Distribution permitted for non-commercial purposes only.

Published: January 2014

Aggressive Gastric Carcinoma Producing Alpha-Fetoprotein: A Case Report and Review of the Literature

A. Lunghi^a P. Petreni^a R.G. Romanelli^b F. Vizzutti^b F. Marra^b
R. Tarquini^b G. Laffi^b

^aDipartimento di Oncologia, Oncologia Medica, Azienda Ospedaliero-Universitaria Careggi, and ^bDipartimento di Medicina Interna, Medicina ed Epatologia, Azienda Ospedaliero-Universitaria Careggi, Florence, Italy

Key Words

Alpha-fetoprotein · Gastric cancer · Tumor marker · Liver metastases

Abstract

A 65-year-old man presented to our hospital with abdominal pain, dyspepsia and anorexia. Laboratory tests showed an altered liver function and abdomen ultrasonography revealed multiple liver nodules, suspected to be metastatic lesions. Serous tumor markers were elevated and a very high level of alpha-fetoprotein was found. Computer tomography confirmed the hepatic lesions and disclosed a thickening of the lesser curvature of the gastric wall. A subsequent endoscopy showed an ulcer on the lesser curvature. Biopsies taken from the gastric ulcer and the liver nodule revealed an adenocarcinoma, both of gastric origin. Shortly after the diagnosis, the patient's condition worsened and he died only 15 days later. This case report illustrates how alpha-fetoprotein-producing gastric adenocarcinomas have a high incidence of venous and lymphatic invasion and a rapid hepatic spread with a very poor prognosis.

© 2014 S. Karger AG, Basel

Case Presentation

In September 2011, a 65-year-old Caucasian man was admitted to our hospital after a 1-month history of epigastric pain, dyspepsia, and anorexia. He had been treated with a proton-pump inhibitor for 2 months. He had a history of type 2 diabetes mellitus, arterial

A. Lunghi, MD
Dipartimento di Oncologia, Oncologia Medica
Azienda Ospedaliero-Universitaria Careggi
L. go Brambilla 3, Florence (Italy)
E-Mail lunghi.alice@gmail.com

hypertension, and dyslipidemia. At physical examination, intense abdominal pain in the upper abdominal quadrants was noted. Laboratory tests showed elevated aspartate transaminase 107 U/l (reference range 10–40 U/l), alanine transaminase 89 U/l (reference range 10–40 U/l), gamma-glutamyl transpeptidase 627 U/l (reference range 10–40 U/l) and alkaline phosphatase 309 U/l (reference range 40–130 U/l); total bilirubin was 1.07 mg/dl (reference range 0.3–1.0 mg/dl). Ultrasonography showed a remarkable and irregular enlargement of the liver with multiple and diffuse nodules in the right hepatic lobe (the largest measured 5 cm in diameter) and a unique large mass (15 × 9 cm) in the left lobe. Abdomen computer tomography scans showed multiple nodules in the liver, suspected to be metastatic lesions, portal vein thrombosis, multiple adenopathies along the lesser curvature of the stomach, the mesenteric root and the lumbo-aortic region as well as a thickening of the gastric lesser curvature wall (fig. 1 a, b). Tumor markers were: alpha-fetoprotein (AFP) 209093 U/ml (reference range 0–10 U/ml), Ca 19.9 170,5 U/ml (reference range 0–39 U/ml), and Ca 125 52,2 U/ml (reference range 0–35 U/ml); other markers were found to be in a normal range, in particular CEA and Ca 72.4. Markers for hepatitis B and C were negative (HBsAg, HBV-DNA and HCV IgG). An esophagogastroduodenoscopy showed a 4 cm ulcer on the lesser curvature of the stomach (fig. 2). At the pathologic examination, the biopsy revealed a gastric adenocarcinoma. The biopsy of one of the hepatic nodules showed a poorly differentiated adenocarcinoma, similar to that of a gastric biopsy. Immunohistochemical findings showed a positivity for CAM 5.2, CDX 2 CK 20 and a negativity for CD10, TTF1, sinaptophysin and chromogranin A, therefore supporting a diagnosis of metastasis of gastric adenocarcinoma (fig. 3). One week later, the patient's condition quickly worsened (Performance Status 3 in accordance with the European Cooperative Oncology Group scale). He presented jaundice, abdominal pain and, at palpation, the appearance of a solid mass in the left upper quadrant of the abdomen and liver enlargement. Levels of transaminases, gamma-glutamyl transpeptidase and alkaline-phosphatase increased; total bilirubin was 19.6 mg/dl and the conjugated one was 12.8 mg/dl. Abdominal ultrasonography showed, with respect to the previous one, an increased number and size of the hepatic nodules as well as a biliary tract dilatation. Tumor markers were found to be increased further: AFP 470396 U/ml, Ca 19.9 354.0 U/ml, and Ca 125 113.7 U/ml. A chemotherapeutic approach was excluded due to the patient's poor condition, his performance status and the altered liver function tests. The patient was discharged and received the best possible supportive care. He died 15 days later.

Discussion

Gastric adenocarcinoma is a neoplasm with a frequent association to various tumor markers such as Ca 72.4, CEA and Ca 19.9. In our case report, elevated serum AFP levels were present in a patient with gastric adenocarcinoma and liver metastases. AFP is a well-known embryonic serum protein, produced by fetal liver cells, yolk sac cells and some fetal gastrointestinal cells [1]. The elevation of serum AFP, in conjunction with the hepatic lesions, may be associated with hepatocellular carcinoma or germ-cell tumors. However, AFP can be produced exceptionally by gastrointestinal tract organs [1], the lung [2], the bladder [3] and by renal cancers [4]. For diseases such as chronic hepatitis, liver cirrhosis and hepatocellular carcinoma, the level of AFP is a good predictor of disease progression and outcome, as it is directly correlated to disease progression [5, 6].

Gastric cancer with the capability of releasing AFP is called AFP-producing gastric carcinoma, first described by Boureille et al. [7] in 1970. Only a few cases have been reported with an incidence rate of 2.7–8.0% of all gastric malignant tumors [8]. The majority of cases

described in the literature refer to Asian people [9]. Our case is one of the few European cases of AFP-producing gastric carcinomas. However, the serum AFP level does not necessarily correlate with tumor size, stage or prognosis [6, 8, 10]. In our case, elevated serum levels of AFP and his quick increase were associated with a rapid disease progression and a fatal outcome.

Cases of AFP-producing gastric cancers are characterized by a poor prognosis, a high incidence of venous invasion, by lymph node and liver metastases and even T1 tumors (according to the TNM staging system) [5]. The exact molecular mechanisms explaining this aggressive behavior is still unclear. Possible causes of liver metastases have been hypothesized in the hepatic capability to develop a suitable environment for the cancer cells growth and to promote an early vascular invasion [5].

Conclusions

AFP-producing gastric cancers are a small subgroup of gastric cancers, with a high likelihood of rapid hepatic metastasization. We think that further studies, especially on a cellular and molecular level, are necessary to explain the highly aggressive biological behavior of AFP-producing gastric cancers in order to develop an effective multimodal and targeted therapy.

Acknowledgements

The authors would like to thank the Department of Internal Medicine, Internal Medicine and Liver Unit, Azienda Ospedaliero-Universitaria Careggi, School of Medicine, University of Florence, Florence, Italy, and Umberto Arena, MD, ultrasonography consultant. We also thank Simonetta Viviani, MD, for her contribution in the production of this paper.

Disclosure Statement

The authors declare that there are no conflicts of interest regarding the publication of this paper.

References

- 1 Gitlin D, Pericelli A, Gitlin G: Synthesis of alpha-fetoprotein by liver, yolk sac and gastrointestinal tract of the human conceptus. *Cancer Res* 1972;32:979–982.
- 2 Hiroshima K, Iyoda A, Toyozaki T, Haga Y, Baba M, Fujisawa T, Ishikura H, Ohwada H: Alpha-fetoprotein-producing lung carcinoma: report of three cases. *Pathol Int* 2002;52:46–53.
- 3 Takayama H: A case of bladder cancer producing alpha-fetoprotein (AFP) (in Japanese). *Hinyokika Kyo* 1995;41:387–389.
- 4 Morimoto H, Tanigawa N, Inoue H, Muraoka R, Hosokawa Y, Hattori T: Alpha-fetoprotein-producing renal cell carcinoma. *Cancer* 1988;61:84–88.
- 5 Liu X, Cheng Y, Sheng W, Lu H, Xu Y, Long Z, Zhu H, Wang Y: Clinicopathologic features and prognostic factors in alpha-fetoprotein-producing gastric cancers: analysis of 104 cases. *J Surg Oncol* 2010;102:249–255.
- 6 Inoue M, Sano T, Kuchiba A, Taniguchi H, Fukagawa T, Katai H: Long-term results of gastrectomy for alpha-fetoprotein-producing gastric cancer. *Br J Surg* 2010;97:1056–1061.
- 7 Bourreille J, Metayer P, Sauger F, Matray F, Fondimare A: Existence of alpha feto protein during gastric-origin secondary cancer of the liver (in French). *Presse Med* 1970;78:1277–1278.

- 8 Kono K, Amemiya H, Sekikawa T, Iizuka H, Takahashi A, Fujii H, et al: Clinicopathologic features of gastric cancers producing alpha-fetoprotein. *Dig Surg* 2002;19:359–365.
- 9 Li XD, Wu CP, Ji M, Wu J, Lu B, Shi HB, Jiang JT: Characteristic analysis of α -fetoprotein-producing gastric carcinoma in China. *World J Surg Oncol* 2013;11:246.
- 10 Adachi Y, Tsuchihashi J, Shiraishi N, Yasuda K, Etoh T, Kitano S: AFP-producing gastric carcinoma: multivariate analysis of prognostic factors in 270 patients. *Oncology* 2003;65:95–101.

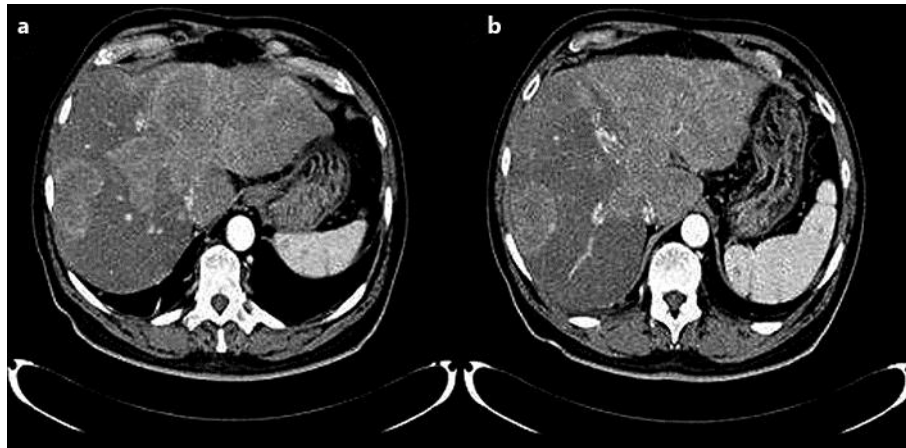


Fig. 1. Computer tomography image of metastatic lesions in the liver (a, b).

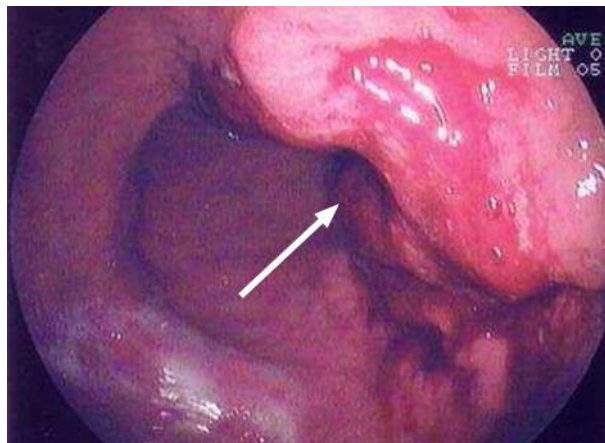


Fig. 2. Esophagogastroduodenoscopy image of a bleeding gastric ulcer (see arrow).

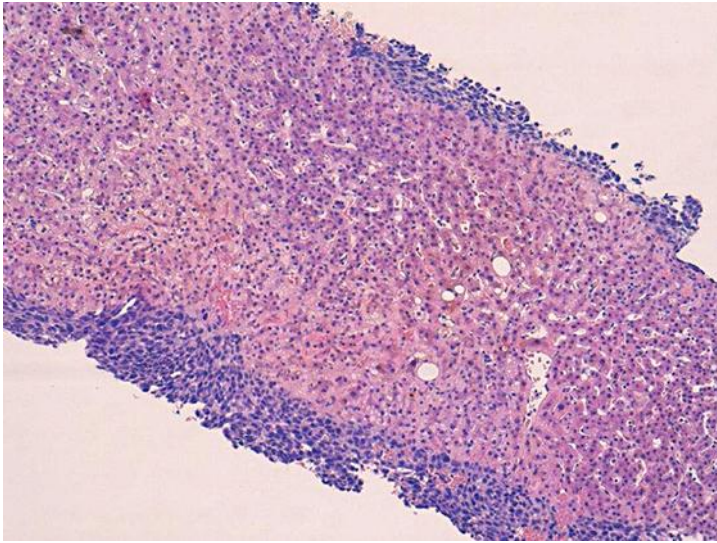


Fig. 3. Histologic evaluation of the hepatic biopsy.