

Tumor Angiogenesis in Lymph Node–Negative Rectal Cancer: Correlation With Clinicopathological Parameters and Prognosis

Fabio Cianchi, MD, Annarita Palomba, MD, Luca Messerini, MD, Vieri Boddi, BS, Grazia Asirelli, BS, Giuliano Perigli, MD, Paolo Bechi, MD, Antonio Taddei, MD, Filippo Pucciani, MD, and Camillo Cortesini, MD

Background: Intratumoral microvessel density (MVD) could be used as a prognostic factor in colorectal cancer. We retrospectively analyzed the value of microvessel count in predicting the clinical outcome of stage I and II (Dukes A and B) rectal cancer patients.

Methods: Eighty-four patients who had undergone curative resection of lymph node–negative rectal cancer were included. Tumor type and differentiation, the depth of local invasion, venous invasion, the character of the invasive margin, and the degree of lymphocytic infiltration were evaluated for each tumor specimen. Immunohistochemical staining for the CD31 endothelial antigen was performed to highlight the microvessels.

Results: The median value of MVD was 45 microvessels. Low MVD (microvessels ≤ 45) was observed in 41 patients (48.8%), and high MVD (>45) was found in 43 (51.2%). The presence of conspicuous lymphocytic infiltration was significantly associated with increased vessel density. With uni- and multivariate survival analysis MVD did not show any prognostic significance. The character of the invasive margin was the only parameter with independent prognostic value.

Conclusions: MVD does not seem to provide any additional prognostic information when compared with standard histopathological parameters in lymph node–negative rectal cancer. It is likely that the strong association between MVD and the presence of conspicuous lymphocytic infiltration may interfere with its predictive value.

Key Words: Rectal cancer—Angiogenesis—Lymphocytic infiltration—Prognosis.

Experimental evidence has shown that neoangiogenesis is essential for the growth of solid tumors.^{1,2} It has also been demonstrated that tumor angiogenesis is a complex process that depends on the activity of several angiogenic promoters, such as vascular endothelial growth factor,³ basic fibroblast growth factor,⁴ and platelet-derived endothelial cell growth factor (PD-ECGF).⁵ It has been suggested that intratumoral microvessel density (MVD) could be used as an indirect parameter of the prognostic value of angiogenesis: an increase in the number of tumor vessels is believed to increase the

possibility of tumor cells entering the blood flow, thus causing metastasis in distant organs.^{6–8} A relationship between high MVD and increased risk of tumor recurrence and metastasis has been reported in breast cancer,^{9,10} non-small-cell lung carcinoma,¹¹ and melanoma.¹² The results of a number of investigations on colorectal cancer have shown that there is a strong correlation between high MVD and the presence of lymph node or distant metastases.^{13–16} Very few studies have addressed the issue of the predictive value of MVD in lymph node–negative (LNN) colorectal cancer: the results have not been conclusive.^{17–19} To our knowledge, the possible prognostic role of MVD in LNN rectal cancer has not been reported.

The aim of this retrospective study was to analyze the value of microvessel count in predicting the clinical outcome of T2/T3N0M0 (American Joint Committee on Cancer [AJCC]/International Union Against Cancer [UICC] stage I and II, Dukes A and B) rectal cancer

Received May 7, 2001; accepted September 7, 2001.

From the Departments of General Surgery (FC, GP, PB, AT, FP, CC), Human Pathology and Oncology (AP, LM, GA), and Experimental Pathology and Oncology (VB), University of Florence, Florence, Italy.

Address correspondence and reprint requests to: Fabio Cianchi, MD, Sez. Clinica Chirurgica e Terapia Chirurgica, Dipartimento di Area Critica Medica e Chirurgica, Viale Morgagni 85, 50134 Firenze, Italy; Fax: 3955-4220133; E-mail: cianchif@mail.unifi.it.

patients. We compared the quantitative assessment of angiogenesis with other well-known histopathological parameters to determine whether MVD provides any additional prognostic information.

METHODS

Patients

Between 1989 and 1996, 170 consecutive patients underwent radical surgical resection of rectal tumors (located no farther than 15 cm from the anal verge) at the Department of General Surgery, University of Florence (Italy). Eighty-four patients were included in the study: 60 (71.4%) were men, and 24 (28.6%) were women (median age, 65 years; range, 37–83 years). All subjects had tumors classified as T2 and T3 without lymph node or distant metastases (AJCC/UICC stage I and II, Dukes A and B). A retrospective study was performed on the clinical outcome of these patients. All surviving patients had been thoroughly informed about the study and gave written consent for the investigation in accordance with the ethical guidelines of our university. All patients were operated on by the same surgeon (C.C.). This most likely eliminated any surgeon-related prognostic factors that could have interfered with survival analysis.²⁰ Operations were defined as radical when there had been no evidence of distant metastases or incomplete macroscopic clearance of the tumor and the pathologist reported tumor-free margins of the specimen. Complete circumferential excision of the mesorectum was performed in all patients with extraperitoneal carcinoma (middle and lower rectum); a distal clearance of at least 2 cm of healthy mucosa from the lower edge of the tumor was provided in all the patients who had undergone sphincter-saving operations. No patient received pre- or postoperative radiotherapy or chemotherapy. The median duration of follow-up for surviving patients was 67 months (range, 50–110 months).

Histopathological Staging

All surgical specimens were fixed in 10% formalin solution and routinely processed for paraffin embedding. We evaluated the following histopathological parameters for each tumor specimen: tumor type, classified into adenocarcinoma and mucinous carcinoma when more than 50% of the tumor volume was composed of mucin; tumor differentiation, classified as well differentiated, moderately differentiated, and poorly differentiated, according to the World Health Organization criteria²¹; the depth of invasion of the tumors, classified as T2 (invasion of the muscularis propria) or T3 (invasion into the subserosa or into nonperitonealized perirectal tissues

through the muscularis propria) according to the AJCC/UICC cancer staging system²²; extramural venous invasion, assessed according to the method described by Talbot et al.²³; the character of the invasive margin (expanding or infiltrating) and lymphocytic infiltration (conspicuous or little/absent), assessed according to criteria defined by Jass et al.²⁴ The median number of lymph nodes recovered and examined in the surgical specimens was 12 (range, 2–42).

Microvessel Immunohistochemical Staining

A monoclonal antibody against the endothelial antigen CD31 was used to stain the microvessels. Four-micrometer-thick sections were cut from formalin-fixed and paraffin-embedded tumor tissue blocks. They were mounted on poly-L-lysine-coated slides, dewaxed in xylene, and rehydrated through a graded series of ethanol. After deparaffinization, the sections were treated with 3% hydrogen peroxide in methanol solution for 20 minutes to block endogenous peroxidase activity. Sections were pretreated with protease type XIV (Sigma Chemical Co., St Louis, MO) in phosphate-buffered saline for 7 minutes at 37°C and then at 4°C for 5 minutes to quench enzymatic digestion. After incubating with normal rabbit serum for 5 minutes at room temperature, the slides were incubated with CD31 monoclonal antibody (JC 70™; Dako, Milano, Italy), diluted 1/10, for 30 minutes at room temperature: this was followed by three washes with phosphate-buffered saline. The streptavidin-biotin method was used, with diaminobenzidine tetrahydrochloride as the chromogen. Sections were rinsed in deionized water, counterstained with Mayer's hematoxylin, and then dehydrated and mounted with Permount™ (Fisher Scientific, Fair Lawn, NJ). For negative controls, we used a nonspecific immunoglobulin G (normal rabbit immunoglobulin G) instead of primary antibody.

Microvessel Counting

One section per tumor was analyzed. MVD was evaluated by the same pathologist (A.P.) and reviewed by one observer (L.M.). Neither pathologist had any knowledge of the clinical outcome. The entire tumor section was first carefully scanned at low magnification ($\times 100$) to find the areas that showed the most intense neovascularization (hot spots). These hot spots were identified as areas with the highest density of brown stained CD31⁺ cells. The microvessels that were included in the MVD counts were only those that had been in the stroma surrounded by malignant glands; the microvessels that had been found within areas of granulation tissue, such those near the surface of ulcerated tumors, were excluded from MVD counts. Individual microvessels in the hot

spots were then counted in a single $\times 250$ field. Any immunoreactive endothelial cell or endothelial cell cluster that was clearly separated from the adjacent microvessels was considered as a single countable vessel. No vessel lumens or red blood cells were used to define a microvessel. The occasionally found immunoreactive lymphocytes, macrophages, and plasma cells were excluded on the basis of the staining pattern and cell morphology. MVD in each tumor was expressed as the microvessel count of the hot spot with the highest number of microvessels according to the methods proposed by Weidner.¹⁰

Statistical Analysis

Correlation between the microvessel count in the hot spot with the highest MVD and the microvessel count in the hot spot with the second highest MVD within the same tumor section was analyzed with Spearman's rank test. The relationships between MVD and the other clinicopathological variables were examined with the χ^2 test. The relationship between clinicopathological variables and survival was estimated with the Kaplan-Meier method.²⁵ The Cox proportional hazards regression model²⁶ was used to identify those clinicopathological factors that independently influenced survival. For all the analyses, Stata Statistical Software™ release 6.0 (Stata Corp., College Station, TX) was used. A *P* value of .05 or less was considered significant.

RESULTS

Patient Outcome and Clinicopathological Variables

Thirty-five (41.7%) of the 84 patients had T2 tumors, and 49 (58.3%) had T3 tumors. Seventy-eight tumors (92.9%) were classified as adenocarcinomas and six (7.1%) as mucinous carcinomas. Seventeen adenocarcinomas (21.8%) were well differentiated, and 61 (78.2%) were moderately differentiated. No tumor was classified as poorly differentiated. Tumor invasion of the extramural veins was present in 14 (16.7%) patients; it was absent in 70 (83.3%). Forty-six (54.8%) tumors were classified as having an expanding invasive margin and 38 (45.2%) as having an infiltrating one. Lymphocytic infiltration was conspicuous in 16 patients (19.0%); it was little or absent in 68 (81.0%).

In each tumor section, the microvessel count of the hot spot with the highest MVD significantly correlated with the microvessel count of the hot spot with second highest vessel density ($r = .74$, $P < .0001$; Fig. 1). The median MVD of all the patients was 45 (range, 18–153). This cutoff was used to identify two groups of patients. Low MVD (≤ 45) was found in 41 patients (48.8%), and high

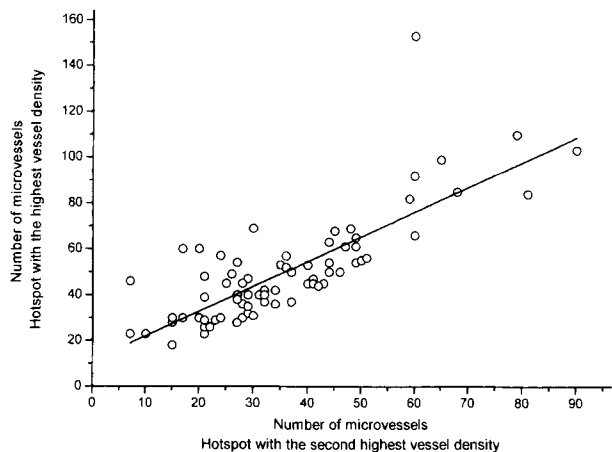


FIG. 1. Microvessel counts in all 84 sections stained for CD31: microvessel counts of vascular hot spots with the highest microvessel density (MVD) correlated significantly with microvessel counts of vascular hot spots with the second highest MVD ($r = .74$; $P < .0001$)

MVD (>45) was found in 43 (51.2%) patients. Figure 2A and B shows representative cases with low and high MVD, respectively. A highly significant association was

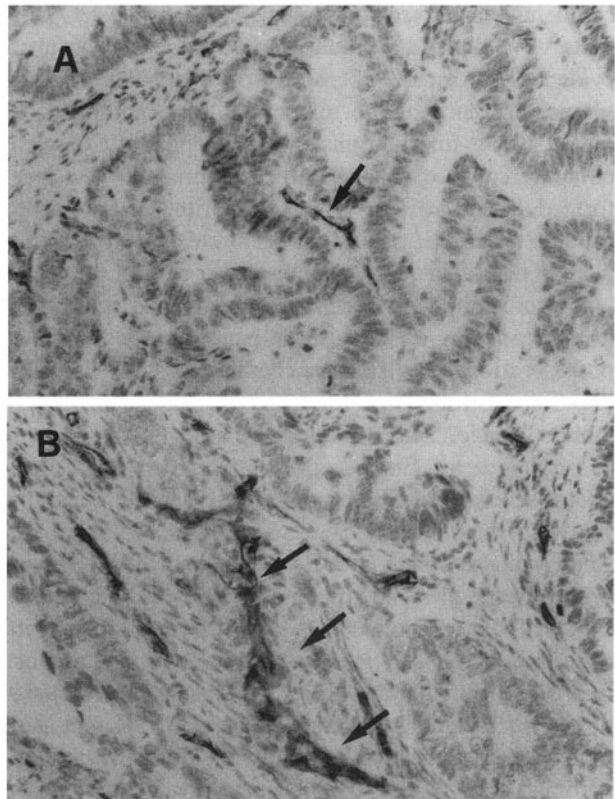


FIG. 2. CD31 immunostaining. Representative cases of tumor specimens with a low vascular hot spot (arrow) (A) and a high vascular hot spot (arrows) (B) ($\times 250$).

found between tumors with high MVD and those with conspicuous lymphocytic infiltration ($P = .001$; Table 1). Figure 3 shows a representative tumor sample with conspicuous lymphocytic infiltration and high MVD. No significant association was found between MVD and the other clinicopathological features.

Prognosis

Sixty-five of the 84 patients were alive at the time of the last follow-up: none showed any evidence of the disease. Nineteen patients had died of disease relapse. Nine patients (10.7%) had distant metastases, six patients (7.1%) had local recurrence, and four patients (4.7%) had both distant metastases and local recurrence. The overall rate of tumor relapse in our study was comparable to that reported by other authors who did not perform pre- or postoperative adjuvant therapy.²⁷⁻²⁹ In univariate analysis, the depth of local invasion and the character of the invasive margin were significantly related to survival (Table 2). The 5-year survival rate of patients with T2 (Dukes A) tumors was 89.8%; it was 63.3% for those patients with T3 tumors (Dukes B; $P = .01$). When

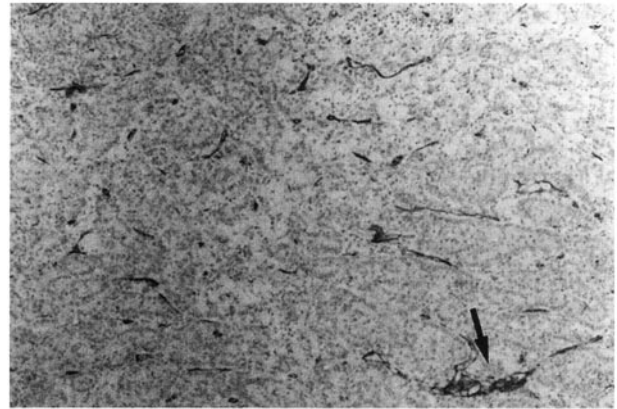


FIG. 3. CD31 immunostaining. Representative case of tumor specimen with conspicuous tumoral lymphocytic infiltration and a high vascular hot spot (arrow) ($\times 100$).

TABLE 1. Relationships between clinicopathological variables and microvessel density (MVD) in 84 patients with lymph node-negative rectal cancer

Variable	MVD		P value
	Low (≤ 45) n (%)	High (> 45) n (%)	
Age (y)			
≤ 65	21 (47.7)	23 (52.3)	
> 65	20 (50.0)	20 (50.0)	.83
Sex			
Male	32 (45.3)	28 (46.7)	
Female	9 (37.5)	15 (62.5)	.18
Histotype			
Mucinous	2 (33.3)	4 (66.7)	
Adenocarcinoma	39 (50.0)	39 (50.0)	.43
Tumor differentiation			
Well differentiated	7 (41.2)	10 (58.8)	
Moderately differentiated	32 (52.5)	29 (47.5)	.41
Poorly differentiated	0	0	
Depth of invasion			
T2	16 (45.7)	19 (54.3)	
T3	25 (51.0)	24 (48.9)	.63
Venous invasion			
Absent	33 (47.1)	37 (52.9)	
Present	8 (57.1)	6 (42.9)	.49
Character of invasive margin			
Expanding	20 (43.5)	26 (56.5)	
Infiltrating	21 (55.3)	17 (44.7)	.28
Conspicuous lymphocytic infiltration			
Present	2 (12.5)	14 (87.5)	
Absent	39 (57.4)	29 (42.6)	.001
Tumor relapse			
Absent	30 (46.2)	35 (53.8)	
Present	11 (57.9)	8 (42.1)	.36

survival was compared with the character of the invasive margin, the patients with expanding tumors had an 89.9% 5-year survival rate, whereas patients with infiltrating tumors had a 57.0% 5-year survival rate ($P = .001$). No significant association was found between MVD and survival. The prognostic value of MVD and the other clinicopathological variables was also examined by multivariate analysis with the Cox proportional

TABLE 2. Association of clinicopathological factors with 5-y survival in 84 patients with lymph node-negative rectal cancer

Variable	n (%)	5-y Survival (%)	P value
Age (y)			
≤ 65	44 (52.4)	84.0	
> 65	40 (47.6)	66.0	.07
Sex			
Male	60 (71.4)	73.6	
Female	24 (28.6)	82.3	.45
Histotype			
Mucinous	6 (7.1)	80.7	
Adenocarcinoma	78 (92.9)	75.6	.87
Tumor differentiation			
Well differentiated	17 (21.8)	82.3	
Moderately differentiated	61 (78.2)	73.8	.44
Depth of invasion			
T2	35 (41.7)	91.2	
T3	49 (58.3)	64.9	.01
Venous invasion			
Absent	70 (83.3)	77.7	
Present	14 (16.7)	67.1	.49
Character of invasive margin			
Expanding	46 (54.8)	90.8	
Infiltrating	38 (45.2)	58.5	.001
Conspicuous lymphocytic infiltration			
Present	16 (19.0)	80.7	
Absent	68 (81.0)	74.7	.60
Microvessel density			
≤ 45	41 (48.8)	70.7	
> 45	43 (51.2)	80.8	.20

hazards model. Only the character of the invasive margin emerged as an independent prognostic factor (Table 3).

DISCUSSION

The relationship between quantitative assessment of angiogenesis, assessed as MVD, and prognosis has been studied in many types of tumors, including colorectal cancer.¹³⁻¹⁶ Most of these studies have shown that a high density of microvessels is associated with short-term survival and thus can be considered a marker of tumor aggressiveness.

The need for new prognostic factors is particularly urgent for LNN colorectal cancer patients. In fact, this group of patients is still a broad category with respect to clinical outcome. It is of critical importance that additional prognostic information be available to better identify those patients who are likely to experience tumor relapse. As a consequence, they could receive the most benefit from adjuvant therapy. There is as yet no consensus regarding the prognostic value of MVD in early-stage colorectal cancer. In two published studies on LNN colon cancer,^{17,18} prognosis was significantly better in the low-MVD patient groups than in those with high MVD. These results were not confirmed when tumors of the colon and of the rectum were analyzed together. Banner et al.¹⁹ reported contrasting results: microvessel counts in stage II colorectal cancer subjects were higher in their long-term survival patient group than in their short-term one. To our knowledge, this study is the first to address the question of the prognostic importance of angiogenesis in LNN rectal cancer. The purpose of this study was to evaluate whether the predictive value of MVD could compete successfully with the prognostic importance of the well-known histopathological parameters in rectal cancer, such those used in the Dukes and Jass colorectal cancer staging classifications. We found that both the depth of local invasion and the character of the invasive margin were significant predictors of sur-

vival in univariate analysis. However, only the character of the invasive margin emerged as an independent prognostic factor from multivariate analysis. Tumor type and differentiation, venous invasion, lymphocytic infiltration, and MVD failed to show any relevance in predicting survival.

We found a significant correlation between the degree of lymphocytic infiltration and MVD: tumors with conspicuous lymphocytic infiltration were more frequent in the high-MVD group than in the low-MVD one. Our data are consistent with findings reported by Giatromanolaki et al.³⁰ They found a striking association between CD31⁺ lymphocyte infiltration and high vascular density. Moreover, they did not find any correlation between microvessel count and prognosis in their Dukes B patients. A similar association was reported in patients with non-small-cell lung carcinoma³¹ and in those with renal tumors.³² These findings are not surprising. A number of recent studies have demonstrated that the inflammatory cell infiltrate significantly contributes to the angiogenic process in malignant disease.³³⁻³⁵ As regards colorectal cancer, it has been demonstrated that PD-ECGF is mainly expressed by tumor-infiltrating macrophages and lymphocytes. Thus, PD-ECGF is considered one of the most important promoters of the angiogenic pathway associated with the immune response against cancer.^{36,37}

All these data, when taken together, may provide an explanation for our results. Jass³⁸ has demonstrated that conspicuous lymphocytic infiltration is more frequently associated with early-stage rectal tumors than with those with lymph node or distant metastases. This infiltration has been considered the expression of an effective cell-mediated immune response against the tumor. The activity of the immune cells has also been associated with the production of angiogenic promoters and, thus, with stimulation of tumor vascularity.³³⁻³⁷ As a consequence, the favorable prognostic effect of the host immunological reaction to invading rectal carcinoma, i.e., the presence of conspicuous lymphocytic infiltration, might interfere

TABLE 3. Survival analysis using multivariate Cox proportional hazards regression model

Prognostic factors	Hazard ratio	95% Confidence interval	P value
Age (>65 y vs. ≤65 y)	1.94	0.714-5.319	.193
Sex (male vs. female)	1.45	0.443-4.750	.538
Histology (mucinous vs. adenocarcinoma)	.94	0.114-7.853	.960
Differentiation (moderately vs. well)	1.11	0.302-4.084	.784
Depth of invasion (T3 vs. T2)	1.72	0.366-8.153	.489
Invasive margin (infiltrating vs. expanding)	5.39	1.245-23.345	.024
Lymphocytic infiltration (absent vs. present)	1.40	0.359-5.474	.626
Venous invasion (present vs. absent)	.78	0.233-2.632	.693
MVD (low vs. high)	.89	0.301-2.633	.834

MVD, microvessel density.

with the negative effect of a large vascular surface area within the tumor. The result would be a lack of any significant prognostic significance regarding either MVD or the degree of lymphocytic infiltration. This hypothesis may explain our results in LNN rectal cancer patients.

Failure of capacity of the degree of lymphocytic infiltration to be a significant prognostic factor has been the experience of other investigators.³⁹⁻⁴¹ This finding has been explained by poor interobserver and intraobserver reproducibility as regards this histopathological parameter. However, none of the studies mentioned³⁹⁻⁴¹ ever noted or even suggested that there could be any association between the immune response and the promotion of the angiogenic process as an explanation for their results.

Another hypothesis that may explain our findings was put forth by Giatromanolaki et al.³⁰ They suggested the presence of specific angiogenic profiles that may differ substantially with regard to tumor relapse; i.e., the angiogenic pathway associated with the immune response may not be associated with aggressive tumor behavior. This hypothesis has been given further support by recently reported data on a significant association between the expression of PD-ECGF and a good prognosis in colorectal cancer.³⁷

It has been suggested⁴² that the discrepancy in results regarding the prognostic value of microvessel count might be related to some differences in methodology. The choice of the endothelial antibodies for immunohistochemical staining and the selection of the area for microvessel quantification have been among the variables cited. In our study, a monoclonal antibody against CD31 was used to highlight the endothelial cells, and the microvessels were counted in the areas that showed the highest degree of vessel density (hot spots), as suggested by a recent international consensus on the methodology and criteria of angiogenesis quantification.⁴² Another issue that should be addressed is the possible heterogeneity of tumor vascularity within each histopathological section. We found that the microvessel count of the hot spot with the highest MVD significantly correlated with the microvessel count of the hot spot with the second highest MVD. This finding supports the hypothesis that the degree of vascularization in different hot spots may be similar within the same colorectal tumor section and thus might represent a biological feature of a single tumor, as previously suggested by Vermeulen et al.⁴³

In conclusion, MVD does not seem to provide any additional prognostic information when compared with standard histopathological variables in patients with LNN rectal cancer. The frequent presence of conspicuous lymphocytic infiltration in early-stage rectal cancer

and the effective role of the immune cells in promoting the angiogenic process may interfere with the effectiveness of MVD in predicting the clinical outcome in this group of patients.

REFERENCES

1. Folkman J. What is the evidence that tumors are angiogenesis dependent? *J Natl Cancer Inst* 1990;82:4-6.
2. Folkman J, Watson K, Ingber D, Hanahan D. Induction of angiogenesis during the transition from hyperplasia to neoplasia. *Nature* 1989;338:58-61.
3. Ferrara N, Houck K, Jakeman L, Leung DW. Molecular and biological properties of vascular endothelial growth factor family of proteins. *Endocr Rev* 1992;13:18-32.
4. Basilico C, Moscatelli D. The FGF family of growth factors and oncogenes. *Adv Cancer Res* 1992;59:115-65.
5. Ishikawa F, Miyazono K, Hellman U, et al. Identification of angiogenic activity and the cloning and expression of platelet-derived endothelial cell growth factor. *Nature* 1989;338:557-62.
6. Bikfalvi A. Significance of angiogenesis in tumor progression and metastasis. *Eur J Cancer* 1995;31A:1101-4.
7. Blood CH, Zetter BR. Tumor interaction with the vasculature: angiogenesis and tumor metastases. *Biochim Biophys Acta* 1990;1032:89-118.
8. Folkman J. Angiogenesis and breast cancer. *J Clin Oncol* 1994;12:441-4.
9. Bosari S, Lee AKC, DeLellis RA, Wiley BD, Heatley GJ, Silverman ML. Microvessel quantitation and prognosis in invasive breast carcinoma. *Hum Pathol* 1992;23:755-61.
10. Weidner N, Semple JP, Welch WR, Folkman J. Tumor angiogenesis and metastasis: correlation in invasive breast carcinoma. *N Engl J Med* 1991;324:1-8.
11. Macchiarini P, Fontanini G, Hardin MJ, Squartini F, Angeletti CA. Relation of neovascularization to metastases in non-small-cell lung cancer. *Lancet* 1992;340:145-6.
12. Srivastava A, Laidler P, Davies RP, Horgan K, Hughes LE. The prognostic significance of tumor vascularity in intermediate-thickness (0.76-4.00 mm thick) skin melanoma. *Am J Pathol* 1988;133:419-23.
13. Tomisaki S, Ohno S, Ichiyoshi Y, Kuwano H, Maehara Y, Sugimachi K. Microvessel quantification and its possible relation with liver metastasis in colorectal cancer. *Cancer* 1996;77:1722-8.
14. Saclarides TJ, Speziale NJ, Drab E, Szeluga DJ, Rubin DB. Tumor angiogenesis and rectal carcinoma. *Dis Colon Rectum* 1994;37:921-6.
15. Takebayashi Y, Akiyama S, Yamada K, Akiba S, Aikou T. Angiogenesis as an unfavorable prognostic factor in human colorectal carcinoma. *Cancer* 1996;78:226-31.
16. Tanigawa N, Amaya H, Matsumura M, et al. Tumor angiogenesis and mode of metastasis in patients with colorectal cancer. *Cancer Res* 1997;57:1043-6.
17. Frank RE, Saclarides TJ, Leurgans S, Speziale NJ, Drab EA, Rubin DB. Tumor angiogenesis as a predictor of recurrence and survival in patients with node-negative colon cancer. *Ann Surg* 1995;222:695-9.
18. Takahashi Y, Tucker SL, Kitadai Y, et al. Vessel counts and expression of vascular endothelial growth factor as prognostic factors in node-negative colon cancer. *Arch Surg* 1997;132:541-6.
19. Banner BF, Whitehouse R, Baker SP, Swanson RS. Tumor angiogenesis in stage II colorectal carcinoma. Association with survival. *Am J Clin Pathol* 1998;109:733-7.
20. Hermanek P. Impact of surgeon's technique on outcome after treatment of rectal carcinoma. *Dis Colon Rectum* 1999;42:559-62.
21. Jass JR, Sobin LH. Histological typing of intestinal tumors. In: Jass JR, Sobin LH, eds. *WHO International Histological Classification of Tumors*. 2nd ed. Berlin: Springer-Verlag, 1989.

22. American Joint Committee on Cancer. *AJCC Cancer Staging Manual*. 5th ed. Philadelphia: Lippincott-Raven, 1997.
23. Talbot IC, Ritchie S, Leighton MH, Hughes AO, Bussey HJ, Morson BC. Spread of rectal cancer within veins: histologic features and clinical significance. *Am J Surg* 1981;141:15-7.
24. Jass JR, Love S, Northover JM. A new prognostic classification for rectal cancer. *Lancet* 1987;1:1303-6.
25. Kaplan E, Meier P. Non parametric estimation from incomplete observations. *J Am Stat Assoc* 1958;53:457-81.
26. Cox DR. Regression model and life tables. *J R Stat Soc B* 1972; 34:187-220.
27. Swedish Rectal Cancer Trial. Improved survival with preoperative radiotherapy in resectable rectal cancer. *N Engl J Med* 1997;336: 980-7.
28. Zaheer S, Pemberton JH, Farouk R, Dozois RR, Wolff BG, Ilstrup D. Surgical treatment of adenocarcinoma of the rectum. *Ann Surg* 1998;227:800-11.
29. Dahlberg M, Glimelius B, Pahlman L. Improved survival and reduction in local failure rates after preoperative radiotherapy. Evidence for the generalizability of the results of Swedish Rectal Cancer Trial. *Ann Surg* 1999;229:493-7.
30. Giatromanolaki A, Stathopoulos GP, Tsiobanou E, et al. Combined role of tumor angiogenesis, bcl-2, and p53 expression in the prognosis of patients with colorectal carcinoma. *Cancer* 1999;86: 1421-30.
31. Giatromanolaki A, Koukourakis M, Theodossiou D, Barbatis C, Harris AL, Gatter KC. Comparative evaluation of angiogenesis assessment with anti-factor-VIII and anti-CD31 immunostaining in non-small cell lung cancer. *Clin Cancer Res* 1997;179:80-8.
32. Anastassiou G, Duensing S, Steinhoff G, et al. Platelet endothelial cell adhesion molecule-1 (PECAM-1): a potential prognostic marker involved in leukocyte infiltration of renal cell carcinoma. *Oncology* 1996;53:127-32.
33. O'Byrne KJ, Dalglish AG, Browning MJ, Steward WP, Harris AL. The relationship between angiogenesis and the immune response in carcinogenesis and the progression of malignant disease. *Eur J Cancer* 2000;36:151-69.
34. Giatromanolaki A, Koukourakis MI, Kakolyris S, et al. Focal expression of thymidine phosphorylase associates with CD31 positive lymphocytic aggregation and local neo-angiogenesis in non-small cell lung cancer. *Anticancer Res* 1998;18:71-6.
35. Leek RD, Landers RJ, Harris AL, Lewis CE. Necrosis correlates with high vascular density and focal macrophage infiltration in invasive carcinoma of the breast. *Br J Cancer* 1999;79:991-5.
36. Takahashi Y, Bucana CD, Liu W, et al. Platelet-derived endothelial cell growth factor in human colon cancer angiogenesis: role of infiltrating cells. *J Natl Cancer Inst* 1996;88:1146-51.
37. Saito S, Tsuno N, Nagawa H, et al. Expression of platelet-derived endothelial cell growth factor correlates with good prognosis in patients with colorectal carcinoma. *Cancer* 2000;88:42-9.
38. Jass JR. Lymphocytic infiltration and survival in rectal cancer. *J Clin Pathol* 1986;39:585-9.
39. Fisher ER, Robinsky B, Sass R, Fisher B. Relative prognostic value of the Dukes and the Jass systems in rectal cancer: findings from the National Surgical Adjuvant Breast and Bowel Projects (Protocol R-01). *Dis Colon Rectum* 1989;32:944-9.
40. Dundas SA, Laing RW, O' Cathain A, et al. Feasibility of new prognostic classification for rectal cancer. *J Clin Pathol* 1988;41: 1273-6.
41. Secco GB, Fardelli R, Campora E, et al. Prognostic value of the Jass histopathological classification in left colon and rectal cancer: a multivariate analysis. *Digestion* 1990;47:71-80.
42. Vermeulen PB, Gasparini G, Fox SB, et al. Quantification of angiogenesis in solid human tumors: an international consensus on the methodology and criteria of evaluation. *Eur J Cancer* 1996; 32A:2474-84.
43. Vermeulen PB, Verhoeven D, Fierens H, et al. Microvessel quantification in primary colorectal carcinoma: an immunohistochemical study. *Br J Cancer* 1995;71:340-3.