



Original article

Percutaneous ultrasound-guided fiducial marker placement for liver cancer robotic stereotactic radio-surgery treatment: A comparative analysis of three types of markers and needles



Marsico Maria ^{a,*}, Gabbani Tommaso ^b, Lunardi Sarah ^c, Galli Andrea ^d, Biagini Maria Rosa ^d, Annese Vito ^e

^a Gastroenterology UO, Bellaria-Maggiore Hospital, Bologna, Italy

^b Gastroenterology Unit, Morgagni-Pierantoni Hospital, AUSL Romagna, Forlì, Italy

^c Division of Internal Medicine 4, AOU Careggi University Hospital, Florence, Italy

^d Clinical Gastroenterology Unit, AOU Careggi University Hospital, Florence, Italy

^e Department of Gastroenterology, Valiant Clinic, Dubai, United Arab Emirates

ARTICLE INFO

Article history:

Received 6 October 2016

Accepted 7 May 2017

Keywords:

Stereotactic body radiation therapy

Fiducial markers

Liver neoplastic lesions

Ultrasound-guided percutaneous placement

Gold anchor marker

ABSTRACT

Background and study aims: Percutaneous placement of fiducial markers is required to perform stereotactic body radiation therapy (SBRT) for liver neoplastic lesions. This prospective trial was designed to evaluate the feasibility and safety of percutaneous ultrasound-guided placement of three different types of markers in patients with liver cancer referred for SBRT.

Patients and methods: Fifty patients underwent percutaneous ultrasound-guided implantation of a fiducial marker in the liver. Three sizes of needles were used: 25 gauge (G), 22 G, and 17 G. The 25 G and 22 G needles contained gold anchor markers of 0.28×10 mm and 0.4×10 mm size, respectively. In contrast, the 17 G needle contained a gold grain marker of 1×4 mm. Each patient received 1–6 markers, depending on lesion size and numbers. Technical feasibility and the occurrence of adverse events were registered. Computed tomography scans were acquired prior to SBRT to evaluate the location, visibility, or complications related to the markers.

Results: A total of 163 needles were used to deliver 163 markers in 50 patients. No major complications occurred. Minor complication occurrence rate was 12%. The total complication occurrence for all type of markers was 8.5%. No complications were observed with the use of the gold anchor marker of 0.4×10 mm size. Variance analysis of the three markers showed a significant difference in the frequency of complications amongst the three markers ($p < 0.01$).

Conclusion: Percutaneous ultrasound-guided placement of fiducial markers for SBRT of liver neoplastic lesions is safe and feasible. In our series, the 22 G needle showed some advantage in terms of handling and safety when compared with the 25 G and 17 G needles. In addition, the gold anchor marker of 0.4×10 mm size displayed a lower percentage of displacement.

© 2017 Pan-Arab Association of Gastroenterology. Published by Elsevier B.V. All rights reserved.

Introduction

Surgery is the current standard treatment for localised operable neoplastic lesions of the liver [1]; however, many patients cannot afford surgical resection because of comorbidities, advanced age, disease extension, or patients' wishes. Treatment strategies for liver cancer have evolved over the last many years. Stereotactic body radiation therapy (SBRT) using the Cyberknife system is a non-surgical option for patients with inoperable or surgically complex tumours. In addition, it is an option in the case of absent

response and/or relapse after chemotherapy and standard radiotherapy [2]. SBRT administers high doses of radiations that can reach any anatomic point with a sub-millimetric precision [3,4]. This high accuracy is achieved through a robotic image-guidance system technology and dynamic tracking of targets, with the removal of breathing artifacts. Through these techniques, the CyberKnife system can precisely hit the lesion with high doses of radiations whilst safeguarding the surrounding critical organs, which otherwise could be damaged [5,6]. Robotic radiosurgery can employ different systems for the localisation of the neoplastic targets for treatment. In particular, for the treatment of the solid organ tumours, CyberKnife uses a localisation system that is based on specific gold markers [7]. The placement of a fiducial marker

* Corresponding author.

E-mail address: ma.marsico@libero.it (M. Marsico).

near the tumour before radiotherapy also allows respiratory motion to be tracked, thus enabling accurate dose delivery whilst the patient breathes freely [8]. Recently, the percutaneous insertion of fiducial markers has been described [9,10], but experience with such procedures is limited. The marker is made of gold, which makes it biocompatible and ensures good contrast on X-ray images.

The aim of the trial was to evaluate and compare the feasibility and technical benefits of percutaneous ultrasound (US)-guided placement of three different types of gold markers in patients with liver cancer referred for SBRT. We also evaluated the handling and safety of the three needles of different calibers that were used for fiducial deployment.

Patients and methods

This was a prospective, single-centre feasibility and comparative study conducted in a tertiary-care medical centre. Eighty patients affected by neoplastic disease with an indication for stereotactic radiotherapy were assessed. Thirty of them were excluded because they were affected by a primitive neoplasia of the pancreas in absence of liver lesion. Fifty patients affected by neoplastic liver lesions underwent percutaneous fiducial marker placement under US guidance. Written informed consent was obtained from all patients. All procedures were performed by two expert ultrasonographers using the ProSound Alfa7 (Hitachi-Aloka, Tokyo, Japan) equipment with a 3.75–7.5-MHz hemispheric sound technology 91–30 Multi Frequency Convex Abdominal probe. Local anaesthesia was achieved by the subcutaneous administration of 1% lidocaine. All gold fiducial markers were placed under US guidance through sub- or intercostal access. When the needle tip had reached the target lesion, the fiducial marker was deployed and the needle removed. We used three different types of needles: 25 gauge (G), 22 G, and 17 G. The 25 G needle contained 0.28×10 mm gold anchor marker, the 22 G needle contained 0.4×10 mm gold anchor marker, and the 17 G needle contained the 1×4 mm gold grain marker (Figs. 1 and 2). Every patient

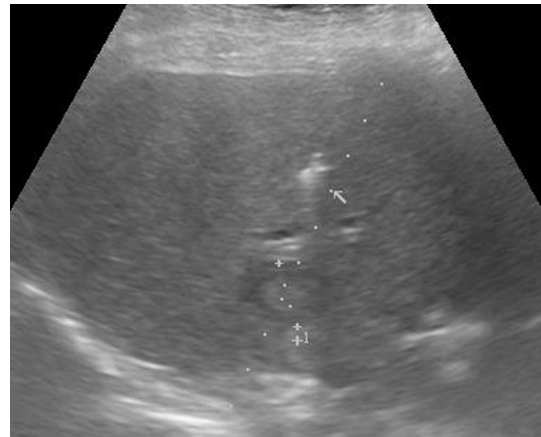


Fig. 3. Hyperechoic flexible-wire notched gold anchor marker (arrow) near a liver metastasis.

received 1 to 6 fiducial markers depending on the dimension and the number and location of the liver lesions. The fiducial positioning was assessed under US guidance as the marker is easily detected as a hyperechoic structure (Fig. 3). Seven days after the procedure, a computed tomography (CT) to identify marker location or possible complications was performed for all patients. Subsequently, two months after the SBRT treatment, another CT scan was performed to evaluate the response to radiotherapy. Technical success was defined as the successful placement of fiducial markers at the intended site. Clinical success was defined as the possibility to implement an adequate treatment plan with the markers retained at the correct position without migration. The following complications were evaluated: marker migration, marker shattering, marker not massed, presence of pneumothorax and/or bleeding, and death. Fiducial migration was defined as seed dislodgement outside the original injection site, making it unusable for guiding SBRT, as determined by CT scan (Fig. 4). All data




Fig. 1. Gold anchor marker 0.4×10 mm before (A) and after massing (B).




Fig. 2. 22-Gauge fine needle.

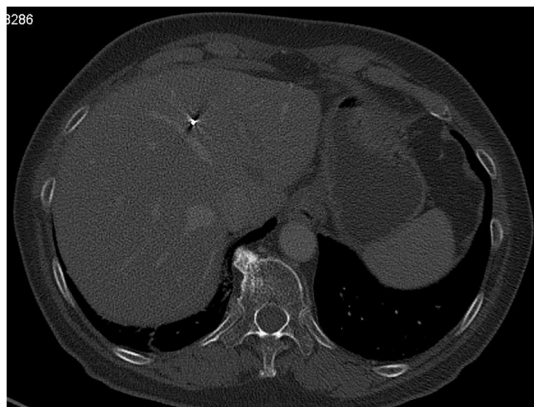


Fig. 4. SBRT planning with CT for the simulation of radiation treatment was performed on all patients to check for marker position and late complications. In the figure: flexible-wire notched gold anchor marker 0.4×10 mm (arrow).

were analysed with the use of appropriate parametric and non-parametric statistical tests such as two-tailed Student *t*-test, considering a *p*-value of <0.05 significant, and one-factor analysis of variance (ANOVA).

Results

Fifty patients (29 men, mean age 63.5 years, range 37–87 years) who underwent percutaneous US-guided fiducial marker implantation for CyberKnife therapy for liver cancer were enrolled. In total, 84 liver lesions were evaluated: 6 were primary tumours and 78 were liver metastases. The mean tumour size was 48 mm (range 11–150 mm) (Table 1). A total of 163 needles were used, and 163 gold markers were correctly deployed. Sixty-eight markers were gold grain type, 78 were gold anchor 0.4×10 mm, and the remaining 17 were gold anchor 0.28×10 mm. All fiducial placements were confirmed by US after the procedure. No major complications related to abdominal puncture occurred during the placement procedure. One vagal syndrome occurred when using the 22 G needle (2%), whilst 5 patients developed abdominal pain following the use of the 17 G needle (10%). No complications were reported with the use of the 25 G needle. Thus, the total percent of patients who experienced a minor complication was 12% (6/50).

Following the marker placement, all 50 patients underwent a simulation CT scan to evaluate the correct fiducial localisation and any onset of complications. In all the cases, SBRT was considered possible, and therefore, the clinical success rate was determined to be 100%. However, only 44 patients underwent SBRT as the therapy was not performed in 7 patients because of disease progression (5 patients) or death (2 patients). The presence of a shattered marker and/or marker not massed was observed in 10 patients with gold anchor markers 0.28×10 mm (25 G needle) (6%). In addition, intra- or extra-hepatic migration was observed with 4 gold grain markers 1×4 mm (17 G needle) (2.5%). In contrast, no dislocation was observed with the use of the gold anchor marker 0.4×10 mm (22 G needle). Thus, the total complication rate related to marker dislocation was 8.5% (14/163) (Table 2).

Table 1
Characteristics of patients.

Population characteristics							
Male	Female	Mean age (years)	Age range (years)	Primary liver tumours	Liver metastases	Mean lesions size (mm)	Size range of lesions (mm)
29	21	63.5	37–87	6	78	48	11–150

Table 2

Number and types of markers placed, needles used, and complications. (No.: number).

Type of markers	Type of needle	No. of complications	No. of Placed markers placed
Anchor marker 0.28×10 mm	25 gauge	10	17
	22 gauge	0	0
Anchor marker 0.4×10 mm	22 gauge	1	78
	17 gauge	4	0
Grain marker 1×4 mm	17 gauge	4	68
	25 gauge	5	0

One-factor ANOVA showed a significant difference in the frequency of complications with the three different markers ($p < 0.01$). More specifically, the gold grain marker showed a significantly greater number of complications than the other two types of markers ($p < 0.01$). Finally, amongst the two types of gold anchor markers, the 0.28×10 mm type resulted in more number of complications than the 0.4×10 mm type ($p < 0.05$).

Discussion

SBRT with Cyberknife machine is a new therapeutic option for tumours that cannot be treated with surgery. Moreover, it provides an alternative therapeutic option in the case of absent response and/or relapse after standard treatment [11–14]. The placement of gold fiducial markers near or inside the tumour is considered the best tool to improve the accuracy of radio-localisation. Percutaneous fiducial marker placement has been widely performed, but some complications have been reported [15]. In our series, the gold grain markers showed a higher migration rate than the gold anchor markers. In addition, the gold anchor marker has an advantage of greater flexibility and can curl up when pushed against the parenchyma owing to the spindle and being carried by the needle. Moreover, its coiled design possibly reduces the incidence of migration and dislocation. However, our results showed a higher incidence of complications with 0.28×10 mm gold anchor markers, probably because of the poor handling of the 25 G fine needle. In contrast, in our study, no signs of migration or other complication were observed with the use of the 0.4×10 mm gold anchor marker delivered using the 22 G needle. This needle is neither flexible nor as thin as the 25 G needle and therefore is more easily handled, resulting in a more precise and successful placement. Moreover, the 22 G needle, because of its small size, might reduce the complication rate related to abdominal puncture [16].

In conclusion, data in the literature are not concordant with regards to fiducial marker implantation technique for CyberKnife therapy. Percutaneous marker placement can be performed under CT, fluoroscopic, or US guidance, and there are many different types of gold fiducial markers of different sizes, lengths, and physical characteristics; therefore, the choice of the placement technique and type of fiducial markers is challenging. Moreover, the characteristics of liver lesions, the compliance, and clinical characteristics of the patients should be carefully evaluated to adopt the appropriate type of fiducial marker and needle for each patient [17–20]. In this hazy context, our study suggests that the gold anchor marker of 0.4×10 mm size should be preferred for US-

guided percutaneous insertion because of its ease of handling and stability. Moreover, the 22 G needle is optimal for good placement because of its adequate diameter, which leads to a reduced complication rate. Furthermore, in accordance with the existing literature, our study suggests that US-guided fiducial placement is safe and effective and might represent a valuable and reliable alternative to CT-guided placement [21–24]. However, our study has limitations such as being a single-centre experience, heterogeneity of the patient population, and the lack of a randomized design. A randomized prospective trial in a larger cohort is awaited to further evaluate the superiority of a specific marker over others and evaluate the cost-effectiveness of US- versus CT-guided placement.

Institutional review board statement and ethical committee approval

The study was reviewed and approved by the board of the Gastroenterology Unit. The study was approved by Gastroenterology Unit Ethical Committee. All patients provided written informed consent for enrolment in the study and inclusion of information in this article that could potentially lead to their identification.

Financial and competing interests' disclosure

This research did not receive any specific grant from funding agencies in the public, commercial, or not-for-profit sectors.

The authors have no relevant affiliations or financial involvement with any organisation or entity with a financial interest in or financial conflict with the subject matter or materials discussed in the manuscript. This includes employment, consultancies, honoraria, stock ownership or options, expert testimony, grants or patents received or pending, or royalties.

Ethical standards statement

All procedures followed were in accordance with the ethical standards of the committee responsible for human experimentation (institutional and national) and with the Helsinki Declaration of 1975, as revised in 2000. The authors have no relevant affiliations or financial involvement with any organisation or entity with a financial interest in or financial conflict with the subject matter or materials discussed in the manuscript. This includes employment, consultancies, honoraria, stock ownership or options, expert testimony, grants or patents received or pending, or royalties.

Data sharing statement and Open-Access

Technical appendix, statistical code, and dataset available from authors at ma.marsico@libero.it. Participants gave informed consent for data sharing; however, the data presented are anonymous and risk of identification is low.

Biostatistics statement

Statistical analysis was performed by Tommaso Gabbani MD, and reviewed by Principal Investigator Maria Marsico MD.

Conflict of interest

None.

References

- [1] Robertson DJ, Stukel TA, Gottlieb DJ, et al. Survival after hepatic resection of colorectal cancer metastases: a national experience. *Cancer* 2009;115:752–9.
- [2] Casamassima F, Cavedon C, Francescon P, Stancanello J, Avanzo M, Cora S, et al. Use of motion tracking in stereotactic body radiotherapy: evaluation of uncertainty in off-target dose distribution and optimization strategies. *Acta Oncol* 2006;45:943–7.
- [3] Kocher M, Wittig A, Piroth MD, Treuer H, Seegenschmiedt H, Ruge M, et al. Stereotactic radiosurgery for treatment of brain metastases: a report of the DEGRO Working group on stereotactic radiotherapy. *Strahlenther Onkol* 2014;190:521–32.
- [4] Kalogeridi MA, Zygogianni A, Kyrgias G, Kouvaris J, Chatziioannou S, Kelekis N, et al. Role of radiotherapy in the management of hepatocellular carcinoma: a systematic review. *World J Hepatol* 2015;7:101–12.
- [5] Collins BT, Vahdat S, Erickson K, Collins SP, Suy S, Yu X, et al. Radical cyberknife radiosurgery with tumor tracking: an effective treatment for inoperable small peripheral stage I non-small cell lung cancer. *J Hematol Oncol* 2009;17:1.
- [6] Kubo H-D, Hill B-C. Respiration gated radiotherapy treatment: a technical study. *Phys Med Biol* 1996;41:83–91.
- [7] Ohta Kengo, Shimohira Masashi, Murai Taro, Nishimura Junichi, Iwata Hiromitsu, Ogino Hiroyuki, Hashizume Takuya, Shibamoto Yuta. Percutaneous fiducial marker placement prior to stereotactic body radiotherapy for malignant liver tumors: an initial experience. *J Radiat Res* 2016;57:174–7.
- [8] Ohta K, Shimohira M, Iwata H, et al. Percutaneous fiducial marker placement under CT fluoroscopic guidance for stereotactic body radiotherapy of the lung: an initial experience. *J Radiat Res* 2013;54:957–61.
- [9] Atel A, Khalsa B, Lord B, et al. Planting the seeds of success: CT-guided gold seed fiducial marker placement to guide robotic radiosurgery. *J Med Imaging Radiat Oncol* 2013;57:207–11.
- [10] Kim JH, Hong SS, Kim JH, et al. Safety and efficacy of ultrasound-guided fiducial marker implantation for cyberknife radiation therapy. *Korean J Radiol* 2012;13:307–13.
- [11] Peiffert D, Baumann AS, Marchesi V. Treatment of hepatic metastases of colorectal cancer by robotic stereotactic radiation (Cyberknife). *J Visc Surg* 2014;151:S45–9.
- [12] Koong AC, Christofferson E, Le QT, Goodman KA, Ho A, Kuo T, et al. Phase II study to assess the efficacy of conventionally fractionated radiotherapy followed by a stereotactic radiosurgery boost in patients with locally advanced pancreatic cancer. *Int J Radiat Oncol Biol Phys* 2005;63:320–3.
- [13] Kats AJ, Santoro M, Diblasio F, Ashley R. Stereotactic body radiotherapy for localized prostate cancer: disease control and quality of life at 6 years. *Radiation Oncology* 2013;8:118.
- [14] Tse RV, Hawkins M, Lockwood G, Kim JJ, Cummings B, Knox J, et al. Phase I study of individualized stereotactic body radiotherapy for hepatocellular carcinoma and intrahepatic cholangiocarcinoma. *J Clin Oncol* 2008;26:657–64.
- [15] Hirato H, Harada T, Harabayashi T, et al. Feasibility of insertion/implantation of 2.0-mm-diameter gold internal fiducial markers for precise setup and real-time tumor tracking in radiotherapy. *Int J Radiat Oncol Biol Phys* 2003;56:240–7.
- [16] Davila Fajardo R, Lekkerkerker SJ, van der Horst A. EUS-guided fiducial markers placement with a 22-gauge needle for image-guided radiation therapy in pancreatic cancer. *Gastrointest Endosc* 2014;79:851–85.
- [17] Ammar T, Cote GA, Creach KM. Fiducial placement for stereotactic radiation by using EUS: feasibility when using a marker compatible with a standard 22-gauge needle. *Gastrointest Endosc* 2010;71:630–3.
- [18] DiMaio CJ, Nagula S, Goodman KA. EUS-guided fiducial placement for image-guided radiation therapy in GI malignancies by using a 22-gauge needle. *Gastrointest Endosc* 2010;71:1204–10.
- [19] Kim JH1, Hong SS, Kim JH, Park HJ, Chang YW, Kwon SB. Safety and efficacy of ultrasound-guided fiducial marker implantation for CyberKnife radiation therapy. *Korean J Radiol* 2012;13(3):307–13.
- [20] Shiozawa K, Watanabe M, Ikehara T, Kobayashi K, Ochi Y, Suzuki Y, et al. Evaluation of contrast-enhanced ultrasonography for hepatocellular carcinoma prior to and following stereotactic body radiation therapy using the CyberKnife® system: a preliminary report. *Oncol Lett* 2016;11(1):208–12.
- [21] Patel A, Khalsa B, Lord B, et al. Planting the seeds of success: CT-guided gold seed fiducial marker placement to guide robotic radiosurgery. *J Med Imaging Radiat Oncol* 2013;57:207–11.
- [22] Sotiropoulou E, Stathochristopoulou I, Stathopoulos K, Verigos K, Salvaras N, Thanos L. CT-guided fiducial placement for cyberknife stereotactic radiosurgery: an initial experience. *Cardiovasc Intervent Radiol* 2010;33:586–9.
- [23] Ohta K1, Shimohira M2, Murai T3, Nishimura J4, Iwata H5, Ogino H5, Hashizume T2, Shibamoto Y2. Percutaneous fiducial marker placement prior to stereotactic body radiotherapy for malignant liver tumors: an initial experience. *J Radiat Res* 2016;57(2):174–7.
- [24] Marsico M, Gabbani T, Livi L, Biagini MR, Galli A. Therapeutic usability of two different fiducial gold markers for robotic stereotactic radio surgery of liver malignancies: a pilot study. *World J Hepatol* 2016;8(17):731–8.