



# How Atypical Penile Curvature Influence Clinical Outcomes in Patients with Peyronie's Disease Receiving Collagenase *Clostridium Histolyticum* Therapy?

Andrea Cocci<sup>1</sup>, Fabrizio Di Maida<sup>1</sup>, Giorgio Ivan Russo<sup>2</sup>, Marina di Mauro<sup>2</sup>, Gianmartin Cito<sup>1</sup>, Marco Falcone<sup>3</sup>, Andrea Minervini<sup>1</sup>, Giovanni Cacciamani<sup>4</sup>, Riccardo Campi<sup>1</sup>, Andrea Mari<sup>1</sup>, Francesco Sessa<sup>1</sup>, Nicola Mondaini<sup>5</sup>

<sup>1</sup>Department of Urology, Careggi Hospital, University of Florence, Florence, <sup>2</sup>Department of Urology, Vittorio Emanuele II, University of Catania, Catania, <sup>3</sup>Department of Urology, University of Turin, Turin, <sup>4</sup>Department of Urology, University of Verona, Verona, <sup>5</sup>Urology Section, Villa Donatello Clinic, Sesto Fiorentino, Italy

**Purpose:** The aim of this study was to evaluate the efficacy of collagenase *Clostridium histolyticum* (CCH) in patients with Peyronie's disease (PD) suffering from atypical deformities.

**Materials and Methods:** We retrospectively collected data of patients with atypical penile curvature (PC) secondary to PD. All patients underwent a modified treatment protocol, consisting of 3 intralesional injections of 0.9 mg of CCH performed at 4-week intervals at the point of maximum PC. Patients were instructed to follow a strict routine, involving daily modeling of erect penis and stretching at the urinary toilette time, two minutes each. Success was defined as a decrease in PC of  $\geq 20^\circ$  from baseline.

**Results:** Sixty-five patients were included in the analysis. Median age was 59.0 years (interquartile range [IQR], 53.0 to 63.0 years), median curvature  $40.0^\circ$  (IQR,  $30.0^\circ$  to  $45.0^\circ$ ) median duration of the disease 12.0 years (IQR, 6.5 to 24.0 years). Fifty-three patients (81.54%) had ventral PC, 7 (10.77%) hourglass PC, and 5 (7.69%) shortening PC. Median changes of PC were  $-20.0$  (IQR,  $-20.0$  to  $-10.0$ ;  $p < 0.01$ ) in ventral PC,  $-20.0$  (IQR,  $-20.0$  to  $0$ ;  $p < 0.01$ ) in hourglass and  $-15.0$  (IQR,  $-15.0$  to  $-15.0$ ;  $p < 0.01$ ) in shortening PC. At Kruskal–Wallis test, significant differences between groups were not found. The rate of PC success was 56.60% (30/53) in ventral PC, 57.14% (4/7) in hourglass and 20.00% (1/5) in shortening PC ( $p = 0.29$ ). Treatment success was not influenced by characteristics of curvature (odds ratio=0.66;  $p = 0.20$ ).

**Conclusions:** CCH intralesional injections could represent an effective therapeutic option for the conservative management of patients with atypical PC.

**Keywords:** Collagenases; Intralesional injections; Therapeutics; Penile induration; Peyronie's disease

This is an Open Access article distributed under the terms of the Creative Commons Attribution Non-Commercial License (<http://creativecommons.org/licenses/by-nc/4.0>) which permits unrestricted non-commercial use, distribution, and reproduction in any medium, provided the original work is properly cited.

**Received:** Feb 21, 2019 **Revised:** Apr 8, 2019 **Accepted:** Apr 28, 2019 **Published online:** May 29, 2019

**Correspondence to:** Andrea Cocci <https://orcid.org/0000-0003-0138-6294>

Department of Urology, Careggi Hospital, University of Florence, Largo Brambilla, 3, 50139, Florence, Italy.

**Tel:** +39-0557949203, **Fax:** +39-0557949046, **E-mail:** [cocci.andrea@gmail.com](mailto:cocci.andrea@gmail.com)

## INTRODUCTION

Peyronie's disease (PD) is characterised by the onset of localized fibrous inelastic scars at the level of the tunica albuginea, consequently inducing several symptoms, such as penile curvature (PC), painful erections, and erectile dysfunction (ED). Although its prevalence is often underestimated, according to current available literature, from 0.4% to 9.0% of male population is affected, with higher prevalence among patients suffering from ED and diabetes [1,2]. The pathophysiology of PD is still object of great debate. Hypothetically, there might be a disorder of the healing mechanism at the level of tunica albuginea, which can be injured by microtraumas during sexual intercourses [3,4]. The starting inflammation process of tunica albuginea is later followed by the development of fibrous plaques, which cause the well-known penile deformity, shortening, and a variable degree of ED [5].

There are different therapeutic options for the management of PD, including pharmacologic and surgical approaches, in relation to the degree of PC and symptoms associated [6]. To date, several medical therapies have been suggested for the treatment of PD, but none of them have proven to be effective as collagenase *Clostridium histolyticum* (CCH). Intraplaque injection therapy with CCH (Xiaflex; Endo Pharmaceuticals, Inc., Malvern, PA, USA) represents the first therapy authorized by the US Food and Drug Administration for the non-surgical management of PD, in presence of stable palpable plaque and PC of at least 30°, but no more than 90° before the beginning of treatment [7].

The majority of men suffering from PD refer to the clinician with a palpable plaque and a uniplanar dorso-lateral curvature. Nevertheless, in rare circumstances, the patients might present with "atypical" deformities, such as ventral curvature, hourglass deformity, and severely shortened penis. Due to their low prevalence, in current available literature there are few reports that analyse the possible treatment options for PD presenting with atypical PC. In this scenario, the assessment of the efficacy of CCH injections in patients with atypical PC currently represents a clinical unmet need. Thus, the aim of this study was to evaluate the efficacy of a modified CCH treatment protocol on the improvement of PC in patients suffering from atypical deformities.

## MATERIALS AND METHODS

### 1. Study population and ethics statement

The present study protocol was reviewed and approved by the Institutional Review Board of University of Florence, Careggi Hospital. Informed consent was submitted by all subjects when they were enrolled. We retrospectively reviewed our prospectively collected PD database to select consecutive patients with atypical PC treated with CCH from November 2016 to November 2018.

Each patient signed a written fully informed consent statement before being enrolled in the study. Inclusion criteria at baseline were: age  $\geq 18$  years, presence of "atypical" presentations, such as ventral curvature, hourglass deformity and severely shortened penis, PC  $\geq 30^\circ$ , but no greater than  $90^\circ$ , currently stable, no previous surgery for PD. Stable disease has been defined as no pain in conjunction with no curvature worsening during the last year. Severe penile shortening was associated with uncommon curvature, such as ventral or hourglass deformity.

All patients received pharmacologically induced erection test using intra-cavernous injection in order to evaluate the degree of PC at baseline and at the end of the treatment. In case of ventral curvatures, CCH was injected in the palpable stable plaque at the point of maximum curvature over the urethra. In this subset of PC, we not took any particular precautions, since there was no major technical difficulty. We just protect urethra between two fingers, at the time of the injection. In case of hourglass deformities, CCH was injected exactly in the centre of the plaque with the purpose to broke the plaque. All patients enrolled were treated with CCH-Xiapex using a new shortened protocol originally described by Abdel Raheem et al [8]. In particular, this consisted of a treatment cycle of three intralésional injections of CCH 0.9 mg, divided by 4-weekly intervals. After the procedure, patients were instructed to keep the penis elevated and to avoid sexual intercourse for the following 14 days. Between injections, the patients were strongly recommended to perform a combination of modelling, stretching, and vacuum therapy, in order to mechanically stretch the fibrous plaque. As such, starting 24 to 48 hours after the CCH injection, home gentle modelling of erect penis was performed. Stretching exercises provided a gradual stretch of the penis for 2 minutes each, at the urinary toilette

time. Vacuum-pump therapy was performed using the Rapport Classic Vacuum system (Owen Mumford, Inc., Marietta, GA, USA; distributed by Medis, Rozzano, Italy). The patients were instructed to use the vacuum device without the constriction ring, only after 2 to 3 days from the CCH injection, once a day for two minutes, to mechanically stretch the penis. The cylinder was placed on the penis and slowly inflated until the penis was erect and maintained in this position for about 60 seconds. The vacuum was then released to allow the erection to subside and the process was repeated again five times during each treatment session.

## 2. Outcome measures

PC was measured using a ruler application, at baseline and at the end of the treatment. In case of shortening PC, also the length of the penis was measured. Patients were asked to write-off self-administered questionnaires such as the International Index of Erectile Function (IIEF-15) [9] and the Peyronie's disease questionnaires (PDQ) [10]. The IIEF-15 scale analyses the degree of ED, classified as follows: severe (IIEF-15≤10), moderate (IIEF-15 between 11 and 16) and mild (IIEF-15 between 17 and 25). The IIEF-15 sub-scores and its subdomains were assessed, including IIEF-erectile function (IIEF-EF). The PDQ is a 15-question survey which gradates the influence and severity of PD symptoms on psychological and physical symptoms, penile pain and symptoms bother. Patients were asked to fulfil the PDQ scale only if they had had sexual intercourse within the previous 90 days.

Treatment satisfaction was evaluated by using a scale from 1 to 10. High satisfaction after treatment was defined as a score ≥8. Success of therapy was defined as a PC decrease of at least 20% from baseline curvature.

## 3. Statistical analysis

First, descriptive statistics were obtained reporting medians (and interquartile ranges [IQRs]) for continuous variables, and frequencies and proportions for categorical variables, as appropriate. Continuous variables were compared by the Student independent T-test or the Mann–Whitney U-test based on their normal or not-normal distribution, respectively (normality of variables' distribution was tested by the Kolmogorov–Smirnov test). Categorical variables were tested with the chi-square test. Differences between median PC changes observed in the different groups were compared using Kruskal–Wallis test. All statistical analyses were performed using IBM SPSS ver. 24 (IBM SPSS Statistics for Mac; IBM Corp., Armonk, NY, USA). All tests were two-sided with a significance set at  $p<0.05$ .

## RESULTS

A total of 65 patients were included in the analysis. Preoperative features are reported in Table 1. Median age was 59.0 years (IQR, 53.0 to 63.0 years). Fifty-three patients (81.54%) had ventral PC, 7 (10.77%) had hourglass PC, and 5 (7.69%) shortening PC. Severe penile shortening was associated in 3/5 cases with ventral PC and in 2/5 cases with hourglass PC (Table 1). Median curvature was 40.0° (IQR, 30.0° to 45.0°) and median duration of the disease was 12.0 years (IQR, 6.5 to 24.0 years). The mean IIEF-EF was 23.56±4.10 while the mean PDQ was 27.06±13.55 before the beginning of the treatment.

After the final follow-up, we observed a significant median change for PC of -20.0 (IQR, -20.0 to -10.0;  $p<0.01$ ) in ventral PC, -20.0 (IQR -20.0 to 0;  $p<0.01$ ) in hourglass and -15.0 (IQR, -15.0 to -15.0;  $p<0.01$ ) in shortening PC, respectively (Fig. 1, Table 2). No significant differences were found in median PC improvements

**Table 1.** Characteristics of the population

Variable	Overall (n=65)	Ventral PC (n= 53)	Hourglass PC (n=7)	Shortening PC (n=5)	p-value*
Age (y)	59.0 (53.0 to 63.0)	59.0 (53.0 to 63.0)	54.0 (51.0 to 69.0)	56.0 (54.0 to 59.0)	0.89
Partner's age (y)	48.0 (41.0 to 56.0)	47.0 (40.5 to 54.5)	50.5 (41.5 to 61.0)	59.0 (54.0 to 64.0)	0.60
Duration disease (mo)	12.0 (6.5 to 24.0)	12.0 (6.5 to 24.0)	12.0 (7.0 to 18.0)	8.0 (4.0 to 16.0)	0.39
PC (°)	40.0 (30.0 to 45.0)	40.0 (30.0 to 45.0)	35.0 (20.0 to 40.0)	40.0 (30.0 to 45.0)	0.54

Values are presented as median (interquartile range).

PC: penile curvature.

\*Kruskal–Wallis test.

after the treatment between the groups ( $p=0.93$ ). Overall median treatment satisfaction was 8.0 (IQR, 7.0 to 9.0). After the treatment, we reported significant changes for all questionnaires and sub-domain after treatment. No major complications were reported. The most common adverse events not differed from the other subset of curvatures. Most adverse reactions were local events of the penis, such as ecchymosis occurring in 50/65 patients (76.92%). All of these adverse events resolved within 14 days. The rate of PC success was 56.60% (30/53) in ventral PC, 57.14% (4/7) in hourglass and 20.00% (1/5) in shortening PC ( $p=0.29$ ). When analysing factors associated with PC improvement after treatment, we found that characteristics of curvature did not represent a significant predictor of PC improvement after treatment (odds ratio=0.66;  $p=0.20$ ). After treatment, the mean IIEF-EF was  $25.86\pm 5.40$  while the mean PDQ was  $28.70\pm 11.50$ .

## DISCUSSION

This is the first published study, to the best of our knowledge, to specifically evaluate the safety and efficacy of intralesional injection with CCH for the management of patients with PD presenting with atypical PC.

It is unequivocal that, to date, there is still lack of

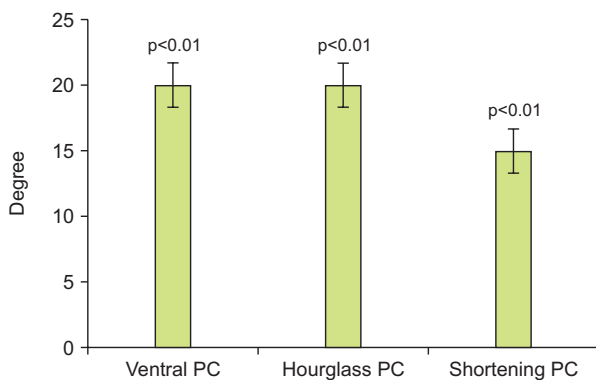


Fig. 1. Median changes in penile curvature (PC).

Table 2. Median changes in PC

Variable	Ventral PC	Hourglass PC	Shortening PC	p-value
Pre-treatment PC	40.0 (30.0 to 45.0)	35.0 (20.0 to 40.0)	40.0 (30.0 to 45.0)	<0.01
Post-treatment PC	20.0 (10.0 to 30.0)	20.0 (20.0 to 30.0)	25.0 (20.0 to 30.0)	<0.01
Median changes	-20.0 (-20.0 to -10.0)	-20.0 (-20.0 to 0)	-15.0 (-15.0 to -15.0)	<0.01

Values are presented as median (interquartile range).  
PC: penile curvature.

unanimous consent over the best practical management of PD. According to the European Association of Urology guidelines, the results of the studies on conservative treatment for PD are often contradictory making it difficult to directly translate such recommendations to the everyday clinical practice [11]. Although several pharmacological treatments have been proposed, only intralesional CCH injection therapy has proven itself to be effective enough for the conservative treatment of PD. The safety and efficacy of CCH in the management of PD have already been tested through several clinical trials enrolling nearly 1500 patients over the last three decades [11-16]. In particular, based on the positive findings of two milestone trials, Investigation for Maximal Peyronie's Reduction Efficacy and Safety Studies (IMPRESS) 1 and 2, intralesional injection of CCH has emerged as the first medication authorised by the Food and Drug Administration for the conservative management of PD [17,18]. Nevertheless, ventral location of plaque and hourglass deformity were among the major trials' exclusion criteria in the above-mentioned studies, mainly because of the concern of urethral wound. As such, there is still lack of evidence regarding the efficacy of CCH intralesional injection in patients with atypical PC.

Herein we firstly report a study in which we demonstrate the efficacy of a modified treatment protocol with CCH in the improvement of PC in patients with atypical PD. In particular, we found that CCH treatment was associated with a significant median change for PC of -20.0 ( $p<0.01$ ) in ventral PC, -20.0 ( $p<0.01$ ) in hourglass PC, and -15.0 ( $p<0.01$ ) in shortening PC, respectively. In addition, IIEF scores and its subdomains, as well, have all improved. Interestingly, when analysing factors associated with PC improvement, we found that characteristics of curvature did not represent a significant predictor of PC improvement after conservative treatment.

The efficacy of CCH intralesional injection over the

conservative management of ventral PC has been widely questioned and is still object of great debate [19,20]. Nearly 10% of patients with PD present with ventral plaques, and the subsequent PC has a significant impact on individual sexual lives. Unfortunately, to date there is lack of data in contemporary literature describing the optimal treatment for this particular setting of patients. In this scenario, one retrospective study conducted by Stewart et al compared the efficacy of intralesional interferon-alpha2b for the conservative treatment of dorsal *versus* ventral plaques [21]. It was found that intralesional interferon-alpha2b ameliorated PC by at least 20° in more than 90% of patients, irrespective of plaque location, paving the way to the assumption that even ventral plaques might be conservatively managed [22]. To date, clinical trials have not yet evaluated the use of CCH for the treatment of ventral plaques. However, Milam [23] recently described the first results of two men treated with CCH for ventral PC. These patients showed an objective reduction of PC after the fourth cycle of CCH, with a subjective amendment of symptoms and lack of serious side effects. In even rarer cases, patients with PD might present with hourglass deformity, penile shortening, or multiplanar curvature. One meta-analysis conducted by Yafi et al [21] stated that although patients with hourglass deformity or multiplanar curvature are usually treated with plaque incision or partial excision and grafting, however this particular setting of patients might benefit also from more conservative treatment options such as intraplaque injection therapy. In light of these findings, the current contraindication of using CCH in patients with ventral plaques or other complex penile deformities might be worth revisiting.

Furthermore, in our study patients were recommended to perform a combination of modelling, stretching, and vacuum therapy, in order to mechanically stretch the fibrous plaque between injections. Nonetheless, the role of modeling and vacuum therapy in improving PC in PD is still object of great discussion [24]. Based on current available literature, it has been suggested that modelling in conjunction with CCH and vacuum therapy further might reduce tunical constraint secondary to the PD plaque [25-29]. Similarly, fewer and lower level-of-evidence studies are available on vacuum therapy as a combination therapy during CCH injections. A recent observational study assessed CCH efficacy combined with vacuum device between injection inter-

vals. All patients used a combination of manual modeling, stretching and vacuum therapy. Findings showed statistically significant mean improvements in PC and length after treatment. [8]. Anyhow, further studies are needed to better assess the benefits of penile stretching and vacuum therapy. Moreover, in our case series we found significant increase of all female sexual function index-subdomains, according to our previous research [2].

Our study is not devoid of several limitations including its retrospective nature, lack of direct verification of correct use of penile modelling and limited cohort size for group comparisons. The latter was, however, to be expected, considering the lower prevalence of PD presenting with atypical PC. Each of these factors might have added statistical bias, undermining the final reliability of reported results. However, acknowledged these limitations, the present study represents the largest series so far evaluating the safety and efficacy of CCH penile injection over the management of PD presenting with atypical PC. Moreover, since the characteristics of the curvature did not represent a predictor of the improvement, the study may not have enough power to demonstrate such a result.

It is clear that a change in the management of PD is mandatory in the nearest future and further studies focusing on the correct identification patient represent a precise unmet need. Particularly, further well-designed studies will have to confirm these initial observations. Studies evaluating the long-term effects of CCH therapy also in patients with ventral PC as well larger trials identifying predictors of treatment success in different subgroups of PD patients would also be needed.

## CONCLUSIONS

Although surgical treatment still represents the gold standard for PD with plaque calcification or disabling ED, CCH seems to provide an effective minimally invasive option also for men presenting with atypical PC and might have the potential to change disease progression. Further prospective studies with higher statistical power and larger cohorts will be required to confirm our preliminary findings.

## Conflicts of Interest

The authors have nothing to disclose.

## Author Contribution

Conceptualization: AC, FDM. Data curation: GC, GIR, FS, AM, RC. Formal analysis: MdM, MF. Supervision: AM, NM. Validation: GC. Visualization: AC, NM. Writing—original draft: AC, FDM, MdM. Writing—review & editing: AC, NM.

## Data Sharing Statement

The data required to reproduce these findings cannot be shared at this time as the data also forms part of an ongoing study.

## REFERENCES

1. Cocci A, Russo GI, Briganti A, Salonia A, Cacciamani G, Capece M, et al. Predictors of treatment success after collagenase *Clostridium histolyticum* injection for Peyronie's disease: development of a nomogram from a multicentre single-arm, non-placebo controlled clinical study. *BJU Int* 2018;122:680-7.
2. Cocci A, Russo GI, Salonia A, Cito G, Regis F, Polloni G, et al. Predictive factors of patients' and their partners' sexual function improvement after collagenase *Clostridium histolyticum* injection for Peyronie's disease: results from a multi-center single-arm study. *J Sex Med* 2018;15:716-21.
3. Rosen R, Catania J, Lue T, Althof S, Henne J, Hellstrom W, et al. Impact of Peyronie's disease on sexual and psychosocial functioning: qualitative findings in patients and controls. *J Sex Med* 2008;5:1977-84.
4. Nelson CJ, Mulhall JP. Psychological impact of Peyronie's disease: a review. *J Sex Med* 2013;10:653-60.
5. Chung E, De Young L, Brock GB. Penile duplex ultrasonography in men with Peyronie's disease: is it veno-occlusive dysfunction or poor cavernosal arterial inflow that contributes to erectile dysfunction? *J Sex Med* 2011;8:3446-51.
6. Nehra A, Alterowitz R, Culkin DJ, Faraday MM, Hakim LS, Heidelbaugh JJ, et al.; American Urological Association Education and Research, Inc. Peyronie's disease: AUA guideline. *J Urol* 2015;194:745-53.
7. Bella AJ, Perelman MA, Brant WO, Lue TF. Peyronie's disease (CME). *J Sex Med* 2007;4:1527-38.
8. Abdel Raheem A, Capece M, Kalejaiye O, Abdel-Raheem T, Falcone M, Johnson M, et al. Safety and effectiveness of collagenase *Clostridium histolyticum* in the treatment of Peyronie's disease using a new modified shortened protocol. *BJU Int* 2017;120:717-23.
9. Coyne KS, Currie BM, Thompson CL, Smith TM. Responsiveness of the Peyronie's Disease Questionnaire (PDQ). *J Sex Med* 2015;12:1072-9.
10. Rosen RC, Riley A, Wagner G, Osterloh IH, Kirkpatrick J, Mishra A. The international index of erectile function (IIEF): a multidimensional scale for assessment of erectile dysfunction. *Urology* 1997;49:822-30.
11. Hatzimouratidis K, Giuliano F, Moncada I, Muneer A, Salonia A. EAU guidelines on erectile dysfunction, premature ejaculation, penile curvature and priapism [cited 2017 Nov 25]. Available from: <http://uroweb.org/guideline/male-sexual-dysfunction/>.
12. Gelbard MK, James K, Riach P, Dorey F. Collagenase versus placebo in the treatment of Peyronie's disease: a double-blind study. *J Urol* 1993;149:56-8.
13. Gelbard MK, Walsh R, Kaufman JJ. Collagenase for Peyronie's disease experimental studies. *Urol Res* 1982;10:135-40.
14. Jordan GH. The use of intralesional clostridial collagenase injection therapy for Peyronie's disease: a prospective, single-center, non-placebo-controlled study. *J Sex Med* 2008;5:180-7.
15. Gelbard MK, Lindner A, Kaufman JJ. The use of collagenase in the treatment of Peyronie's disease. *J Urol* 1985;134:280-3.
16. French ME, Mookhtiar KA, Van Wart HE. Limited proteolysis of type I collagen at hyperreactive sites by class I and II *Clostridium histolyticum* collagenases: complementary digestion patterns. *Biochemistry* 1987;26:681-7.
17. Capece M, Cocci A, Russo G, Cito G, Giubilei G, Cacciamani G, et al. Collagenase *Clostridium histolyticum* for the treatment of Peyronie's disease: a prospective Italian multicentric study. *Andrology* 2018;6:564-7.
18. Gelbard M, Goldstein I, Hellstrom WJ, McMahon CG, Smith T, Tursi J, et al. Clinical efficacy, safety and tolerability of collagenase *Clostridium histolyticum* for the treatment of Peyronie disease in 2 large double-blind, randomized, placebo controlled phase 3 studies. *J Urol* 2013;190:199-207.
19. Levine LA, Cuzin B, Mark S, Gelbard MK, Jones NA, Liu G, et al. Clinical safety and effectiveness of collagenase *Clostridium histolyticum* injection in patients with Peyronie's disease: a phase 3 open-label study. *J Sex Med* 2015;12:248-58.
20. Yafi FA, Hatzichristodoulou G, Knoedler CJ, Trost LW, Sikka SC, Hellstrom WJ. Comparative analysis of tunical plication vs. intralesional injection therapy for ventral Peyronie's disease. *J Sex Med* 2015;12:2492-8.
21. Yafi FA, Hatzichristodoulou G, DeLay KJ, Hellstrom WJ. Re-

- view of management options for patients with atypical Peyronie's disease. *Sex Med Rev* 2017;5:211-21.
22. Stewart CA, Yafi FA, Knoedler M, Mandava SH, McCaslin IR, Sangkum P, et al. Intralesional injection of interferon- $\alpha$ 2b improves penile curvature in men with Peyronie's disease independent of plaque location. *J Urol* 2015;194:1704-7.
  23. Milam D. Positive results with Collagenase Clostridium histolyticum treatment in two patients with ventral penile curvature due to Peyronie's disease. Paper presented at: 21st Annual Fall Scientific Meeting of the Sexual Medicine Society of North America; 2015 Nov 19-22; Las Vegas, USA. abstract 116.
  24. Avant RA, Ziegelmann M, Nehra A, Alom M, Kohler T, Trost L. Penile traction therapy and vacuum erection devices in Peyronie's disease. *Sex Med Rev* 2019;7:338-48.
  25. Ziegelmann MJ, Viers BR, Montgomery BD, Avant RA, Savage JB, Trost LW. Clinical experience with penile traction therapy among men undergoing collagenase Clostridium histolyticum for Peyronie disease. *Urology* 2017;104:102-9.
  26. Chung E, Ralph D, Kagioglu A, Garaffa G, Shamsodini A, Bivalacqua T, et al. Evidence-based management guidelines on Peyronie's disease. *J Sex Med* 2016;13:905-23.
  27. Cocci A, Cito G, Urzi D, Minervini A, Di Maida F, Sessa F, et al. Sildenafil 25 mg ODT + Collagenase Clostridium histolyticum vs Collagenase Clostridium histolyticum alone for the management of Peyronie's disease: a matched-pair comparison analysis. *J Sex Med* 2018;15:1472-7.
  28. Ralph DJ, Abdel Raheem A, Liu G. Treatment of Peyronie's disease with Collagenase Clostridium histolyticum and vacuum therapy: a randomized, open-label pilot study. *J Sex Med* 2017;14:1430-7.
  29. Raheem AA, Garaffa G, Raheem TA, Dixon M, Kayes A, Christopher N, et al. The role of vacuum pump therapy to mechanically straighten the penis in Peyronie's disease. *BJU Int* 2010;106:1178-80.