



OPEN ACCESS

Research article

Pattern and degree of left ventricular remodeling following a tailored surgical approach for hypertrophic obstructive cardiomyopathy

Ismail El-Hamamsy^{1,2}, Karim Lekadir³, Iacopo Olivetto⁴, Ahmed El Guindy², Robert Merrifield³, Luigi Rega⁵, GuangZong Yang³, Franco Cecchi⁴, Magdi H. Yacoub^{2,*}

ABSTRACT

Background The role of a tailored surgical approach for hypertrophic cardiomyopathy (HCM) on regional ventricular remodelling remains unknown. The aims of this study were to evaluate the pattern, extent and functional impact of regional ventricular remodelling after a tailored surgical approach.

Methods From 2005 to 2008, 44 patients with obstructive HCM underwent tailored surgical intervention. Of those, 14 were ineligible for cardiac magnetic resonance (CMR) studies. From the remainder, 14 unselected patients (42 ± 12 years) underwent pre- and post-operative CMR studies at a median 12 months post-operatively (range 4–37 months). Regional changes in left ventricular (LV) thickness as well as global LV function following surgery were assessed using CMR Tools (London, UK).

Results Pre-operative mean echocardiographic septal thickness was 21 ± 4 mm and mean LV outflow gradient was 69 ± 32 mmHg. Following surgery, there was a significant degree of regional regression of LV thickness in all segments of the LV, ranging from 16% in the antero-lateral midventricular segment to 41% in the anterior basal segment. Wall thickening was significantly increased in basal segments but showed no significant change in the midventricular or apical segments. Globally, mean indexed LV mass decreased significantly after surgery (120 ± 29 g/m² versus 154 ± 36 g/m²; $p < 0.001$). There was a trend for increased indexed LV end-diastolic volume (70 ± 13 mL versus 65 ± 11 mL; $p = 0.16$) with a normalization of LV ejection fraction ($68 \pm 7\%$ versus $75 \pm 9\%$; $p < 0.01$).

Conclusion Following a tailored surgical relief of outflow obstruction for HCM, there is a marked regional reverse LV remodelling. These changes could have a significant impact on overall ventricular dynamics and function.

Keywords: hypertrophic cardiomyopathy, tailored myectomy, ventricular remodelling

¹Department of Cardiac Surgery, Montreal Heart Institute, Université de Montréal, Montreal, Canada

²Harefield Heart Science Center, National Heart and Lung Institute, Imperial College London, UK

³Biomedical Engineering, Imperial College London, UK

⁴Department of Cardiology, Azienda Ospedaliera Universitaria Careggi, Florence, Italy

⁵Department of Radiology, Azienda Ospedaliera Universitaria Careggi, Florence, Italy

*Email: m.yacoub@imperial.ac.uk

<http://dx.doi.org/10.5339/gcsp.2012.9>

Published: 3 July 2012

© 2012 El-Hamamsy et al., licensee Bloomsbury Qatar Foundation Journals. This is an open access article distributed under the terms of the Creative Commons

Attribution-NonCommercial license CC BY-NC 3.0 which permits unrestricted non-commercial use, distribution and reproduction in any medium, provided the original work is properly cited.

INTRODUCTION

Hypertrophic cardiomyopathy (HCM) is a heterogeneous genetic disease which can present with a wide spectrum of phenotypic manifestations affecting the interventricular septum, the ventricular muscle, the mitral valve, the subvalvular apparatus and the papillary muscles [1–4]. These abnormalities can result in dysfunction of the left ventricular outflow tract (LVOT) resulting in dynamic LVOT obstruction [5], which is identified in up to 70% of subjects with HCM [6]. In addition to causing symptoms, LVOT obstruction is a direct prognostic indicator of long-term patient survival [7]. Thus, relief of LVOT obstruction has important clinical implications on both morbidity and mortality.

Along with the septal location, ventricular hypertrophy affecting areas of the left ventricle (LV) remote from the septum has been well recognized [3,4,8,9]. Hypertrophy of remote areas can be part of the disease process or represent a compensatory mechanism secondary to increased afterload due to LVOT obstruction, a matter yet unresolved [1]. The degree of LV hypertrophy estimated by indexed LV mass or thickness is an important predictor of outcomes in patients with HCM [4,10]. Thus, although the primary objective of surgery in HCM is the relief of LVOT obstruction, its effect on the different segments of the LV may also be significant. The pattern of LV remodelling following alcohol septal ablation (ASA) has been previously evaluated [11]. However, the specific aspect of regional LV response in structure and function following surgical myectomy has not been studied before.

Several surgical and interventional techniques have been described for patients with HCM [12–17]. We have evolved a tailored surgical approach for the treatment of LVOT dysfunction which targets the various components of the disease including the septum, the fibrous trigones, the papillary muscles and subvalvular apparatus (*see Methods*). This technique aims to correct both the structure and function of the LVOT by restoring its normal dynamics, particularly at the level of the aortic-mitral junction [5].

Using cardiac magnetic resonance (CMR), the objectives of this study were to analyze the pattern and degree of regional and global LV remodelling following tailored surgical treatment of LVOT dysfunction. We specifically examined regional changes in LV thickness and thickening following surgery as well as global changes in LV volumes, systolic function and mass.

METHODS

Patient population

From 2005 to 2008, 44 patients with obstructive HCM refractory to maximal medical therapy underwent tailored LVOT reconstructive procedure at the Azienda Ospedaliera Universitaria Careggi (Florence, Italy). All patients were invited to undergo pre- and post-operative CMR studies except for 14 patients who could not undergo CMR examination because of an implantable cardioverter-defibrillator ($n = 8$) or claustrophobia ($n = 6$). Of the remainder, 14 patients underwent complete pre- and post-operative CMR examinations ($n = 28$ studies) and were included for this study. Comparison of included and non-included patients showed no differences between the two groups in terms of pre-, per- and post-operative outcomes (*data not shown*).

Patient characteristics and operative data of the study cohort ($n = 14$) are presented in Table 1. Mean age of the patients was 42 ± 12 years ($n = 10$ male; 71%). Mean maximum LVOT gradient measured by echocardiography was 68 ± 27 mmHg. All patients were on beta-blocker therapy pre- and post-operatively. Two patients (14%) had treated hypertension. There were no other significant comorbidities.

Surgical technique

Our surgical technique targets all components of LVOT dysfunction in a tailored fashion. Briefly, through a trans-aortic approach, an extended septal myectomy (Fig. 1) guided by pre-operative imaging of the depth, width and length of muscle hypertrophy, is performed. The left and right fibrous trigones are then explored and mobilized by removing the fibrous tissue from the angles of the trigones, thus restoring the normal mobility of the subaortic curtain [5]. To correct anterior displacement of the papillary muscles or their attachment to the lateral LV wall, the papillary muscles are thinned or mobilized from the free wall of the LV and abnormal chords restricting their mobility are cut. In addition, any obstructive accessory chord or mitral valve tissue is removed. Importantly, the mitral valve apparatus is preserved in all patients with no enlargement [12] or plication [13] of the anterior leaflet. On post-operative day 5, beta-blocker therapy is systematically reintroduced for all patients.

Table 1. Patient characteristics and operative outcomes.

Variable	Pre-op
Age (yrs)	42 ± 12
Male gender; n (%)	10 (71)
BSA (m ²)	1.9 ± 0.2
Time from surgery (median)	12 (4–37)
Clinical presentation	
NYHA III–IV	13 (93)
Syncope	1 (7)
Angina	4 (28)
Preoperative echo findings	
Max LVOT Gradient (mmHg)	68 ± 27
Septum (mm)	25 ± 4
Posterior wall (mm)	11 ± 2
30-Day Mortality	0 (0)
Post-operative gradient (mmHg)	9 ± 6

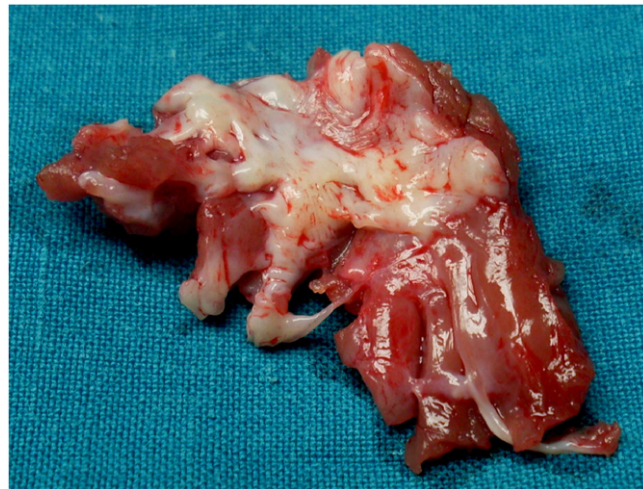

Figure 1. Myectomy specimen illustrating the extent of the resected muscle which includes the area of subendocardial fibrosis on the septum and three muscle bands extending into the midventricular region.

CMR studies

CMR was performed pre-operatively and at a minimum period of 4 months following operation (median 12 months; range 4–37 months). Magnetic resonance imaging was performed using a 1.5 T scanner (Intera 1.5 T Philips, gradient slope 30 mT/m) with a 5 element phased array coil. Cine images were acquired in multiple short-axis and long-axis views with a breath-hold, retrospective steady-state free precession sequence (slice thickness 8 mm, echo time 1.53 ms, matrix 168 × 195, SENSE factor 1.8). The number of *k*-space lines for each heartbeat was adjusted to permit the acquisition of 30 cardiac phases covering the whole cardiac cycle. The field of view was 340 mm on average and adapted to the size of the patient, leading to a spatial resolution of about 2 mm. A gadolinium-based contrast agent (0.1 mMol/kg) was then given intravenously, and contrast-enhanced images were acquired by using a 3D breath-hold inversion-recovery segmented gradient-echo sequence in the same views used for cine cardiac magnetic resonance series, 10–15 min after contrast administration. The optimal inversion time (IT) was obtained for each patient by visual inspection of a preliminary acquisition of a single-slice multi-IT series. The optimal IT (usually between 175 and 260 ms) was the one providing the best contrast between the myocardium and the left ventricular chamber.

Image analysis

Image analysis was performed using CMR Tools (CMR Tools Inc., London, UK), a validated and clinically approved image analysis software specifically designed for in-depth analysis of CMR studies. Importantly, it allows regional assessment of the LV by dividing it into 17 segments as

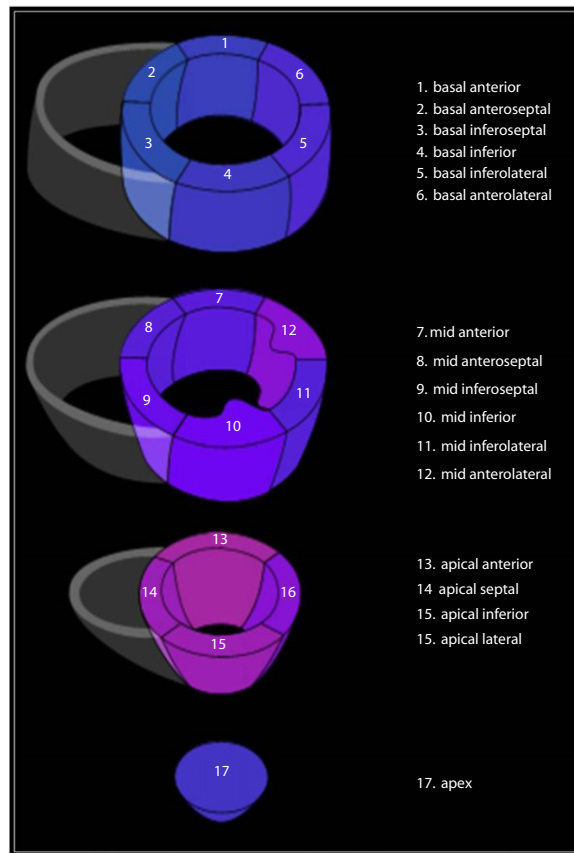


Figure 2. Schematic representation of the 17 left ventricular segments as recommended by the American Heart Association Standardized Myocardial Segmentation and Nomenclature for Imaging Guidelines.

recommended by the American Heart Association Standardized Myocardial Segmentation and Nomenclature for Imaging Guidelines (Fig. 2) [18].

Regional analyses

Regional analyses focused on segmental changes in LV thickness and thickening following surgery. The analysis was performed by manually delineating the endocardial and epicardial borders of the LV on each successive short-axis cine image. For LV thickness, measurements were made at end-diastole. Thickening was measured as the increase in ventricular thickness from end-diastole to end-systole. Papillary muscles were manually excluded from the analysis of LV on all short-axis views.

Global analyses

Global LV analysis consisted of changes in LV end-systolic and end-diastolic volumes (LVESV and LVEDV), LV ejection fraction (LVEF) and indexed LV mass. Using the same manual delineation method, LV volumes and ejection fraction were estimated. In addition, myocardial mass was calculated from contiguous short-axis views employing Simpson's rule. When multiplied by the density of myocardial tissue (1.05 g/cm³), the LV mass was obtained and indexed to body surface area (BSA) [19]. Left ventricular remodelling index (LVRI) defined as the LV mass/volume ratio was also assessed. LVRI has been reported to affect diastolic function parameters independent of intrinsic diastolic function and filling pressures [20]. In addition, pre- and post-operative LV longitudinal function was evaluated by measuring the mitral annular plane systolic excursion (MAPSE) during the cardiac cycle using CMR images in 2- and 4-chamber views.

Table 2. Changes in regional LV end-diastolic thickness following tailored surgical myectomy for HCM

	LV Segment	Pre-operative (mm)	Post-operative (mm)	% Change	p-value
Basal	Anterior	12.4 ± 2.9	7.3 ± 2.4	-41%	< 0.001
	Antero-Septal	11.9 ± 3.7	7.6 ± 3.5	-36%	0.03
	Infero-Septal	13.3 ± 4.4	8.1 ± 2.8	-39%	< 0.001
	Inferior	12.1 ± 2.6	8.4 ± 3.1	-31%	< 0.001
	Infero-Lateral	12.3 ± 2.4	8.1 ± 2.6	-34%	< 0.001
	Antero-Lateral	13.8 ± 3.6	9.8 ± 2.3	-29%	0.01
Mid	Anterior	17.2 ± 5.3	13.1 ± 4.2	-24%	0.03
	Antero-Septal	17.2 ± 5.9	13.9 ± 4.5	-19%	0.02
	Infero-Septal	16.3 ± 5.2	13.1 ± 4.1	-20%	0.02
	Inferior	14.5 ± 3.0	11.7 ± 2.6	-19%	< 0.01
	Infero-Lateral	13.5 ± 3.0	10.7 ± 2.5	-21%	< 0.01
Apical	Antero-Lateral	15.0 ± 2.7	12.6 ± 3.4	-16%	0.03
	Anterior	13.6 ± 5.1	10.9 ± 5.1	-20%	0.23
	Septal	14.6 ± 5.0	10.3 ± 4.4	-29%	0.02
	Inferior	12.7 ± 3.2	9.0 ± 2.3	-29%	< 0.001
Apex	Lateral	12.5 ± 3.2	9.3 ± 2.9	-26%	< 0.001
	Apex	8.7 ± 2.8	6.2 ± 1.1	-29%	0.02

Statistical methods

Data are expressed as mean ± standard deviation or median (range) for continuous variables and as number (percentage) for categorical variables. Univariable analyses included two-tailed Wilcoxon rank sum or Student's t-test for continuous variables and Fisher's exact test for discrete variables. A *p*-value <0.05 was considered statistically significant.

RESULTS

Operative results

Patient characteristics and operative outcomes are presented in Table 1. All patients underwent successful surgery with a significant reduction in mean trans-LVOT gradient (9 ± 6 mmHg versus 68 ± 27 mmHg; *p* < 0.001). There were no hospital mortalities. No patients had a perioperative myocardial infarction, required pacemaker implantation or required inotropic support after surgery.

Regional LV remodelling

Regional LV thickness

As shown in Table 2, there was a significant decrease in LV thickness (measured at end-diastole) in all basal segments following surgery, ranging from a 29% decrease in the antero-lateral septum to 41% decrease in the anterior septum (*p* < 0.05 for each segment). Similarly, there was a significant decrease in regional LV thickness in all segments of the mid-ventricle, ranging from a 16% decrease in the antero-lateral and infero-septal segments to a 24% decrease in the anterior segment (*p* < 0.05 for each segment). Additionally, a significant reduction in LV wall thickness was observed in all segments of the apex, except the anterior apical segment (*p* = 0.23). The decrease in the apical segments ranged from a 26% decrease in the lateral segment to a 29% decrease in all other segments (*p* < 0.05 for each segment).

Regional LV thickening

There was high variability between patients in the extent of changes in regional LV thickening following tailored myectomy (Table 3). Nevertheless, there was a noticeable pattern of changes which consisted of improved thickening in the segments of the base with little change in the other regions of the ventricle. Thus, there was a significant increase in the LV thickening at the level of the anterior segment of the base (93% increase; *p* = 0.02; Table 3). Similarly, there was a trend towards an increase in LV thickening in all other segments of the base, although this did not reach statistical significance. The increase ranged from 35% in the infero-septal segment (*p* = 0.07) to 78% in the inferior segment of the base (*p* = 0.08) and 79% in the antero-septal segment (*p* = 0.09). In contrast, there was little to no change in the degree of thickening of the various segments of the mid-ventricle and apex following surgery (Table 3).

Table 3. Changes in regional LV wall thickening following tailored surgical myectomy for HCM.

	LV Segment	Preoperative (%)	Postoperative (%)	% change	p-value
Basal	Anterior	38.0 ± 18.0	73.4 ± 41.4	+93%	0.02
	Antero-Septal	50.4 ± 37.0	90.0 ± 63.0	+79%	0.09
	Infero-Septal	55.8 ± 29.5	75.3 ± 36.6	+35%	0.07
	Inferior	58.3 ± 29.1	103.5 ± 78.1	+78%	0.08
	Infero-Lateral	68.7 ± 44.7	88.7 ± 46.3	+29%	0.30
Mid	Antero-Lateral	52.5 ± 31.0	48.4 ± 32.3	-8%	0.67
	Anterior	49.3 ± 28.2	58.4 ± 36.5	+18%	0.51
	Antero-Septal	49.7 ± 31.0	53.8 ± 29.3	+8%	0.61
	Infero-Septal	58.6 ± 27.8	62.7 ± 36.6	+7%	0.66
	Inferior	69.4 ± 28.1	73.2 ± 24.3	+5%	0.71
Apical	Infero-Lateral	86.4 ± 48.4	90.2 ± 24.8	+4%	0.76
	Antero-Lateral	66.4 ± 25.5	76.0 ± 33.9	+14%	0.41
	Anterior	75.6 ± 49.2	76.4 ± 46.9	+1%	0.96
	Septal	70.2 ± 39.9	67.4 ± 29.3	-4%	0.83
	Inferior	74.3 ± 30.5	76.0 ± 33.4	+2%	0.85
Apex	Lateral	79.9 ± 37.2	79.2 ± 34.0	-1%	0.93
	Apex	45.4 ± 28.6	45.6 ± 31.0	0%	0.98

Table 4. Changes in global LV function following tailored myectomy for HCM.

Variable	Pre-operative	Post-operative	P-value
Indexed LVEDV (mL/m ²)	65.3 ± 10.8	70 ± 13.2	0.16
Indexed LVESV (mL/m ²)	16 ± 5.5	22.4 ± 6.5	< 0.001
Indexed LV stroke volume (mL/m ²)	49.4 ± 10.5	47.8 ± 9.5	0.6
LV ejection fraction (%)	75 ± 9	68 ± 7	< 0.001
Indexed LV mass (g/m ²)	154 ± 36	120 ± 29	< 0.001
Left Ventricular Remodelling Index ¹	2.4 ± 0.7	1.8 ± 0.6	0.005
LV longitudinal systolic function (MAPSE, mm)	13.3 ± 3.8	12.1 ± 4.0	0.2

LVEDV, left ventricular end-diastolic volume; LVESV, left ventricular end-systolic volume; LV, left ventricle; MAPSE, mitral annular plane systolic excursion

¹ Measured as the indexed volume/mass ratio

Global LV volume and mass

Changes in global LV volume and mass are described in Table 4. Overall, there was a trend towards a statistically significant increase in mean indexed LVEDV (70 ± 13.2 mL/m² post-operatively versus 65.3 ± 10.8 mL/m² pre-operatively; $p = 0.16$). There was a parallel statistically significant increase in mean indexed LVESV (22.4 ± 6.5 mL/m² post-operatively versus 16 ± 5.5 mL/m² pre-operatively; $p < 0.001$). As a result, there were no changes in mean indexed stroke volume at rest following surgery (47.8 ± 9.5 mL/m² post-operatively versus 49.4 ± 10.5 mL/m² pre-operatively; $p = 0.6$) and a significant decrease in mean LVEF from 75 ± 9% pre-operatively to 68 ± 7% post-operatively ($p < 0.001$). Mean indexed LV mass showed a significant decrease from 154 ± 36 g/m² to 120 ± 29 g/m² following surgery ($p < 0.001$). In addition, LV remodelling index was significantly improved after surgery (1.8 ± 0.6 post-operatively vs. 2.4 ± 0.7 pre-operatively; $p = 0.005$). However, no significant change in mitral annular plane systolic excursion (longitudinal function) was observed after surgery (12.1 ± 4.0 mm post-operatively versus 13.3 ± 3.8 mm pre-operatively; $p = 0.2$).

DISCUSSION

This study illustrates that a tailored surgical approach results in a global and asymmetric pattern of LV remodelling in all segments of the ventricle, including those remote from the septum. This is accompanied by an increase in thickening of the basal septal segments following surgery, denoting improved regional systolic function. The pattern and extent of regional remodelling observed resulted in overall normalization of LV function and a significant decrease in indexed LV mass which, in addition to the reduction in LVOT gradient, could have important prognostic significance.

Diffuse LV hypertrophy in patients with HCM is likely due to a combination of two factors: the disease process affecting all ventricular myocytes and secondary hypertrophy due to increased afterload. Patients with HCM can present with a variety of patterns of hypertrophy sometimes involving the entire ventricle [8]. In patients requiring myectomy, it is often difficult to distinguish between pathogenic mechanisms based on pre-operative cardiac imaging. It is presumed that secondary hypertrophy is a reversible process whereas the reversibility of primary hypertrophy is less

likely. The present study shows that relief of obstruction consistently resulted in a significant and diffuse pattern of regional LV remodelling in an unselected sample of HCM cases.

The exact cause of the regional heterogeneity in the decrease in thickness is not known. Nevertheless, this could be partially explained by the regional heterogeneity of the changes in transmural pressures in the different segments following surgery. It is well known that cells in different parts of the body can sense and adapt to mechanical stimuli such as pressure or flow by translating them into biological signals such as cell migration, contraction, proliferation and growth factor synthesis (a process termed mechanotransduction) [21]. Changes in mechanical stimuli can thus result in changes in the local molecular and signalling environments, leading to varying degrees of cell size regression or extracellular matrix remodelling. Together, these result in an overall reduction in wall thickness without loss of contractile function. Another potential explanation for the regional heterogeneity in the extent of LV remodelling can be explained by differences in developmental origins of cardiomyocytes within the LV [22–25]. Various studies have demonstrated that cells from different developmental origins exhibit distinct biological responses to the same mechanical or biochemical stimuli [26–28]. Therefore, an equal reduction in transmural pressure can be interpreted differently by cells within the LV, leading to non-uniform remodelling. Apart from understanding the mechanisms of regression, the overall functional effect of the heterogeneous changes of LV myocardium on LV shape and pattern of contraction remain undetermined and need to be studied further. Finally, the heterogeneous pattern of remodelling could be a reflection of the phenotypic heterogeneity of hypertrophy in patients with HCM [5].

Basal septal systolic function is thought to be an essential component of the function of the LVOT and contributes to the rapid ejection of a bolus of blood from the flask-shaped LV during systole [5]. Regional analysis of LV thickening in our cohort showed improvement in basal systolic function following surgery as demonstrated by an increase in thickening in most segments of the base (Fig. 1). In contrast, although ASA can achieve satisfactory degrees of septal thinning, von Döckum et al. showed reduced thickening of the septum following ASA using CMR-based analyses [11]. On the other hand, in our study, there was no change in regional systolic function of the mid-ventricular and apical segments. This heterogeneous pattern of regional LV thickening following surgery may reflect the pathophysiological process in obstructive HCM. Because the bulk of the hypertrophy is located in the septum, surgical myectomy at that site results in improved regional myocardial blood flow and creates room for ventricular thickening. In contrast, the rest of the ventricle is contracting against an increased afterload in obstructive HCM, thus requiring maximal thickening to achieve an appropriate stroke volume. Post-operatively, hemodynamic conditions are significantly different as contractions of these regions of the LV are not opposed by obstruction at the LVOT. Therefore, a comparable degree of thickening before and after surgery suggests good preservation of regional LV systolic function in regions remote from the base.

The sum of the changes in the different LV segments on overall LV shape and function are characterized by a significant decrease in indexed LV mass, an increase in end-diastolic volumes and preserved stroke volume at rest. These changes represent a trend towards normalization of these parameters, particularly LV mass (Table 2). Other groups have shown similar patterns of overall LV functional changes following surgical myectomy or ASA, using echocardiographic or CMR imaging [11,29,30]. Van Döckum et al. showed a decrease in septal and non-septal wall mass following ASA [11]. Similar to our findings, they observed no change in LVEDV, increased LVESV, decreased LV mass and a normalization of LVEF [11]. Interestingly, following ASA, a statistically significant (albeit clinically mild) decrease in stroke volume at 1 month after the procedure was observed [11]. This could potentially be explained by the relatively large size of the infarct caused by alcohol injection.

The preserved stroke volume in the presence of a significantly lower ventricular mass suggests improved contractile efficiency following surgery, a result of absence of LVOT obstruction as well as a presumed improvement in myocardial perfusion in the various regions of the LV. Of course, in view of the reduction in mitral regurgitation following surgery, a preserved stroke volume results in a net increase in effective stroke volume index. Similarly, the observed normalization (decrease) in LVEF (with preserved stroke volume) following surgery, which was also reported in other studies, may reflect reduction of the hyper-adrenergic drive observed in obstructive HCM patients [1]. This may be an important factor in explaining the excellent long-term survival and low incidence of ventricular arrhythmias in myectomy patients.

The clinical significance of our findings is particularly important in light of the known independent predictors of symptom progression and mortality in patients with HCM. Maron et al. firmly established the link between obstruction (at rest or provoked) and progression of symptoms and/or survival [7]. Additionally, Spirito et al. suggested a link between maximal LV thickness at echocardiography and patient survival [10]. Olivotto et al. emphasized the role of indexed LV mass estimated by using 3D CMR in predicting outcomes [4]. Therefore, by achieving both a significant reduction in LVOT gradient and a diffuse decrease in regional LV thickness resulting in overall reduced indexed LV mass, a significant improvement in long-term patient symptoms, quality of life and survival can be expected. Additionally, de Castro et al. have shown that LVRI varies significantly between different pathophysiological conditions, with a ratio in healthy individuals close to 1 and a significantly higher ratio in patients with HCM [31]. The significant decrease in LVRI in this cohort of patients after surgery strongly supports the positive effects of surgical myectomy on overall diastolic function.

This study has several limitations. The CMR studies were performed at variable time points following surgery. Although this precludes us from defining the response of the LV at a specific time point after surgery, HCM is by definition a phenotypically heterogeneous disease. Drawing firm data on remodelling in a limited number of patients is therefore difficult. Nevertheless, this study establishes a clear pattern of LV remodelling after a tailored surgical approach. Evaluation of thickness and thickening at the basal septum using CMR can be challenging. However, the same method for analysis was used in all studies, therefore ensuring consistency in data analysis. Evaluation of changes in left atrial volumes by CMR could be of prognostic significance to the patients. Unfortunately, in the present study, complete imaging at the level of the atria was not acquired, making such studies incomplete.

CONCLUSION

In conclusion, this study demonstrates that the use of a tailored surgical approach for the treatment LVOT dysfunction in patients with HCM results in a diffuse and heterogeneous pattern of regional LV remodelling. This is characterized by a decrease in wall thickness in all segments of the LV along with an increase in thickening at rest in the basal septal segments. This results in overall reduction in indexed LV mass and improved contractile efficiency of the ventricle. These findings may have important clinical and prognostic implications because LVOT obstruction and LV mass are associated with negative outcomes in patients with HCM. In addition, they have important implications for the understanding of the pathophysiology of disease, its response to various interventions which could therefore help further refinement of management.

Author Contributions

Conceived and designed the study: IEH, IO, FC, MHY; Performed the studies: LR; Analyzed the data: IEH, KL, AEG, RM, GZY; Interpreted the data: IEH, GZY, IO, FC, MHY; Wrote the manuscript: IEH, IO, FC, MHY.

Funding

Funding for the study was obtained from the Magdi Yacoub Institute.

Competing interests

None

References

- [1] Maron BJ. Hypertrophic cardiomyopathy: a systematic review. *JAMA*. 2002;287:1308–1320.
- [2] Olivotto I, Girolami F and Nistri S et al. The many faces of hypertrophic cardiomyopathy: from developmental biology to clinical practice. *Journal of Cardiovascular Translational Research*. 2009;2:392–397.
- [3] Moon JC, Fisher NG and McKenna WJ et al. Detection of apical hypertrophic cardiomyopathy by cardiovascular magnetic resonance in patients with non-diagnostic echocardiography. *Heart*. 2004;90:645–649.
- [4] Olivotto I, Maron MS and Autore C et al. Assessment and significance of left ventricular mass by cardiovascular magnetic resonance in hypertrophic cardiomyopathy. *J Am Coll Cardiol*. 2008;52:559–566.
- [5] Yacoub MH, El-Hamamsy I and Said K et al. The left ventricular outflow in hypertrophic cardiomyopathy: from structure to function. *Journal of Cardiovascular Translational Research*. 2009;2:510–517.
- [6] Maron MS, Olivotto I and Zenovich AG et al. Hypertrophic cardiomyopathy is predominantly a disease of left ventricular outflow tract obstruction. *Circulation*. 2006;114:2232–2239.
- [7] Maron MS, Olivotto I and Betocchi S et al. Effect of left ventricular outflow tract obstruction on clinical outcome in hypertrophic cardiomyopathy. *N Engl J Med*. 2003;348:295–303.

- [8] Binder J, Ommen SR and Gersh BJ et al. Echocardiography-guided genetic testing in hypertrophic cardiomyopathy: septal morphological features predict the presence of myofilament mutations. *Mayo Clin Proc.* 2006;81:459–467.
- [9] Rickers C, Wilke NM and Jerosch-Herold M et al. Utility of Cardiac Magnetic Resonance Imaging in the Diagnosis of Hypertrophic Cardiomyopathy. *Circulation.* 2005;112:855–861.
- [10] Spirito P, Bellone P and Harris KM et al. Magnitude of Left Ventricular Hypertrophy and Risk of Sudden Death in Hypertrophic Cardiomyopathy. *N Engl J Med.* 2000;342:1778–1785.
- [11] van Dockum WG, Beek AM and ten Cate FJ et al. Early onset and progression of left ventricular remodeling after alcohol septal ablation in hypertrophic obstructive cardiomyopathy. *Circulation.* 2005;111:2503–2508.
- [12] Kofflard MJ, van Herwerden LA and Waldstein DJ et al. Initial results of combined anterior mitral leaflet extension and myectomy in patients with obstructive hypertrophic cardiomyopathy. *J Am Coll Cardiol.* 1996;28:197–202.
- [13] McIntosh CL, Maron BJ and Cannon 3rd RO et al. Initial results of combined anterior mitral leaflet plication and ventricular septal myotomy-myectomy for relief of left ventricular outflow tract obstruction in patients with hypertrophic cardiomyopathy. *Circulation.* 1992;86:1160-7.
- [14] Cooley DA, Wukasz DC and Leachman RD. Mitral valve replacement for idiopathic hypertrophic subaortic stenosis. Results in 27 patients. *J Cardiovasc Surg (Torino).* 1976;17:380–387.
- [15] Dearani JA, Ommen SR and Gersh BJ et al. Surgery insight: Septal myectomy for obstructive hypertrophic cardiomyopathy—the Mayo Clinic experience. *Nat Clin Pract Cardiovasc Med.* 2007;4:503–512.
- [16] Sigwart U. Non-surgical myocardial reduction for hypertrophic obstructive cardiomyopathy. *Lancet.* 1995;346:211–214.
- [17] Yacoub MH. Surgical versus alcohol septal ablation for hypertrophic obstructive cardiomyopathy: the pendulum swings. *Circulation.* 2005;112:450–452.
- [18] Cerqueira MD, Weissman NJ and Dilsizian V et al. Standardized Myocardial Segmentation and Nomenclature for Tomographic Imaging of the Heart: A Statement for Healthcare Professionals From the Cardiac Imaging Committee of the Council on Clinical Cardiology of the American Heart Association. *Circulation.* 2002;105:539–542.
- [19] Myerson SG, Bellenger NG and Pennell DJ. Assessment of Left Ventricular Mass by Cardiovascular Magnetic Resonance. *Hypertension.* 2002;39:750–755.
- [20] Buakhamsri A, Popovic ZB and Lin J et al. Impact of left ventricular volume/mass ratio on diastolic function. *Eur Heart J.* 2009;30:1213–1221.
- [21] Hahn C and Schwartz MA. Mechanotransduction in vascular physiology and atherogenesis. *Nat Rev Mol Cell Biol.* 2009;10:53–62.
- [22] Cai C-L, Martin JC and Sun Y et al. A myocardial lineage derives from Tbx18 epicardial cells. *Nature.* 2008;454:104–108.
- [23] Zhou B, Ma Q and Rajagopal S et al. Epicardial progenitors contribute to the cardiomyocyte lineage in the developing heart. *Nature.* 2008;454:109–113.
- [24] Franco D, Meilhac SM and Christoffels VM et al. Left and right ventricular contributions to the formation of the interventricular septum in the mouse heart. *Developmental Biology.* 2006;294:366–375.
- [25] Lie-Venema H, van den Akker NMS and Bax NAM et al. Origin, Fate, and Function of Epicardium-Derived Cells (EPDCs) in Normal and Abnormal Cardiac Development. *The Scientific World Journal.* 2007;7:1777–1798.
- [26] Topouzis S and Majesky MW. Smooth muscle lineage diversity in the chick embryo. Two types of aortic smooth muscle cell differ in growth and receptor-mediated transcriptional responses to transforming growth factor-beta. *Dev Biol.* 1996;178:430–445.
- [27] Haimovici H and Maier N. Fate of Aortic Homografts in Canine Atherosclerosis. III. Study of Fresh Abdominal and Thoracic Aortic Implants Into Thoracic Aorta: Role of Tissue Susceptibility in Atherogenesis. *AMA Arch Surg.* 1964;89:961–969.
- [28] Thieszen SL, Dalton M and Gadson PF et al. Embryonic lineage of vascular smooth muscle cells determines responses to collagen matrices and integrin receptor expression. *Exp Cell Res.* 1996;227:135–145.
- [29] Monteiro PF, Ommen SR and Gersh BJ et al. Effects of Surgical Septal Myectomy on Left Ventricular Wall Thickness and Diastolic Filling. *The American Journal of Cardiology.* 2007;100:1776–1778.
- [30] Valeti US, Nishimura RA and Holmes DR et al. Comparison of Surgical Septal Myectomy and Alcohol Septal Ablation With Cardiac Magnetic Resonance Imaging in Patients With Hypertrophic Obstructive Cardiomyopathy. *Journal of the American College of Cardiology.* 2007;49:350–357.
- [31] De Castro S, Caselli S and Maron M et al. Left ventricular remodelling index (LVRi) in various pathophysiological conditions: a real-time three-dimensional echocardiographic study. *Heart.* 2007;93:205–209.