



UNIVERSITÀ
DEGLI STUDI
FIRENZE

FLORE

Repository istituzionale dell'Università degli Studi di Firenze

Patient with liver dysfunction while maintained on veno-venous extracorporeal membrane oxygenation should not be overlooked as a

Questa è la Versione finale referata (Post print/Accepted manuscript) della seguente pubblicazione:

Original Citation:

Patient with liver dysfunction while maintained on veno-venous extracorporeal membrane oxygenation should not be overlooked as a potential donor / Mourad M.M.; Reay M.; Muiesan P.; Mirza D.F.; Perera M.T.P.R.. - In: TRANSPLANT INTERNATIONAL. - ISSN 0934-0874. - ELETTRONICO. - 27:(2014), pp. e50-e53. [10.1111/tri.12290]

Availability:

This version is available at: 2158/1200032 since: 2020-07-07T09:37:38Z

Published version:

DOI: 10.1111/tri.12290

Terms of use:

Open Access

La pubblicazione è resa disponibile sotto le norme e i termini della licenza di deposito, secondo quanto stabilito dalla Policy per l'accesso aperto dell'Università degli Studi di Firenze (<https://www.sba.unifi.it/upload/policy-oa-2016-1.pdf>)

Publisher copyright claim:

(Article begins on next page)

CASE REPORT

Patient with liver dysfunction while maintained on veno-venous extracorporeal membrane oxygenation should not be overlooked as a potential donor

Moustafa M. Mourad, Michael Reay, Paolo Muiesan, Darius F. Mirza and M. Thamara P. R. Perera

The Liver Unit, Queen Elizabeth Hospital Birmingham, Edgbaston Birmingham, UK

Keywords

donor after circulatory death, extracorporeal membrane oxygenation, graft dysfunction, marginal donor.

Correspondence

Mr. Thamara Perera FRCS, The Liver Unit, Queen Elizabeth Hospital Birmingham, Edgbaston, Birmingham B15 2TH, UK.
Tel.: 0044 12137 14637;
fax: 0044 12141 41833; e-mail: thamara.perera@uhb.nhs.uk

Conflict of interest

The authors declare that they have no competing interests.

Received: 18 December 2013

Revision requested: 7 January 2014

Accepted: 17 February 2014

Published online: 1 April 2014

doi:10.1111/tri.12290

Introduction

Liver transplantation is superior to any other treatment for those with end-stage liver disease or primary liver tumours. Despite the increased transplant activity worldwide, shortage of donor organs remains a problem. Thus, surgeons have resorted to accept marginal donor organs in an attempt to increase the donor pool [1]. Liver dysfunction of donor is usually considered relative contraindication [2]; however, consideration of such grafts with caution allows expansion of donor pool without compromising post-transplant outcome. In the absence of universal acceptance criteria for donors with abnormal liver biochemistry, surgeons consider these by case-by-case basis [3]. One set laboratory data is usually not sufficient to predict the graft function, whereas 'trend' of such results provides a global picture of the donor suitability.

Summary

This report describes transplantation of liver allograft from a circulatory death donor who was supported by veno-venous extracorporeal membrane oxygenation (ECMO) for 14 days and presented with severely altered liver functions. Successful liver transplant was done in a patient with hepatocellular carcinoma (HCC) in the background of primary sclerosing cholangitis. There was immediate graft function and uneventful recovery with stable graft function at 1-year follow-up. This case illustrates the ability of veno-venous ECMO to resuscitate organs in the presence of severe dysfunction, and perhaps, lessons from this case may be incorporated to optimize the condition of organs rescued from these marginal donors and exemplify the use of ECMO in normothermic regional perfusion in donors after circulatory death.

The presented case herein is an example of a donor initially presented with highly abnormal organ function prior to the donation. This donor was deemed unsuitable by all other centres. Careful analysis of the donor history revealed improved liver biochemistry while the patient was managed on extracorporeal membrane oxygenation (ECMO) support. Through this manuscript, we aim to report the first case in the literature thus far on successful use of a liver graft from donors after circulatory death (DCD) donor maintained on veno-venous ECMO. This will be discussed in the background rationale for graft acceptance and recipient selection and successful outcomes. It is estimated that treatment is withdrawn in many patients maintained on ECMO annually in the UK and other countries although an exact figure is difficult to predict [4,5]. Careful selection may help utilize some of the organs from these donors and contribute to ease the pressure on transplant wait lists.

Case report

Donor history

A 35-year-old patient (54 kg, blood group O) with 2-year history of idiopathic pulmonary fibrosis and awaiting lung transplantation was admitted to the local hospital with recurrent pneumocystis pneumonia. Patient was appropriately treated with antibiotics, and on the 6th day of admission, patient developed acute respiratory failure secondary to underlying pulmonary fibrosis. This patient was commenced on veno-venous ECMO; meanwhile, cardiac arrest occurred on the 7th day of admission secondary to a pneumothorax. Although successfully resuscitated, the patient was deemed medically unsuitable for lung transplant. Further treatment was deemed futile. Patient was maintained on veno-venous ECMO until the option of organ donation was explored.

Subsequent to cardiac arrest, donor liver function showed high alanine aminotransferase (ALT) >3000 U/l, which progressively improved to 229 U/l the day before organ offering. Immediate preprocurement donor ALT, alkaline phosphatase and bilirubin were 97 U/l, 172 U/l and 20 μ M, respectively. Patient maintained core body temperature of 36.4 °C and oxygen saturation 99% through ECMO support. There was continuous infusion of inotropes. The organ offer was declined by other centres primarily due to liver dysfunction evident from laboratory results. When offered, careful review of the history and the laboratory data convinced us the improving liver function while the patient was on ECMO. The extracorporeal oxygenation was considered a reassurance; hence, the organ offer was accepted.

Donor treatment withdrawal entailed discontinuation of ECMO support, inotropes and extubation. Circulatory death ensued soon after treatment withdrawal, and the donor warm ischaemia time was 32 min. Organs were recovered in the modified super-rapid technique. University of Wisconsin (UW) solution was used for organ preservation. A soft, well-perfused liver graft was procured that showed normal anatomy, no steatosis or injuries. Graft weight was 1203 g.

Recipient

The unit adopts a policy of allocating high-risk organs to recipients without advanced liver disease. Thus, a 59-year-old patient with hepatocellular carcinoma in the background of primary sclerosing cholangitis was selected. The recipient operation was standard. Total cold ischaemia time was 06:15 hours. Implantation time was 28 min with total operative time of 05:40 hours. There was no evidence of postreperfusion syndrome during the reperfusion, and patient remained stable throughout the operation. No

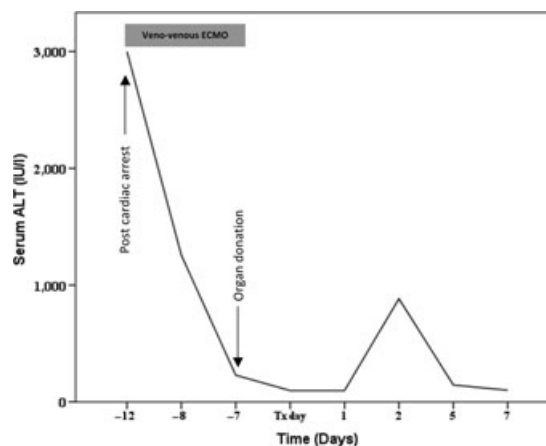


Figure 1 Trends of serum alanine aminotransferase (ALT) (predonation) and recipient serum ALT post-transplant.

packed red blood cell or plasma was given intraoperatively, and final haemoglobin at the time of closure was 9.8 g/dl. Immediate post-operative recovery was excellent. Aspartate transaminase and ALT peaked at 549 and 884 U/l, respectively, following transplantation (Fig. 1). He was diagnosed with acute cellular rejection on day 5 and successfully treated with pulsed steroids. All graft functions were normalized at 14 days following transplantation, and patient now completes 1 year with stable graft function.

Discussion

Shortage of donor organs has been largely contributed by expanding the criteria, and indications for transplantation and marginal grafts are widely used in this background. Through 'utilitarian approach' practised in our unit, ideal donor–recipient matching could be performed when marginal grafts are used. Blood group-O-recipients at present face fierce competition for organs, and current wait times for a deceased donor graft in the UK for such recipients is 199 days [6]. Nearly 20% of these drop out due to disease progression, tumour growth or medically unsuitable for transplantation [7]. Therefore, any blood group-O-donor could be considered a potential resource unless proven otherwise. The advantage of utilizing the marginal organs in a utilitarian approach is the less competition it creates for those remaining on the wait list when a suitable, ideal quality graft becomes available.

Use of liver grafts from donors with abnormal liver biochemistry is not a new concept. Liver grafts with altered liver functions offer survival chance for many patients and help reduce mortality and dropout on the waiting lists [8]. Of 388 liver transplant recipients who received grafts from extended criteria donors, 20.5% were from donors with raised liver function tests, yet outcomes were comparable

with standard donors [8]. Therefore, the previously considered relative contraindication to use grafts from those with abnormal liver biochemistry is currently revisited by many centres.

The successful use of liver graft from the donor presented herein is attributable to ECMO. Considerable period of artificial oxygenation allowed the ischaemic insult to the liver from cardiac arrest to recover. ECMO is generally used as arterio-venous ECMO for both cardiac and respiratory support or as veno-venous ECMO, which only support oxygenation of tissues [9]. It has been demonstrated that pulsatile blood flow was of considerable importance to hepatic and renal function with more efficient perfusion [10]. In this donor, ECMO maintained efficient perfusion and oxygenation of potentially transplantable organs.

Johnson *et al.* [11] reported first ever liver transplant from a donor who was maintained on veno-venous ECMO for 29 days, and this was a donation after brain death (DBD) where there was no warm ischaemia involved, and presented case is the first successful use of a liver graft from DCD donor maintained on veno-venous ECMO; predonation ECMO provided the reassurance to use this graft, and this decision was influenced by recent interest on application of ECMO as bridge to organ donation between asystole and procurement, reversing anaerobic metabolism mimicking a period of ischaemic preconditioning [12]. In a previously reported DCD donor, however, arterio-venous ECMO had been successfully used, albeit for a much shorter duration. ECMO permits the assessment of donor organs under nonischaemic conditions over a period of time through biochemical means, reflecting the ability of liver graft to recover from warm ischaemic injury in Maastricht category II DCD donors [13] (Table 1). This principle was recently introduced in the UK in Maastricht category III DCD donors by some groups, including

author's institution using a modified organ procurement protocol [19] in the form of regional perfusion involving abdominal compartment (normothermic regional perfusion – NRP). A recent systemic review consolidated the evidence for regional organ perfusion with ECMO of DCD organs from ischaemic injury and enables transplantation with acceptable survival [20]. Although NRP protocols recommend shorter period of organ perfusion than the longer use of ECMO in the presented case, the lessons from this case may probably help justify the use of NRP in DCD donors.

In summary, we present the first successful use of liver graft from a DCD donor with significantly altered biochemistry and maintained on veno-venous ECMO. Organ functions improved while maintained on ECMO prior to donation, and the clinical sequelae following transplantation was parallel with that of any standard liver transplant. In the era of organ shortage, consideration of those maintained on ECMO for a considerable time period before treatment is withdrawn may add few extra organs to the donor pool.

Authorship

MM: responsible for data collection. MM and MTPRP: case report design, prepared the manuscript. MTPRP: acceptance of donor and performing transplant. MR, PM, DFM and MTPRP: patient management, data interpretation and critical review of manuscript; all co-authors approved the final manuscript.

Funding

The investigators have not received any financial support for this case report. None of the authors has any potential conflicting financial interests relevant to this report.

Table 1. The use of ECMO in the different literatures to support liver grafts prior to organ harvest.

Timing of ECMO	Type of ECMO	Donor type	Number of cases	Outcomes
Prior to death (predonation)	Arterio-venous	DCD [14]	1	Excellent immediate function, 2-year follow-up
	Veno-venous	DBD [11]	1	Excellent immediate function, follow-up N/A
		DCD*	1	Excellent immediate function, 1-year follow-up
Post-mortem (postcardiac death)	Abdominal regional perfusion – (normothermic regional perfusion)	DCD (II)† [15]	34 (8.5%)‡	82% 1-year overall survival/70% 1-year graft survival
		DCD (II) [16]	20 (46.5%)	85% 1-year overall survival/80% 1-year graft survival
		DCD (II) [17]	14 (N/A)	71% 1-year overall survival/43% 1-year graft survival
		DCD (III)† [18]	12 (63%)	91% 1-year overall survival/91% 1-year graft survival

DCD, donors after circulatory death; ECMO, extracorporeal membrane oxygenation; N/A, not available.

*Presented case in this report.

†Maastricht category II and III DCD.

‡Percentage of successful liver graft procurement using ECMO in relation to the total number of potential donors.

Ethical

Not applicable.

References

1. Summers DM, Counter C, Johnson RJ, Murphy PG, Neuberger JM, Bradley JA. Is the increase in DCD organ donors in the United Kingdom contributing to a decline in DBD donors? *Transplantation* 2010; **90**: 1506.
2. Bernat JL, D'Alessandro AM, Port FK, *et al.* Report of a National Conference on Donation after cardiac death. *Am J Transplant* 2006; **6**: 281.
3. Goldaracena N, Quinonez E, Mendez P, *et al.* Extremely marginal liver grafts from deceased donors have outcome similar to ideal grafts. *Transpl Proc* 2012; **44**: 2219.
4. Skarda D, Barnhart D, Scaife E, Molitor M, Meyers R, Rollins M. Extracorporeal cardiopulmonary resuscitation (EC-CPR) for hypothermic arrest in children: is meaningful survival a reasonable expectation? *J Pediatr Surg* 2012; **47**: 2239.
5. Muralidharan R, Mateen FJ, Shinohara RT, Schears GJ, Wijidicks EF. The challenges with brain death determination in adult patients on extracorporeal membrane oxygenation. *Neurocrit Care* 2011; **14**: 423.
6. NHS Blood and Transplant. Transplant activity in the UK: activity report. 2012/2013. http://www.organdonation.nhs.uk/ukt/statistics/transplant_activity_report/current_activity_reports/ukt/activity_report_2012_13.pdf.
7. Hirschfield GM, Gibbs P, Griffiths WJ. Adult liver transplantation: what non-specialists need to know. *BMJ* 2009; **338**: b1670.
8. Tector AJ, Mangus RS, Chestovich P, *et al.* Use of extended criteria livers decreases wait time for liver transplantation without adversely impacting posttransplant survival. *Ann Surg* 2006; **244**: 439.
9. Health Quality O. Extracorporeal lung support technologies – bridge to recovery and bridge to lung transplantation in adult patients: an evidence-based analysis. *Ont Health Technol Assess Ser* 2010; **10**: 1.
10. Mori A, Watanabe K, Onoe M, *et al.* Regional blood flow in the liver, pancreas and kidney during pulsatile and nonpulsatile perfusion under profound hypothermia. *Jpn Circ J* 1988; **52**: 219.
11. Johnson LB, Plotkin JS, Howell CD, Njoku MJ, Kuo PC, Bartlett ST. Successful emergency transplantation of a liver allograft from a donor maintained on extracorporeal membrane oxygenation. *Transplantation* 1997; **63**: 910.
12. Amador A, Grande L, Marti J, *et al.* Ischemic pre-conditioning in deceased donor liver transplantation: a prospective randomized clinical trial. *Am J Transplant* 2007; **7**: 2180.
13. Wind J, Hoogland ER, van Heurn LW. Preservation techniques for donors after cardiac death kidneys. *Curr Opin Organ Transplant* 2011; **16**: 157.
14. Wang CC, Wang SH, Lin CC, *et al.* Liver transplantation from an uncontrolled non-heart-beating donor maintained on extracorporeal membrane oxygenation. *Transpl Proc* 2005; **37**: 4331.
15. Fondevila C, Hessheimer AJ, Flores E, *et al.* Applicability and results of Maastricht type 2 donation after cardiac death liver transplantation. *Am J Transplant* 2012; **12**: 162.
16. Jiménez-Galanes S, Meneu-Diaz MJC, Elola-Olaso AM, *et al.* Liver transplantation using uncontrolled non-heart-beating donors under normothermic extracorporeal membrane oxygenation. *Liver Transpl* 2009; **15**: 1110.
17. Otero A, Gómez-Gutiérrez M, Suárez F, *et al.* Liver transplantation from Maastricht category 2 non-heart-beating donors. *Transplantation* 2003; **76**: 1068.
18. Pelletier SJ, Hundley JC, Englesbe MJ, Rojas AP, Bartlett RH, Punch JD. Liver transplantation and ECMO-assisted donation after cardiac death [abstract]. *Am J Transplant* 2009; **9**(Suppl. 2): 263.
19. NHS Blood and Transplant. Liver Advisory Group. An update on Normothermic regional perfusion in DCD category III organ retrieval and organ transplantation. http://www.odt.nhs.uk/pdf/advisory_group_papers/KAG/Normothermic_regional_perfusion_in_DCD_category_III_organ_retrieval_and_organ_transplantation.pdf.
20. Shapey IM, Muiesan P. Regional perfusion by extracorporeal membrane oxygenation of abdominal organs from donors after circulatory death: a systematic review. *Liver Transpl* 2013; **19**: 1292.