



UNIVERSITÀ
DEGLI STUDI
FIRENZE

DOTTORATO DI RICERCA TOSCANO IN NEUROSCIENZE

CICLO XXXII

COORDINATORE Prof. Renato Corradetti

Ultrathin Descemet stripping automated endothelial keratoplasty versus Descemet membrane endothelial keratoplasty: a fellow-eye comparison

Settore Scientifico Disciplinare MED/30

Dottorando

Dott. Favuzza Eleonora

Tutore

Prof. Virgili Gianni

Coordinatore

Prof. Corradetti Renato

Anni 2016/2019

1. INTRODUCTION	
1.1. Anatomy and physiology of the corneal endothelium	2
1.2. The dysfunctions of the corneal endothelium	4
1.3. Endothelial keratoplasty: DSAEK, UT-DSAEK, NT-DSAEK and DMEK	7
1.4. Endothelial keratoplasty: visual outcomes	9
2. AIM OF THE STUDY	11
3. METHODS	12
<i>3.1. Patients and evaluations</i>	12
<i>3.2. Surgical techniques</i>	14
<i>3.3. Statistical analysis</i>	16
4. RESULTS	17
<i>4.1. Postoperative visual acuity, refraction and endothelial cell density</i>	18
<i>4.2. Corneal aberrations</i>	20
<i>4.3. Correlations between postoperative BCVA and corneal aberrations</i>	22
<i>4.4. Contrast sensitivity</i>	24
<i>4.5. Satisfaction questionnaire</i>	26
5. DISCUSSION	27
6. REFERENCES	32

1. INTRODUCTION

1.1. Anatomy and physiology of the corneal endothelium

The cornea is a critical component of the eye for vision as it is the main determinant of the optical power of the eye (approximately 70%) and it constitutes a clear window so that light rays reach the retina. (Ayres et al. 2006, Stuart et al. 2018).

It is composed of five layers from the outer to the inner surface: the epithelium, Bowman's membrane, the stroma, Descemet's membrane and the endothelium.

The endothelium consists of a thin (4 μm) monolayer of confluent hexagonal endothelial cells which adhere strongly to their basal membrane, Descemet's membrane, and it covers the whole corneal posterior surface evenly, up to the trabecular meshwork in the iridocorneal angle.

The endothelial cells, which derive from the embryonal neural crest, play a critical role in maintaining the transparency of the cornea, which is of the utmost importance in order to provide a clear visual image. The corneal endothelium in fact controls the movement of water and ions across the hydrophilic stroma and pumps fluid out of the cornea, keeping it in a relatively dehydrated state (78% water content). This preserves the regular spacing of the stromal collagen fibers, which is crucial for tissue transparency. This hydric balance is guaranteed through a double mechanism, known as the "pump/leak" mechanism (Bonanno 2012), where the active transport properties of the endothelium represent the "pump" and the stromal swelling pressure represents the "leak". The "leak" is thought to be caused by the swelling pressure (~60 mmHg) exerted by molecular repulsion from the highly negatively charged stromal glycosaminoglycans (GAGs) and by the possible focal discontinuities in the inter-cellular tight junctions: consequently, the bare stroma can swell to many times its normal thickness, the spacing between fibers becomes non-uniform, light scatter

increases, and corneal transparency is lost. This tendency to swell is counteracted by the endothelial pump through the membrane active transport mechanisms which consist in Na^+/K^+ ATPase and carbonic anhydrase. The balance is thus reached when the endothelial pump rate equals the GAG-driven leak. Due to the presence of the continuous leak, loss of endothelial ion transport activity leads to corneal edema, loss of transparency, and impaired vision. (Bonanno 2012).

Moreover, the corneal endothelium maintains the nutrition of the corneal cells: except for oxygen, all the nutrients for the cornea come from the aqueous humor and through the endothelium. Glucose transporters are present on both the apical and basolateral endothelial cell membranes to allow transcellular glucose flux (Bonanno 2012).

At birth, the central endothelial cell density (ECD) reaches the maximum, 6000 cells/ mm^2 , then it falls slowly during infancy at a rate of 0.6% per year; the average healthy adult cornea has approximately 2500 to 2700 cells/ mm^2 .

This number physiologically falls slowly with age but rarely it results in corneal endothelial failure, because endothelial cells move and enlarge to maintain confluency (Smolin et al. 1994). Conversely, when, as a result of disease or damage, the number of cells falls below a critical level of around 300 to 500 cells/ mm^2 , corneal endothelial failure occurs, resulting in corneal edema and loss of vision (Smolin et al. 1994).

Joyce et al. (Joyce et al. 1996) proved that the endothelial cells of the human cornea in vivo are stuck in the G1 phase of the cell-cycle and express factors that down-regulate the cell-cycle and belong to the CIP/KIP family (p21 and p27), to the INK4 family (p16, p15 and p19) and to the p53 protein family (p53, Tap63). The inhibition of the cell mitosis also seems to be caused by the presence in the aqueous humor of

the Transforming Growth Factor beta (TGF- β), by the contact inhibition of the confluent endothelial cells and by the early senescence induced by cellular stress mechanisms (Joyce et al. 1996). Nevertheless, some studies have suggested the possibility of a corneal endothelial regeneration both in vivo and in vitro (Van den Bogerd et al. 2018, Okumura et al. 2011, Okumura et al. 2012). In vivo the regeneration seems to be limited to the peripheral endothelium, as proved by the centripetal migration of the endothelial cells from the periphery of recipient corneas after full-thickness corneal transplants, and by the longer survival of posterior lamellar grafts in patients with high peripheral ECD (Van der Bogerd et al. 2018). In in vitro and in vivo models, the proliferation and regeneration of endothelial cells have been observed after the administration of Rho-kinases (ROCK) inhibitors, which can release the endothelial cells and allow them to complete the cell cycle (Okumura et al. 2011, Okumura et al. 2012).

1.2. The dysfunctions of the corneal endothelium

The leading causes of corneal endothelial dysfunction or failure are Fuchs' endothelial dystrophy (FED) and pseudophakic bullous keratopathy (PBK). (Boimer et al. 2011; Frigo et al. 2015)

Fuchs' endothelial dystrophy, a condition first described by Ernst Fuchs in 1910, is a premature degeneration of corneal endothelial cells characterized by the presence of "guttae" of Descemet's membrane, and in later phases by corneal edema. (Fuchs 2010) It commonly affects individuals in the fifth and sixth decade of life (Afshari et al. 2006), usually both eyes although at its onset it is typically asymmetrical. FED occurs more commonly in women than men and can be inherited in an autosomal

dominant fashion, although not all cases are familiar (Cross et al. 1971). The condition is progressive and irreversible.

All layers of the cornea may be affected by FED, either primary or secondary to corneal edema. The primary changes include reduction of endothelial cell density and alteration of endothelial morphology. (Figure 1) Thickening of Descemet's membrane occurs, with the addition of collagenous layers and formation of excrescences called guttae (Zhang & Patel 2015).




Figure 1: *Left image: specular microscopy of a normal corneal endothelium; middle and right images: endothelium of two patients affected by Fuchs' endothelial dystrophy at different stages.*

Changes secondary to corneal edema include the formation of epithelial bullae and sub-epithelial fibroblast and collagen infiltration, reduction of sub-basal corneal nerve density, reduced anterior keratocyte density and fibroblastic transformation of stressed keratocytes in the stroma (Zhang & Patel 2015).

The disease has often been categorized in stages involving the presence of guttae without edema, the presence of guttae with stromal or epithelial edema, and corneal scarring or neovascularization caused by chronic edema (Wilson & Bourne 1988). Adamis et al. (Adamis et al., 1993) described four clinical stages: in stage 1 guttae are present in the central cornea, but visual acuity is not affected as the remaining endothelial cells can undergo polymegathism and compensate for endothelial cell loss; in stage 2 corneal endothelial cells become thinner, enlarged and reduced in number, along with a confluence of guttae extending towards the peripheral cornea; mild corneal stromal edema and painless reduction in vision is observed. In stage 3 the severity of corneal stromal edema increases and is associated with epithelial and sub-epithelial bullae, and painful loss of vision. In stage 4 severe edema is associated with opacification and vascularization of the cornea, but pain subsides.

Although visual acuity may not be affected in the early stage, when guttae are the only detectable abnormalities, some patients report visual difficulties as their visual quality may be strongly impaired. This has become more evident in the last few years, as recent technology advances have permitted the quantitative measurement of guttae and quality of vision. Specifically, intraocular forward light scatter, referred to as straylight, and anterior and posterior corneal high-order aberrations (HOAs) and backscatter (related to anterior corneal haze) have been reported to be higher than normal in the early stage of FED (Watanabe et al. 2015, Wacker et al. 2015)

PBK refers to the loss of endothelial cells during cataract surgery. This may occur because of direct trauma to endothelial cells during the cataract procedure, or indirectly due to the effects of inflammation or high intraocular pressure that can occur following cataract surgery. Therefore, contrary to FED, it is typically unilateral. (Stuart 2018, Claesson et al. 2009).

1.3. Endothelial keratoplasty: DSAEK, UT-DSAEK, NT-DSAEK and DMEK

The treatment for corneal endothelial failure varies according to the severity of the disease and may range from hypertonic saline drops to surgical intervention. In moderate or severe disease, corneal transplantation may be required for visual rehabilitation (Stuart et al. 2018).

Previously, the gold standard corneal grafting technique for endothelial failure was the full-thickness grafting of the cornea, penetrating keratoplasty (PK) (Hamzaoglu et al. 2015). However, in the past decade endothelial keratoplasty (EK), the selective replacement of the innermost layer of the cornea, has become the gold standard for the treatment of endothelial dysfunctions (Boimer et al. 2011; Frigo et al. 2015).

The expected benefits of EK techniques over PK are faster visual recovery, more predictable refractive outcome due to less astigmatism, and stronger wound integrity (Terry et al. 2001, Lee et al. 2009). Moreover, theoretically, with EK there is also less risk of immune rejection of the transplanted corneal tissue, which is an important reason for failure in PK patients (Pineros et al. 1996): possible reasons may be that a smaller amount of tissue is transplanted and that the endothelium is located in what is normally an immune-privileged location. Various subtypes of EK have been described but the most commonly performed are:

- DSAEK ((Descemet-Stripping Automated Endothelial Keratoplasty), first described in 2006 by Mark Gorovoy (Gorovoy et al. 2006): the transplanted graft, cut by a microkeratome from the donor cornea, is composed of a portion of posterior corneal stroma of variable thickness, Descemet's membrane and endothelial cells, and it may be from 50 up to 150 microns thick. Due to the higher demand of DSAEK grafts and thanks to the refinement and standardization of the graft cutting techniques (Romano et al. 2017, Cheung et al. 2018, Busin et

al. 2013), nowadays eye banks are providing surgeons with thinner grafts, often thinner than 130 μm or even 100 μm (ultrathin, UT) or 50 μm (nanothin, NT) (Cheung et al. 2018, Kurji et al. 2018). (Figure 2)

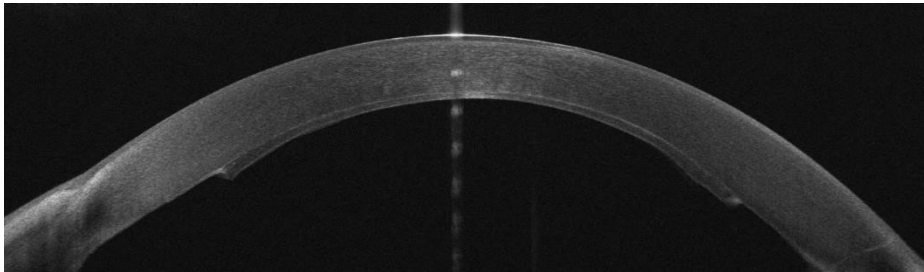


Figure 2: Corneal optical coherence tomography 2 weeks after UT-DSAEK (graft central thickness= 60 microns)

- DMEK (Descemet Membrane Endothelial Keratoplasty), pioneered by Gerrit Melles (Melles et al, 2006): a thin sheet (around 15-20 μm) composed of only Descemet's membrane and endothelium is stripped from the donor cornea and transplanted. (Figure 3)

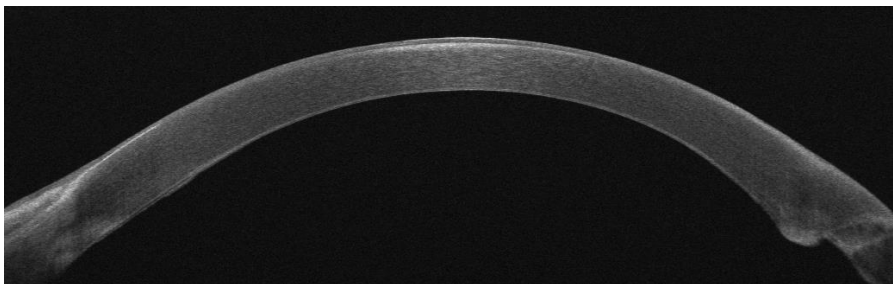


Figure 3: Corneal optical coherence tomography 2 weeks after DMEK

Due to its quicker postoperative recovery and similar or better visual outcome and lower rejection rates, DMEK has rapidly gained popularity, even though its widespread adoption is still limited by the difficult and less predictable surgical technique that prevents its use in complicated cases, and by its higher rates of

postoperative rebubbling (Cheung et al. 2018, Dickman et al. 2016, Stuart et al. 2018). The more difficult surgical handling of the graft may induce or accelerate long-term endothelial cell loss, possibly increasing the rate of late graft failure (Cheung et al. 2018, Dickman et al. 2016, Stuart et al. 2018).

1.4. Endothelial keratoplasty: visual outcomes

Several studies suggest that visual acuity after DMEK may be better than after DSAEK (Marques et al. 2018, Pavlovich et al. 2017, Singh et al. 2017, Zhu et al. 2018, Hamzaoglu et al. 2015, Droutsas et al. 2018, Stuart et al. 2018); nevertheless, to the best of our knowledge, the majority of published studies and metaanalysis comparing DSAEK and DMEK outcomes take into consideration only DSAEK grafts which are thicker than 130 μm .

Even though the debate on the relationship between graft thickness and DSAEK visual outcome is still ongoing and based on contradictory results (Busin & Albè 2014, Terry et al. 2012), Neff et al. (Neff et al. 2011) were the first to suggest that DSAEK grafts thinner than 130 μm (ultrathin, UT-DSAEK) may lead to postoperative visual outcomes which are better than conventional DSAEK and comparable to DMEK. These outcomes were further supported by a large interventional case series (Busin et al. 2013) and by a recent randomized controlled clinical trial (Dickman et al. 2016). The increasing availability of UT grafts have led to a randomized controlled clinical study (Chamberlain et al. 2019) which by contrast found a higher visual outcome after DMEK compared to UT-DSAEK.

It has been highlighted that the visual performance of patients undergoing EK can be influenced by multiple factors other than the graft thickness alone, e.g. the graft thickness uniformity, parallelism and irregularities of the host-donor interface, high-

order aberrations (HoA), haze-related light reflection phenomena and anterior corneal changes related to the duration of the disease (Turnbull et al. 2016, Hayashi et al. 2017).

Regarding the conflicting results concerning the impact of graft thickness on visual acuity, it may not be the graft thickness or total corneal thickness per se that influences vision, but rather the degree of parallelism between the graft and the recipient cornea. This is likely to be influenced indirectly by graft thickness, as thinner grafts have been found to have fewer irregularities than thick grafts and more faithfully replicate the normal corneal anatomy (Turnbull et al., 2016).

It has also been suggested that the nature of the interface may influence visual performance after EK: according to the proposed theories, a stroma-stroma interface (e.g. DSAEK interface) might be inferior to the more “anatomically correct” Descemet’s membrane-stroma interface of DMEK, due to the convergence of host and donor stromal fibers of different orientation, and differences in refractive index. However, evidence showing that “ultrathin” DSAEK is able to emulate the results of DMEK suggests that the stroma-stroma interface may not be a limiting factor. (Turnbull et al. 2016)

Unlike the lower-order aberrations (defocus and astigmatism), higher-order aberrations (HOAs) cannot be accurately corrected with current optical treatment: even though they account for 10% of the overall aberration in the eye, they can significantly impair visual performance. It is known that HOAs have a greater impact on low-contrast visual acuity and contrast sensitivity than high-contrast visual acuity. (Turnbull et al. 2016) Anterior corneal high-order aberrations have been found to be higher after DSAEK than in age-matched controls, and they have been related both to the surgical incision (though they cause minimal disruption of the anterior surface)

and more importantly to the changes in the anterior stroma induced by the underlying disease. Chronic stromal edema and subepithelial fibrosis induced by Fuchs' corneal dystrophy can indeed induce anterior HOAs, subepithelial haze and backscattering that may persist despite successful EK. Although EK involves greater manipulation of the posterior than the anterior cornea, it is widely suggested that the anterior cornea is the key determinant of visual outcome. (Turnbull et al, 2016). These concepts have led to the theory that earlier surgery may produce better visual outcomes by limiting the duration of stromal edema and reducing fibrosis, but no consensus has yet been reached. (Turnbull et al, 2016).

Posterior corneal HOAs increase after all techniques of EK compared with normal controls, and in DSAEK they may be secondary to graft decentration, differences in curvature between the recipient and the graft, or uneven graft thickness from asymmetric trephination. Although several studies have failed to find a strong association between posterior corneal HOAs and postoperative BCVA, the impact of the posterior corneal surface on visual outcomes should not be ignored. (Turnbull et al, 2016).

As visual acuity is an important component of visual quality, but quality of vision can also be impaired by several other factors, in order to better assess visual performance after EK other parameters such as anterior and posterior corneal aberrations and contrast sensitivity need to be evaluated.

2. AIM OF THE STUDY

In this context, the aim of our study was to retrospectively compare the visual outcomes, contrast sensitivity, corneal keratometry and aberrations, endothelial cell

density (ECD) and satisfaction in patients affected by Fuchs endothelial dystrophy who underwent UT-DSAEK in one eye and DMEK in the fellow eye.

We chose to perform an intra-patient comparison because it can help to highlight the differences between the two techniques, by limiting confounding factors which may be due to interindividual variability.

3. METHODS

3.1. Patients and evaluations

In this retrospective study the records of 18 pseudophakic patients (implanted with a spherical monofocal hydrophobic acrylic IOL, SA60AT, Alcon, Fort Worth, Texas, USA) affected by Fuchs endothelial dystrophy who underwent DMEK in one eye and UT-DSAEK in the fellow eye were reviewed.

All surgical procedures were performed by the same experienced surgeon (R.M.) between January 2015 and June 2017. The procedures were carried out at the Eye Clinic, Department of Neuroscience, Psychology, Pharmacology and Child Health (NEUROFARBA), University of Florence.

Only patients who had at least 12 months of postoperative follow-up were included. In all patients DSAEK was performed in the first eye and DMEK in the second eye: the first eye was operated when the surgeon (R.M.) had limited experience with DMEK and preferred UT-DSAEK, the second eye when she became more confident in this new technique and started to perform DMEK in all uncomplicated cases.

One patient which experienced severe postoperative complications after DMEK (pupillary block and total graft detachment, corneal decompensation that didn't recover after air injection and was successfully managed with UT-DSAEK graft

implantation) was excluded. Two patients affected by severe macular degeneration with low visual potential were also excluded.

This retrospective observational study was conducted in compliance with the tenets of the Declaration of Helsinki. All patients were informed about the study and provided consent.

At the preoperative visit best-corrected visual acuity (BCVA, logMAR), slit-lamp examination, applanation tonometry (Goldmann applanation tonometer, Haag Streit, Bern, Switzerland), ocular fundus examination, endothelial cell density (Perseus, CSO, Italy) and corneal pachymetry (Sirius tomographer, CSO, Italy) were performed.

The patients were examined at 1 and 10 days and at 1,3, 6, 12 months after surgery. At the 12-month visit, in addition to the previously mentioned measurements, corneal aberrations at 4 and 6-mm optical zones (Sirius, CSO, Italy), graft thickness (spectral-domain anterior-segment Optical Coherence Tomography, RT-Vue OCT, Optovue Inc., Fremont, CA, USA) and contrast sensitivity were measured.

Graft thickness was measured using AS-OCT on a horizontal cross-sectional image obtained at the anterior corneal vertex, using the software-imbedded tool. Central thickness of the graft was measured at the corneal vertex, the peripheral thickness at the temporal and nasal sides at a distance of 3 mm from the vertex. The mean of the temporal and nasal thickness for each patient was then recorded.

Distance contrast sensitivity was analysed under photopic and mesopic conditions (85 and 3 cd/m respectively) using the Optec 6500 Vision Tester (Stereo Optical Co., Inc., Chicago, USA). The stimuli imply linear sine-wave grating charts of 1.5, 3, 6, 12 and 18 cpd (cycles per degree) in nine circular patches arranged in two rows (five patches above, four patches below). For each spatial frequency sine-wave gratings in

0.15 log CS decrements were presented at six spatial frequencies (A, 1.5 cycles per degree, cpd; B, 3 cpd; C, 6 cpd; D, 12 cpd; E, 18 cpd). The obtained results were compared to the physiologic contrast sensitivity range of the measuring device for normal patients of a similar age (Hohberger et al. 2007).

A questionnaire grading the patient's satisfaction with surgery for right and left eye on a scale of 1-6 including the following questions was administered at the last follow up visit (Goldich et al. 2015, slightly modified):

- 1) How is your vision? (1= very bad, 2 = bad, 3 = fine, 4 = good, 5 = very good, 6 = excellent)
- 2) Compare the post-operative period for the respective eye in terms of comfort. (1= very comfortable, 6= very uncomfortable)
- 3) How long did it take to resume normal activities (i.e., back to work)?
- 4) Please rate your level of satisfaction from surgery (1 = least satisfied, 6 = most satisfied);
- 5) Having undergone the 2 types of surgery, if given a choice, which one would you prefer?

Demographic characteristics, preoperative BCVA and corneal pachymetry, donor and graft characteristics and the aforementioned 12-month postoperative parameters were reviewed and analysed for this retrospective study.

3.2. *Surgical techniques*

All procedures were performed under monitored anesthesia with peribulbar block. Posterior lamellar grafts were supplied by the Eye bank of Lucca (Italy), after being cut by a microkeratome with a 350- μ m head (Moria SA, Antony, France) (DSAEK grafts) or being stripped and placed on their sclerocorneal support (DMEK grafts).

They were trephined by the surgeon to the desired diameter using a Hessburg-Barron donor corneal punch (Barron Precision Instruments, LLC, Grand Blanc, Michigan USA); DMEK grafts were left on their natural support immersed in 0.06% trypan blue dye (Vision blue; D.O.R.C). All grafts had an endothelial cell count of at least 2500 cells/mm². The graft thickness provided by the Bank was recorded.

The epithelium of the recipient was marked with a trephine in order to guide the subsequent descemetorhexis and to allow the correct positioning and perfect centering of the transplanted donor flap. The anterior chamber (AC) of the eye was then entered through a clear corneal incision, and an anterior chamber maintainer (ACM) was used in order to prevent an anterior chamber collapse.

The endothelium and the Descemet membrane were stripped from the central 8.5-9 mm diameter using the inverted Price-Sinsky hook, along the epithelial reference line for about 45 ° or 90°. The removed flap was exposed on the anterior surface of the receiver's cornea to verify its integrity.

In DSAEK surgery, the rolled donor's endothelial graft was inserted using a Busin glide through a 4-mm clear corneal incision (Moria Inc, Antony, France) and a small air bubble was injected to lift the graft. After centering the graft, the anterior chamber was completely filled with an air bubble to allow the perfect adherence of the donor flap to the receiving tissue (Mencucci et al. 2015).

DMEK surgery was performed following the "no-touch" technique. The trephined DMEK graft was carefully detached from the surrounding DM, immersed in sterile balanced salt solution—and aspirated into the transparent glass cartridge of a specific injector (E. Janach S.R.L., Como, Italy). The rolled graft was injected into the AC with slow and continuous pressure through the main incision (about 3 mm). Then the graft was unfolded and positioned using the Tap-tap technique and Dirisamer

technique, and after ensuring the correct orientation and centration it was pressed against the recipient stroma by injecting air underneath.

Patients were instructed to keep a supine position after surgery until the air in the AC was completely reabsorbed. Then in the case of a pupillary block or ocular hypertension a small quantity of air was released using a slit lamp. The postoperative treatment was in both groups a topical antibiotic 4 times a day for the first three weeks, and dexamethasone eye drops 4 times a day for the first month. Then the topical steroid was tapered down to one drop every other day during a 1-year period.

3.3. *Statistical analysis*

Data are presented as mean \pm standard deviation (SD).

After the normality of distribution of values within each data set of continuous variables had been checked with the Kolmogorov-Smirnov test, either paired 2-tailed Student t test (parametric) or the Wilcoxon signed rank test (non-parametric) were used to assess differences. Correlations between BCVA and corneal aberrations were analysed by Spearman's test.

In order to make inference on the differences in contrast sensitivity (CS) between DMEK and DSAEK, we fitted a single statistical model using random effects linear mixed modelling with CS as a response variable and procedure type and contrast frequency as covariates, in which we tested for interaction between procedure type and, separately, light conditions and frequency. We fitted separate models for the photopic and mesopic conditions. Analyses were performed using SPSS and Stata 14.1 software (StataCorp, College Station, TX). Values of $p < 0.05$ were considered as statistically significant.

4. RESULTS

In this study we included 36 eyes of 18 pseudophakic patients (16 female and 2 male) affected by bilateral Fuchs dystrophy, with a mean age of 73.5 ± 7.93 years. Patients underwent UT-DSAEK in one eye and after an average of 6 months (6.3 ± 1.2 months) DMEK in their fellow eye.

The preoperative characteristics of patients are shown in Table 1. The differences between the two groups in preoperative BCVA (log MAR) ($p=0.10$) and preoperative pachymetry (μm) ($p=0.14$) were not statistically significant. Table 1 also reports donor and graft characteristics in both groups. The preoperative mean thickness of the UT-DSAEK graft was $80.33 \pm 20.52 \mu\text{m}$. The mean age of donors, the endothelial cell count (measured by the eye bank after tissue processing) and the diameter of the graft were not significantly different.

No patient showed iris damage or had undergone previous ocular surgery other than uncomplicated phacoemulsification with posterior chamber IOL implantation or had very deep anterior chamber in either eye.

One eye in the DSAEK group and three eyes in the DMEK group experienced early postoperative peripheral partial graft detachment, which was successfully managed with air injection in the anterior chamber within one week from surgery. No intraocular pressure rise or graft failures or rejections were observed in this retrospective study. No patients were reported to have significant posterior capsular opacification.

Table 1. Preoperative characteristics of patients and of the transplanted grafts

	UT-DSAEK	DMEK	p
Preoperative BCVA (log MAR)	0.60±0.29	0.51±0.11	0.10
Preoperative pachymetry (µm)	618.78±39.41	629.28±38.64	0.14
Donor age (y)	67.17±6.27	69.56±9.82	0.45
Graft ECD (cell/mm²)	2700.00±59.41	2625.56±124.58	0.06
Graft central thickness (µm)	80.33±20.52		
Diameter of the graft (µm)	7.99±0.18	7.88±0.13	0.10

P value was assessed by the paired-*t* test for BCVA, pachymetry and donor age, by Wilcoxon signed rank test (non-parametric) for graft ECD and diameter. UT-DSAEK: Ultra-thin Descemet Stripping Automated Endothelial keratoplasty; DMEK Descemet membrane endothelial keratoplasty; BCVA: Best Corrected Visual Acuity; logMAR: logarithm of the minimal angle of resolution; µm: micrometers; y: years; ECD: endothelial cell density. Data are presented as mean ± standard deviation (SD).

4.1. Postoperative visual acuity, refraction and endothelial cell density

BCVA was significantly improved 12 months after UT-DSAEK and DMEK ($p < 0.001$ and $p < 0.001$ respectively, Wilcoxon signed rank test) without any statistically significant difference between the two groups ($p = 0.24$, Wilcoxon signed rank test, Table 2). Using a paired *t*-test, a difference of 0.023 logMAR (about 1 letter) favouring DMEK was found, but clinically important differences (2.5 letters or more) were unlikely (95%CI: -0.003 to 0.049, $p = 0.07$). The objective and subjective refraction and the spherical equivalent did not significantly differ between UT-DSAEK and DMEK eyes, except for the objective sphere which was significantly lower after DMEK ($p < 0.001$). The keratometric values evaluated by the Sirius Tomographer (CSO, Italy) were not significantly different between groups.

The endothelial cell density after the 12-month follow-up was similar, although

slightly higher in the UT-DSAEK group ($p=0.10$) and as expected the corneal thickness was lower ($p<0.001$) in the DMEK group (Table 2).

Table 2. Postoperative results at the 12-month follow-up after UT-DSAEK and DMEK

	UT-DSAEK	DMEK	p
BCVA (logMAR)	0.10±0.04	0.07±0.07	0.24
Objective sphere (D)	0.92±0.40	0.56±0.17	0.001**
Objective cylinder (D)	-1.12±0.55	-1.00±0.34	0.45
Subjective sphere (D)	0.56±0.47	0.29±0.25	0.07
Subjective cylinder (D)	-0.62±0.67	-0.62±0.52	0.82
Spherical Equivalent (SE)	0.25±0.39	-0.01±0.33	0.07
Sim K1 (D)	43.42±0.67	43.51±0.96	0.14
Sim K2 (D)	44.39±0.85	44.30±0.97	0.77
Avg (D)	43.90±0.75	43.91±0.95	0.67
Cyl tot (D)	-0.98±0.27	-0.79±0.30	0.11
Corneal pachymetry (µm)	570.38±21.96	516.29±33.52	<0.001**
Graft central thickness (µm)	77.85±22.02		
Graft peripheral thickness(µm)	107.46±28.32		
ECD (cell/mm²)	1772.62 ±185.59	1590.94±136.87	0.10

P value was assessed by the Wilcoxon signed rank test (non-parametric); UT-DSAEK: Ultra-thin Descemet Stripping Automated Endothelial keratoplasty; DMEK Descemet membrane endothelial keratoplasty; BCVA: Best Corrected Visual Acuity; logMAR: logarithm of the minimal angle of resolution; µm: micrometers; SIMK: K-value of simulated keratometry; D: diopters; Avg: average; Cyl: cylinder; D: diopters; ECD: endothelial cell density. Data are presented as mean ± standard deviation (SD). **= $p<0.01$

4.2. Corneal aberrations

Tables 3 and 4 present postoperative corneal aberrations as evaluated by the Sirius Tomographer. total and posterior corneal higher order aberrations (HOAs), posterior astigmatism and total coma were significantly lower after DMEK than UT-DSAEK at both 4- and 6-mm optical zones. The posterior coma was significantly lower in DMEK only at the 4-mm optical zone. The total and anterior corneal astigmatism were significantly lower in the DMEK group only at the 6-mm optical zone. The spherical aberration was similar between groups.

Table 3. Corneal aberrations at a 4-mm optical zone 12 months after surgery

	UT-DSAEK	DMEK	p
HOAs total	0.38±0.09	0.29±0.10	0.01*
HOAs front	0.27±0.08	0.25±0.09	0.89
HOAs back	0.24±0.13	0.13±0.04	0.001**
Astigmatism total	0.45±0.26	0.41±0.17	0.97
Astigmatism front	0.40±0.15	0.35±0.14	0.23
Astigmatism back	0.22±0.07	0.16±0.06	0.01*
Coma total	0.28±0.06	0.20±0.07	<0.001**
Coma front	0.20±0.06	0.16±0.06	0.20
Coma back	0.12±0.08	0.05±0.02	0.003**
Spherical aberration total	0.07±0.04	0.05±0.03	0.16
Spherical aberration front	0.07±0.04	0.06±0.02	0.40
Spherical aberration back	0.04±0.03	0.02±0.01	0.18

P value was assessed by the Wilcoxon signed rank test (non-parametric); UT-DSAEK: Ultra-thin Descemet Stripping Automated Endothelial keratoplasty; DMEK Descemet membrane endothelial keratoplasty; HoAs: High-order aberrations; *= $p < 0.05$; **= $p < 0.01$. Data are presented as mean ± standard deviation (SD). All values are in micrometers.

Table 4. Corneal aberrations at a 6-mm optical zone 12 months after surgery

	UT-DSAEK	DMEK	p
HOAs tot	0.88±0.20	0.58±0.15	<0.001**
HOAs front	0.76±0.16	0.63±0.19	0.11
HOAs back	0.43±0.16	0.23±0.07	<0.001**
Astigmatism total	1.08±0.43	0.63±0.34	0.003**
Astigmatism front	0.95±0.27	0.62±0.24	0.005**
Astigmatism back	0.41±0.17	0.20±0.11	<0.001**
Coma total	0.55±0.10	0.45±0.26	0.04*
Coma front	0.44±0.16	0.45±0.24	0.87
Coma back	0.20±0.13	0.14±0.10	0.06
Spherical aberration total	0.24±0.14	0.24±0.06	0.87
Spherical aberration front	0.26±0.08	0.25±0.04	0.89
Spherical aberration back	0.09±0.07	0.18±0.28	0.76

P value was assessed by the Wilcoxon signed rank test (non parametric); UT-DSAEK: Ultrathin Descemet Stripping Automated Endothelial keratoplasty; DMEK Descemet membrane endothelial keratoplasty; HoAs: High-order aberrations; *= $p < 0.05$; **= $p < 0.01$. Data are presented as mean \pm standard deviation (SD). All values are in micrometers.

4.3. Correlations between postoperative BCVA and corneal aberrations

The Spearman's correlation coefficients are reported in Table 5. BCVA 12 months after UT-DSAEK was significantly correlated with anterior HoAs, anterior astigmatism, total and anterior coma and anterior spherical aberration at a 4-mm optical zone; in DMEK eyes postoperative BCVA was correlated with total and anterior HoAs and total and anterior astigmatism at a 4-mm optical zone. Correlations between BCVA and aberrations at a 6-mm optical zone are reported in Table 5. All the significant correlations (except the posterior coma at a 6-mm optical zone) were positive (e.g. the higher the aberration, the higher the BCVA LogMAR value and the lower the visual acuity). The posterior coma at a 6-mm optical zone was negatively correlated to the BCVA (the higher the aberration, the lower the BCVA LogMAR value and the higher the visual acuity) but the level of significance was 0.030, not very high.

Table 5. Correlations between BCVA and corneal aberrations at a 4- and a 6-mm optical zones 12 months after surgery

	UT-DSAEK 4.0 mm r	DMEK 4.0 mm r	UT-DSAEK 6.0 mm r	DMEK 6.0 mm r
HOAs tot	-0.091	0.618**	0.213	0.448
HOAs front	0.647**	0.912**	0.334	0.500*
HOAs back	-0.091	-0.059	0.334	0.431
Astigmatism total	-0.030	0.529*	0.030	0.059
Astigmatism front	0.698**	0.529*	0.577*	0.059
Astigmatism back	-0.213	-0.309	-0.091	-0.412
Coma total	0.493*	0.418	0.954**	0.409
Coma front	0.556*	0.322	0.880**	0.413
Coma back	-0.273	0.448	-0.516*	0.344
Spherical aberration total	0.375	0.446	-0.395	0.425
Spherical aberration front	0.638**	0.435	-0.455	0.224
Spherical aberration back	0.063	-0.405	-0.395	0.224

*Spearman's correlation coefficients (r) are reported. UT-DSAEK: Ultra-thin Descemet Stripping Automated Endothelial keratoplasty; DMEK Descemet membrane endothelial keratoplasty; HoAs: High-order aberrations; *= $p < 0.05$; **= $p < 0.01$.*

4.4. Contrast sensitivity

Contrast sensitivity results were reported in figures 1 and 2; they were at the lowest limit or below the physiological contrast sensitivity range, especially in mesopic conditions, in both groups, compared to the linear model of normal patients of similar age (Figures 4 and 5).

Using linear mixed modelling, we found no overall interaction between procedure and spatial frequency in the photopic condition ($p=0.354$), where only frequency C (6 cpd) showed a borderline difference between procedures ($p=0.014$). Therefore, we averaged the differences across frequencies and found an average difference between UT-DSAEK and DMEK eyes of 0.12 logCS favouring DMEK ($p=0.022$).

In mesopic conditions we found a significant overall interaction between procedure and frequency ($p=0.017$), a heterogeneity which, again, was mainly related to a much larger difference in frequency C (6 cpd) ($p<0.001$). By averaging the differences across frequencies, we found that DMEK outperformed DSAEK by 0.20 logCS ($p<0.001$) more than in photopic conditions.

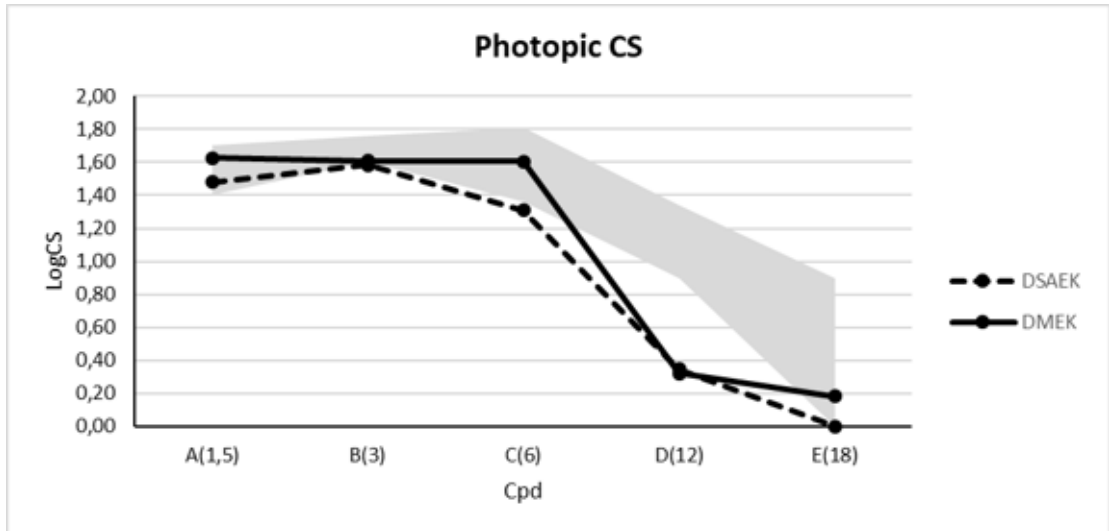


Figure 4: Contrast sensitivity ($\log_{10}CS$) measured with Optec 6500 Vision Tester under photopic conditions at different spatial frequencies (cycles per degree) at 12 postoperative months. The gray area represents the normal range of similar age subjects (Hohberger et al. 2017).

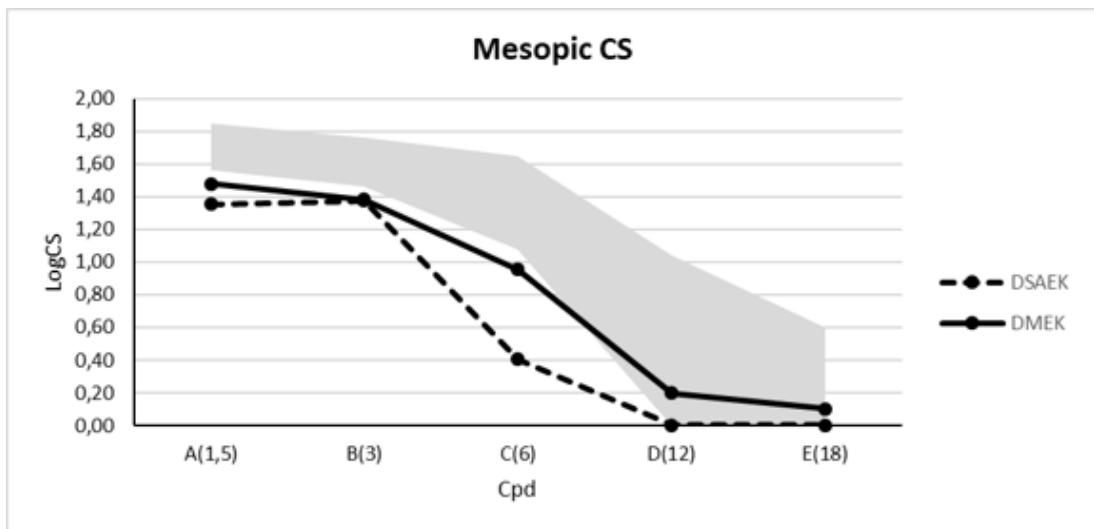


Figure 5: Contrast sensitivity ($\log_{10}CS$) under mesopic conditions measured with Optec 6500 Vision Tester at different spatial frequencies (cycles per degree) 12 months after surgery. The gray area represents the normal range of similar age subjects (Hohberger et al. 2017).

4.5. Satisfaction questionnaire

Patients were asked to evaluate visual outcomes on a scale of 1–6 (1= very bad, 6= excellent): for the UT-DSAEK eye the mean rate was 4.68 ± 0.49 , for the DMEK eye the score was $5.00 \pm 0,84$ ($P=0.031$, Wilcoxon signed rank test), which significantly favoured DMEK. Overall, patients were highly satisfied with their vision in both eyes, even though 33% reported good and 67% very good vision in the UT- DSAEK eye, whereas in the DMEK eye 33% reported good vision, 33% very good vision and a further 33% excellent vision

The majority of patients (83.4%) reported a very comfortable postoperative period after DMEK, while only half of them after UT-DSAEK; on a scale between 1 and 6 (1= very comfortable, 6= very uncomfortable) the mean score was 1.50 ± 0.51 after UT-DSAEK and 1.17 ± 0.38 after DMEK ($P=0.031$).

The mean recovery time to resume normal activities (question 3) was 20.83 ± 13.09 days after UT-DSAEK and significantly lower, 14.00 ± 9.41 days, after DMEK ($p<0.001$).

Patients were highly satisfied with both procedures (question 4): in both UT-DSAEK and DMEK eyes the score was 6 in 83.4% of patients (on a scale between 1=lest satisfied and 6=most satisfied), and the mean was 5.67 ± 0.67 after UT-DSAEK and 5.83 ± 0.38 after DMEK ($p=0.344$). Nevertheless 66.7% of patients (12 out of 18) preferred DMEK to UT-DSAEK (question 5).

5. DISCUSSION

DMEK and DSAEK are the two most widely performed endokeratoplasty techniques for the treatment of endothelial dysfunctions. Even though there is evidence that DMEK may give equal or better results than “conventional” DSAEK with grafts thicker than 130 microns and a faster recovery time (Marques et al. 2018, Pavlovich et al. 2017, Singh et al. 2017, Zhu et al. 2018, Hamzaoglu et al. 2015, Droutsas et al. 2018, Stuart et al. 2018), few studies have directly compared the visual outcomes between UT-DSAEK and DMEK (Bhandari et al. 2015, Chamberlain et al. 2019, Kurji et al. 2018, Tourabaly et al. 2019).

While Bhandari et al (Bhandari et al. 2015) and Chamberlain et al. (Chamberlain et al. 2019) found better visual outcomes after DMEK compared to UT-DSAEK, Tourabaly et al. (Tourabaly et al. 2019) found similar BCVA between DMEK, UT-DSAEK and NT-DSAEK, and Kurji et al. (Kurji et al. 2018) between DMEK and NT-DSAEK.

In our study, comparing the outcomes of UT-DSAEK and DMEK performed on fellow eyes, we found similar best corrected visual acuity at 12 postoperative months (0.10 ± 0.04 logMAR in UT-DSAEK, 0.07 ± 0.07 logMAR in DMEK eyes, $P=0.24$). Our results were better than those reported in the only published contralateral-eye comparison between UT-DSAEK (0.34 ± 0.1 logMAR, mean graft thickness 91.1 ± 10.1 μm) and DMEK (0.21 ± 0.12 logMAR) (Bandhari et al. 2015), which found a statistically significant difference between the two techniques favouring DMEK. Our results are more similar to a recent randomized trial, the DETECT study (Chamberlain et al. 2019) that found a visual acuity of 0.04 ± 0.12 logMAR in 25 eyes subjected to DMEK and 0.16 ± 0.18 logMAR in 25 eyes subjected to UT-DSAEK (central graft thickness 73 ± 12 μm), although with a significant difference between

groups; conversely, the retrospective study of Tourabaly et al. (Tourabaly et al. 2019) found a mean postoperative BCVA of 0.09 logMAR in DMEK eyes (n=30) and 0.17 logMAR in UT-DSAEK eyes (n=30), without significant differences between groups.

Regarding the previously reported quicker postoperative recovery after DMEK compared to DSAEK (Chamberlain et al. 2019, Guerra et al. 2011, Tourabaly et al. 2019), in our study we could not evaluate this parameter as only 12-month follow-up results were analyzed. Further larger or longer studies comparing UT-DSAEK and DMEK visual outcomes are necessary to more precisely assess the differences.

The postoperative endothelial cell count, while not showing statistically significant differences in the two groups, was better after UT-DSAEK than DMEK. These results, corresponding to a mean ECD loss of 34.83% and 38.01% respectively and comparable to other studies (Guerra et al. 2011), are probably caused by the increased handling of DMEK tissue during surgery. Even though none of the included patients had intraoperative complications, the higher number of early partial graft detachments (1 in the UT-DSAEK group and 3 in the DMEK group) the higher complexity of the DMEK technique and the relatively lower experience of the surgeon with DMEK (the analysed cases were within the surgeon's first hundred) may explain our results.

It has been pointed out that the visual performance of patients undergoing EK can be influenced by multiple factors, e.g. the duration of the disease, high-order aberrations (HoA), haze-related light reflection phenomena, parallelism and irregularities of the host-donor interface (Turnbull et al. 2016, Hayashi et al. 2017). In our study posterior corneal aberrations such as HOAs, astigmatism and coma were significantly lower after DMEK than UT-DSAEK, while the anterior aberrations did

not significantly differ. Nevertheless, postoperative visual acuity was significantly correlated (the higher the aberrations, the lower the visual acuity) mainly with total or anterior aberrations, like HOAs and astigmatism in the DMEK eyes, and with HOAs, astigmatism, coma and spherical aberration in the UT-DSAEK eyes. Our results are generally in line with studies comparing DSAEK and DMEK, that found higher posterior aberrations in DSAEK eyes (Rudolph et al. 2012, Yamaguchi et al. 2015, Van Dijk et al. 2014, Duggan et al. 2019). In fact, the stromal lamella present in DSAEK grafts seems to be responsible for posterior astigmatism, hyperopic shift and HOAs (Yamaguchi et al. 2015, Tourtas et al. 2012). Despite the continuous improvement in DSAEK graft preparation and regularity, a difference in posterior corneal aberrations seems to still be present even with thinner grafts (Duggan et al. 2019). Only two studies about aberrations after UT-DSAEK and DMEK have been published up to now (Tourabaly et al 2019, Duggan et al. 2019): while the retrospective study of Tourabaly M et al. (Tourabaly et al. 2019), which evaluated the total ocular aberrations, didn't find any difference, the randomized controlled prospective study DETECT (Duggan et al. 2019) found significantly higher posterior corneal HOAs, coma and trefoil at the 4-mm optical zone and significantly higher posterior corneal coma, astigmatism, tetrafoil and HOAs at the 6-mm optical zone 12 months after UT-DSAEK compared to DMEK. In our study, however, contrary to what has been reported by Duggan et al., total HOAs and total coma were higher after UT-DSAEK than after DMEK at both 4 and 6-mm optical zones as well.

Despite these differences between the two groups in posterior corneal aberrations, in our study visual acuity seems to be more influenced by anterior corneal aberrations: this would confirm the importance of the anterior corneal changes (haze or fibrotic

changes due to stromal edema) related to the duration of the diseases (Yamaguchi et al. 2015, Turnbull et al. 2016, Van Dijk et al. 2014, Mencucci et al. 2015).

Conversely, the randomized trial of Duggan et al. (Duggan et al. 2019), which involved 25 patients per group, found significant correlations between postoperative posterior HOAs and postoperative BCVA, and not between anterior HOAs and BCVA. These results need to be confirmed by studies on larger cohorts of patients. A limitation of our study is the lack of preoperative aberrometric evaluation, that may add information about the preoperative severity of the disease.

Contrast sensitivity has been reported to be better after DMEK than after DSAEK, probably due to the asymmetry of the DSAEK graft or due to the stroma-to-stroma interface irregularities (Cabrerizo et al 2014, Maier et al. 2015); furthermore, the contrast sensitivity after DMEK in phakic eyes was comparable to healthy eyes in previous studies (Cabrerizo et al 2014, Maier et al. 2015). To our knowledge, no studies comparing contrast sensitivity between UT-DSAEK and DMEK have been published up to now. Our results in pseudophakic patients show that DMEK outperformed UT-DSAEK especially in mesopic conditions and at intermediate spatial frequencies; in both groups contrast sensitivity values were at the lower limit or below the age-standardized reference threshold of normal phakic patients. The most appropriate reference group would have been composed of pseudophakic controls, but contrast sensitivity values of pseudophakic controls measured using the Optec 6500 vision tester have not yet been published.

Finally, the satisfaction questionnaire showed that although patients were highly satisfied with both procedures more than half of them preferred DMEK and reported more comfortable and quicker postoperative recovery. Although they were highly satisfied with their vision in both eyes, about one third of patients reported excellent

vision only in DMEK eyes.

In conclusion, according to our results, DMEK and UT-DSAEK showed no differences in terms of postoperative BCVA, although DMEK had a better performance in terms of contrast sensitivity, posterior corneal aberrations and overall patient satisfaction. Moreover, our study confirms that the measurement of high-contrast visual acuity alone is an insufficient indicator of the subjective and objective visual performance of patients who underwent EK for endothelial dysfunction. Visual outcome after EK may depend not only on the BCVA, which in our study did not differ significantly between the two techniques, but it may also be related to other parameters such as the thickness of the transplanted graft, corneal aberrations and contrast sensitivity. These factors, together with the speed of postoperative recovery, may influence the overall patient satisfaction. Further studies on a higher number of patients are needed to confirm our results and to better analyse differences between UT- or NT-DSAEK and DMEK outcomes.

6. REFERENCES

- Adamis AP, Filatov V, Tripathi BJ & Tripathi RC (1993): Fuchs' endothelial dystrophy of the cornea. *Surv. Ophthalmol.* 38, 149e168.
- Afshari NA, Pittard AB, Siddiqui A & Klintworth GK (2006): Clinical study of Fuchs corneal endothelial dystrophy leading to penetrating keratoplasty: a 30-year experience. *Archives of Ophthalmology* 124(6):177–80.
- Ayres BD & Rapuano CJ (2006): Refractive power of the cornea. *Comprehensive Ophthalmology Update* 7(5):243–51.
- Bhandari V, Reddy JK, Relekar K & Prabhu V (2015): Descemet's Stripping Automated Endothelial Keratoplasty versus Descemet's Membrane Endothelial Keratoplasty in the Fellow Eye for Fuchs Endothelial Dystrophy: A Retrospective Study. *Biomed Res Int.* 2015:750567.
- Boimer C, Lee K, Sharpen L, Mashour R & Slomovic A (2011): Evolving surgical techniques of and indications for corneal transplantation in Ontario from 2000 to 2009. *Canadian Journal of Ophthalmology* 46(4):360–6.
- Bonanno JA (2012): Molecular Mechanisms Underlying the Corneal Endothelial Pump. *Exp Eye Res* 95 (1): 2-7
- Busin M & Albé E (2014): Does thickness matter: ultrathin Descemet stripping automated endothelial keratoplasty. *Curr Opin Ophthalmol.* 25:312-318
- Busin M, Madi S, Santorum P, Scorcio V & Beltz J. (2013): Ultrathin Descemet's stripping automated endothelial keratoplasty with the microkeratome double-pass technique: two-year outcomes. *Ophthalmology.* 120:1186-1194

- Cabrerizo J, Livny E, Musa FU, Leeuwenburgh P, van Dijk K & Melles GR (2014): Changes in color vision and contrast sensitivity after descemet membrane endothelial keratoplasty for fuchs endothelial dystrophy. *Cornea* 33 :1010-1015.
- Chamberlain W, Lin CC, Austin A et al (2019): Descemet Endothelial Thickness Comparison Trial: A Randomized Trial Comparing Ultrathin Descemet Stripping Automated Endothelial Keratoplasty with Descemet Membrane Endothelial Keratoplasty. *Ophthalmology* 126:19-26.
- Cheung AY, Hou JH, Bedard P, Grimes V, Buckman N, Eslani M & Holland EJ (2018): Technique for Preparing Ultrathin and Nanothin Descemet Stripping Automated Endothelial Keratoplasty Tissue. *Cornea* 37:661-666.
- Claesson M, Arnotage WJ & Stenevi U (2009): Corneal oedema after cataract surgery: predisposing factors and corneal graft outcome. *Acta Ophthalmologica* 87(2):154–9.
- Cross HE, Maumenee AE & Cantolino SJ (1971): Inheritance of Fuch's endothelial dystrophy. *Archives of Ophthalmology* 85(3):268–72.
- Dickman MM, Kruit PJ, Remeijer L et al (2016): Randomized Multicenter Clinical Trial of Ultrathin Descemet Stripping Automated Endothelial Keratoplasty (DSAEK) versus DSAEK. *Ophthalmology* 123:2276-2284
- Droutsas K, Lazaridis A, Giallouros E, Kymionis G, Chatzistefanou K & Sekundo W (2018): Scheimpflug Densitometry After DMEK Versus DSAEK-Two-Year Outcomes. *Cornea* 37:455-461
- Duggan MJ, Rose-Nussbaumer J, Lin CC, Austin A, Labadzinzki PC, Chamberlain WD. Corneal Higher-Order Aberrations in Descemet Membrane

Endothelial Keratoplasty versus Ultrathin DSAEK in the Descemet Endothelial Thickness Comparison Trial: A Randomized Clinical Trial. *Ophthalmology*. 2019; 126(7): 946-957.

- Frigo AC, Fasolo A, Capuzzo C, Fornea M, Bellucci R, Busin M, et al (2015): Corneal transplantation activity over 7 years: changing trends for indications, patient demographics and surgical techniques from the Corneal Transplant Epidemiological Study (CORTES). *Transplant Proceedings* 47(2):528–35.
- Fuchs E (1910): Dystrophia epithelialis corneae. *Albr von Græfe's Arch für Ophthalmol*. 76(3):478–508.
- Goldich Y, Showail M, Avni-Zauberman N, Perez M, Ulate R, Elbaz U & Rootman DS (2015): Contralateral eye comparison of descemet membrane endothelial keratoplasty and descemet stripping automated endothelial keratoplasty. *Am J Ophthalmol*. 159:155-159.
- Gorovoy MS (2006): Descemet-stripping automated endothelial keratoplasty. *Cornea* 25(8):886-9.
- Guerra FP, Anshu A, Price MO & Price FW (2011): Endothelial keratoplasty: fellow eyes comparison of Descemet stripping automated endothelial keratoplasty and Descemet membrane endothelial keratoplasty. *Cornea* 30:1382-1386.
- Hamzaoglu EC, Straiko MD, Mayko ZM, Sales CS & Terry MA (2015): The First 100 Eyes of Standardized Descemet Stripping Automated Endothelial Keratoplasty versus Standardized Descemet Membrane Endothelial Keratoplasty. *Ophthalmology* 122:2193-2199

- Hayashi T, Yamaguchi T, Yuda K, Kato N, Satake Y & Shimazaki J (2017): Topographic characteristics after Descemet's membrane endothelial keratoplasty and Descemet's stripping automated endothelial keratoplasty. *PLoS One* 12: e0188832.
- Hohberger B, Laemmer R, Adler W, Juenemann AGM & Horn FK (2007): Measuring contrast sensitivity in normal subjects with OPTEC® 6500: influence of age and glare. *Graefes Arch Clin Exp Ophthalmol* 245:1805–1814
- Joyce NC, Meklar B, Joyce SJ et al (1996): Cell cycle protein expression and proliferative status in human corneal cells. *Invest Ophthalmol Vis Sci* 37:645–655
- Kurji KH, Cheung AY, Eslani M, Rolfes EJ, Chachare DY, Auteri NJ, Nordlund ML & Holland EJ (2018): Comparison of Visual Acuity Outcomes Between Nanothin Descemet Stripping Automated Endothelial Keratoplasty and Descemet Membrane Endothelial Keratoplasty. *Cornea* 37:1226-1231.
- Lee WB, Jacobs DS, Musch DC, Kaufman SC et al (2009): Descemet's stripping endothelial keratoplasty: safety and outcomes: a report by the American Academy of Ophthalmology. *Ophthalmology* 116(9): 1818–30.
- Maier AK, Gundlach E, Gonnermann J, Klamann MK, Bertelmann E, Rieck PW, Jousseaume AM & Torun N (2015): Retrospective contralateral study comparing Descemet membrane endothelial keratoplasty with Descemet stripping automated endothelial keratoplasty. *Eye* 29:327-332.
- Marques RE, Guerra PS, Sousa DC, Sousa DC, Gonçalves AI, Quintas AM & Rodrigues W (2018): DMEK versus DSAEK for Fuchs' endothelial dystrophy: A meta-analysis. *Eur J Ophthalmol*. 29:15-22

- Melles GR, Ong TS, Ververs B & Van der Wees J (2006): Descemet membrane endothelial keratoplasty (DMEK). *Cornea*; 25:987–990.
- Mencucci R, Favuzza E, Tartaro R, Busin M & Virgili G (2015): Descemet stripping automated endothelial keratoplasty in Fuchs' corneal endothelial dystrophy: anterior segment optical coherence tomography and in vivo confocal microscopy analysis. *BMC Ophthalmol.* 15:99
- Neff KD, Biber JM & Holland EJ (2011): Comparison of central corneal graft thickness to visual acuity outcomes in endothelial keratoplasty. *Cornea* 30:388–3914
- Okumura N, Koizumi N, Ueno M, et al (2012): ROCK inhibitor converts corneal endothelial cells into a phenotype capable of regenerating in vivo endothelial tissue. *Am J Pathol.* 181(1):268-77.
- Okumura N, Koizumi N, Ueno et al. (2011): Enhancement of corneal endothelium wound healing by Rho-associated kinase (ROCK) inhibitor eye drops. *Br J Ophthalmol.* 95(7):1006-9.
- Pavlovic I, Shajari M, Herrmann E, Schmack I, Lencova A & Kohnen T (2017). Meta-Analysis of Postoperative Outcome Parameters Comparing Descemet Membrane Endothelial Keratoplasty Versus Descemet Stripping Automated Endothelial Keratoplasty. *Cornea* 36:1445-1451
- Pineros O, Cohen EJ, Rapuano CJ, Laibson PR (1996): Long-term results after penetrating keratoplasty for Fuchs endothelial dystrophy. *Archives of Ophthalmology* 114(1):15–8.
- Romano V, Steger B, Myneni J, Batterbury M, Willoughby CE & Kaye SB (2017): Preparation of ultrathin grafts for Descemet-stripping endothelial

- keratoplasty with a single microkeratome pass. *J Cataract Refract Surg.* 43:12-15.
- Rudolph M, Laaser K, Bachmann BO, Cursiefen C, Epstein D & Kruse FE (2012): Corneal higher-order aberrations after Descemet's membrane endothelial keratoplasty. *Ophthalmology* 119:528-535
 - Singh A, Zarei-Ghanavati M, Avadhanam V & Liu C (2017): Systematic review and meta-analysis of clinical outcomes of Descemet membrane endothelial keratoplasty versus Descemet stripping endothelial keratoplasty/Descemet stripping automated endothelial keratoplasty. *Cornea* 36:1437–1443.
 - Smolin G, Throft R & Dohlman CH (1994): Endothelial function. *The Cornea; Scientific Foundations and Clinical Practice.* 3rd Edition. Lippincott William and Wilkins, 635–43
 - Stuart AJ, Romano V, Virgili G & Shortt AJ (2018): Descemet's membrane endothelial keratoplasty (DMEK) versus Descemet's stripping automated endothelial keratoplasty (DSAEK) for corneal endothelial failure. *Cochrane Database Syst Rev.* 6: CD012097.
 - Terry MA & Ousley PJ (2001): Deep lamellar endothelial keratoplasty in the first United States patients: early clinical results. *Cornea* 20(3):239–43.
 - Terry MA, Straiko MD, Goshe JM, Li JY & Davis-Boozer D (2012): Descemet's stripping automated endothelial keratoplasty: the tenuous relationship between donor thickness and postoperative vision. *Ophthalmology* 119:1988-1996
 - Tourabaly M, Chetrit Y, Provost J, Georgeon C, Kallel S, Temstet C, Bouheraoua N, Borderie V. Influence of graft thickness and regularity on

vision recovery after endothelial keratoplasty. *Br J Ophthalmol.* 2019 Dec 17
pii: [bjophthalmol-2019-315180](https://doi.org/10.1136/bjophthalmol-2019-315180). doi: 10.1136/bjophthalmol-2019-315180.
[Epub ahead of print]

- Tourtas T, K. Laaser, B. O. Bachmann, Cursiefen C & Kruse FE (2012): Descemet membrane endothelial keratoplasty versus descemet stripping automated endothelial keratoplasty. *Am J Ophthalmol* 153: 1082– 1090.
- Turnbull AM, Tsatsos M, Hossain PN & Anderson DF (2016): Determinants of visual quality after endothelial keratoplasty. *Surv Ophthalmol* 61:257-271.
- Van den Bogerd B, Dhubhghaill SN, Koppen C, et al (2018): A review of the evidence for in vivo corneal endothelial regeneration. *Surv Ophthalmol.* 63(2):149-165
- Van Dijk K, Droutsas K, Hou J Sangsari S, Liarakos VS & Melles GR (2014): Optical quality of the cornea after Descemet membrane endothelial keratoplasty *Am J Ophthalmol* 158:71-79
- Wacker K, McLaren JW, Amin SR, Baratz KH & Patel SV (2015). Corneal High-Order Aberrations and Backscatter in Fuchs' Endothelial Corneal Dystrophy. *Ophthalmology* 122:1645-1652
- Watanabe S, Oie Y, Fujimoto H, Soma T, Koh S, Tsujikawa M, Maeda N & Nishida K (2015): Relationship between corneal guttae and quality of vision in patients with mild Fuchs' endothelial corneal dystrophy *Ophthalmology* 122:2103-2109
- Wilson SE & Bourne WM (1988): Fuchs' dystrophy. *Cornea.* 7:2–18.
- Yamaguchi T, Satake Y, Dogru M, Ohnuma K, Negishi K & Shimazaki J. (2015): Visual Function and Higher-Order Aberrations in Eyes After Corneal

Transplantation: How to Improve Postoperative Quality of Vision. *Cornea* 34
Suppl 11: S128-35

- Zhang J & Patel DV (2015): The pathophysiology of Fuchs' endothelial dystrophy e A review of molecular and cellular insights. *Exp Eye Res* 130:97e105
- Zhu L, Zha Y, Cai J & Zhang Y (2018): Descemet stripping automated endothelial keratoplasty versus Descemet membrane endothelial keratoplasty: a meta-analysis. *Int Ophthalmol* 38:897-905