

## PRIMARY HEMANGIOPERICYTOMA OF THE INFRATEMPORAL FOSSA

G.A. PACINO<sup>1</sup>, L.M. REDONDO<sup>2</sup>, S. COCUZZA<sup>3</sup>, A. MANIACI<sup>3</sup>, M.C. DA MOSTO<sup>4</sup>,  
P. BOSCOLO-RIZZO<sup>5</sup>, G. TONOLI<sup>6</sup>, G. MANNELLI<sup>7</sup> and G. SPINATO<sup>4,5</sup>

<sup>1</sup>Oral and Maxillo-Facial Department, Provincial Rovigo Hospital, Italy; <sup>2</sup>Oral and Maxillofacial Surgery Department. Río Hortega Hospital, Valladolid, Spain; <sup>3</sup>Department of Medical and Surgical Sciences and Advanced Technologies “GF Ingrassia”, ENT Section; University of Catania- Italy; <sup>4</sup>Department of Neurosciences, Section of Otolaryngology and Regional Centre for Head and Neck Cancer, University of Padova, Treviso, Italy; <sup>5</sup>Department of Surgery, Oncology and Gastroenterology, Section of Oncology and Immunology, University of Padova, Padova, Italy. <sup>6</sup>Ear, Nose and Throat Department, Rovigo Provincial Hospital, Rovigo, Italy; <sup>7</sup>Academic Clinic of Otolaryngology-Head and Neck Surgery, University of Florence

Received October 10, 2019 – Accepted March 13, 2020

To the Editor,

Hemangiopericytoma (HPC) is a rare perivascular tumour classified as a soft-tissue vascular tumour featuring the uncontrolled proliferation of pericytic cells (1). Showing trend for ubiquitous location, soft tissue of lower extremities, pelvic fossa and retroperitoneum are the predominant sites of origin. Its incidence in the head and neck region has been considered approximately less than 20% (2). In this area, the majority of the reported cases are in the nasal cavity and paranasal sinuses, nasopharynx, jawbones, orbit and scalp; other areas involved have included parotid and submandibular gland, larynx, parapharyngeal space, sinus tract and meninges, trachea, middle ear, oral cavity and thyroid gland (1).

A review of the medical literature on tumours occupying the infratemporal fossa reveals that primary HPCs of this anatomical space are exceedingly rare, secondary involvement due to direct extension from adjacent sites being more commonly found (3). To the best of our knowledge, only nine previous cases

of primary HPCs involving the infratemporal fossa have been reported up until the end of 2018 (Table I) (2). We report herein an additional case of HPC arising in the infratemporal fossa, describing the gross and microscopic features of this lesion, as well as clinical presentation, management and outcomes.

In September 2001, a 23-year-old woman was referred to the Oral and Maxillofacial Surgery Department for evaluation and treatment of a left-sided facial swelling. The mass had been growing slowly over a 1-year period with no history of trauma, fever, pain, paraesthesia or dysphagia. The patient gave informed consent to report her case. On examination, a large well-demarcated, smooth-lobular, elastic-hard, compressible, immobile mass was found on the left facial region. The bulging was not adherent to the skin and there was no discoloration, bruit, thrill or pulsation. The examination of the neck did not reveal lymphadenopathies. The patient showed a full range of mandibular motion and normal salivary flow from the major duct of the

*Key words: vascular neoplasm; hemangiopericytoma; infratemporal fossa; surgery*

Corresponding Author:

Dr. Antonino Maniaci,  
ENT Department of University of Catania,  
95100, Via Santa Sofia,  
Catania, Italy  
Tel.: +39.0953781103  
e-mail: tnmaniaci29@gmail.com

0393-974X (2020)

Copyright © by BIOLIFE, s.a.s.

This publication and/or article is for individual use only and may not be further reproduced without written permission from the copyright holder.

Unauthorized reproduction may result in financial and other penalties  
**DISCLOSURE: ALL AUTHORS REPORT NO CONFLICTS OF INTEREST RELEVANT TO THIS ARTICLE.**

parotid gland. The intraoral hard and soft tissues were completely normal, and the caudal aspect of the mass was palpated in the posterior maxillary region where a partial obliteration of the left gingiva-buccal sulcus was observed. Fine needle aspiration obtained only blood. A careful intraoral punch biopsy attempt was hampered by copious bleeding, which required haemostatic package and suture. The subsequent histology was inconclusive. A post-contrast computed tomographic scan confirmed an enhanced soft-tissue mass extending from the left infratemporal fossa to the homolateral mandibular ramus with no evidence of bony destruction or of intracranial extension. Magnetic resonance imaging (MRI) with gadolinium enhancement showed a large lobular-shaped mass that was embedding exteriorly the inner surface of the zygomatic arch and of the masseter muscle and posteriorly the temporal muscle and the lateral surface of the external pterygoid muscle (Fig. 1). In all its extension the mass showed clear contouring without signs of surrounding anatomical invasion. The tumour was highly perfused. This was confirmed by angiography (Fig. 2).

The supplying vessel originating from the left maxillary artery was selectively embolized. Thereafter, the tumour was surgically resected via a transfacial route by means of Weber-Ferguson approach. Macroscopically, the specimen consisted of a regularly pseudo capsuled lobular-mass measuring 6.5 x 5 x 2.5 cm in its greatest dimensions (Fig. 3). On cross surface, a solid portion was observed of the lesion intermingled with cystic features with gray-brown haemorrhagic areas and a jelly-like consistency. Sections from formalin-fixed tissue stained with haematoxylin and eosin exhibited round and spindle-shaped tumour cells arranged in nest patterns with ill-defined borders and round-to-oval nuclei surrounding the endothelial-lined vascular channels (Fig. 4). The anastomosing vessel ranged from capillary to large sinusoidal spaces, revealing a multiple staghorn pattern. Cellular pleomorphism was minimal and more than two mitotic figures per 10 high-powered fields were present. The definitive histopathological diagnosis was consistent with HPC.

The postoperative course was entirely uneventful, and the patient was discharged from the hospital on

the fifth postoperative day. After 18 years of clinic-instrumental recall examinations there is no evidence of local recurrence or distant metastases.

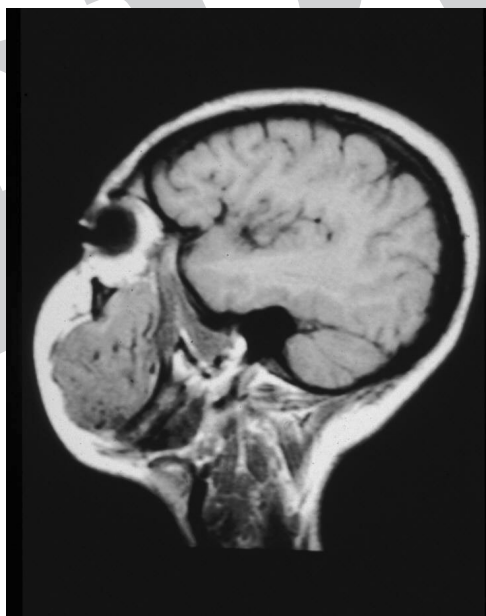
## DISCUSSION

Since its descriptions in 1942 by Stout and Murray, hemangiopericytoma has evoked controversy mainly because of its uncertain pathological entity. Several articles have questioned whether it is a histopathologic pattern or a clinicopathologic entity, a diagnosis of exclusion, a wastebasket diagnosis or a dying breed (4-6). Basically, HPC is characterized as benign or malignant, round to spindle-shaped cell tumour with numerous "staghorn" branching vascular channels. First of all, the histologic, immunohistochemical, and ultrastructural features of HPC seem to be rather unspecific. The HPC-like vascular pattern can be present in many neoplasms such as synovial sarcoma, mesenchymal chondrosarcomas, benign and malignant fibrous histiocytoma, malignant peripheral nerve sheath tumours, solitary fibrous tumours, malignant mesotheliomas, leiomyosarcomas, thymomas, sarcomatous carcinomas, endometrial stromal sarcomas (7). Secondly, there is a clearly noticeable variation in the clinical course, and histologic grading does not necessarily correlate with biological behaviour. According to the World Health Organization, HPC is graded as grade II and III, depending on the mitotic rate ( $> 5$  mitoses per 10 high-power fields), high cellularity, nuclear pleomorphism, haemorrhage and necrosis. Thirdly, there is a lack of understanding regarding the nature and function of the pericytes. Originally identified by Rouget in 1873 and subsequently described by Zimmermann in 1923, these are cells with modified, smooth muscle characteristic that are highly arborized and arranged alongside capillary vessels where they have a contractile capability and are responsible for vessel calibre regulation, and modulating both flux and permeability. However, other authors have postulated that pericytes represent versatile precursors of other mesenchymal cells, such as fibroblasts (8). There is no general agreement as to the aetiology of this neoplasm, although HPC has been linked to infection by an oncogenic virus,

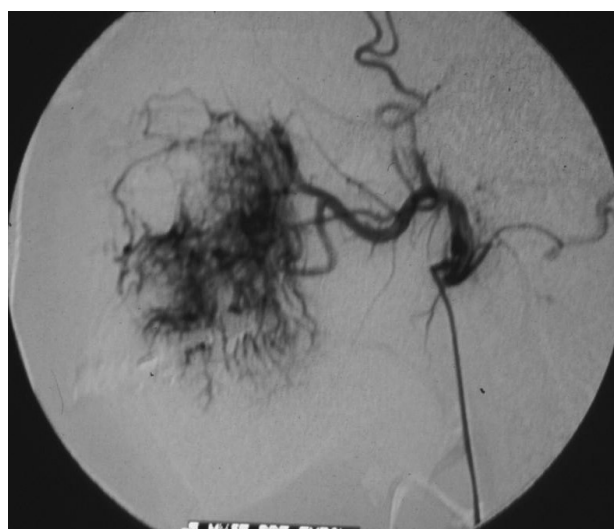traumatic factors, prolonged steroid therapy and hormonal imbalance. Recent biomolecular research suggests that endothelial and non-endothelial sources of angiogenic factors seem to regulate pericyte recruitment and influence vascular pattern formation during the pathogenetic development of HPC (9, 10).

Enzinger and Smith have allocated this uncommon tumour to two groups: an adult type and a congenital or infantile type. In elderly patients, the tumour seems to be deeply sited, located in muscle tissue and showing more frequently a malignant course, whereas the congenital or infantile forms are almost invariably superficial in site, and appear to behave in a benign fashion. In the head and neck area, this neoplasm presents in a rather unspecific way; often, symptoms are directly related to the anatomic location of the neoplasm.

Computed tomography scan is superior to most studies, but it often fails to define planes, may not always clearly indicate the vascularity of the lesion,



**Fig. 1.** Sagittal T1-weighted MR image depicts a large, well demarcated lobular soft-tissue mass extending from the left infratemporal fossa to the mandibular ramus. On this sequence the lesion shows an inhomogeneous matrix with prominent internal flow void.

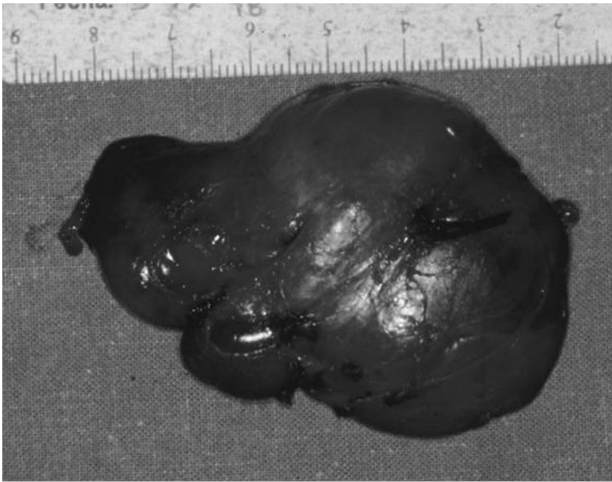


**Fig. 2.** Common carotid angiography demonstrating a highly vascular lesion with dense staining and displacement of major vessel.

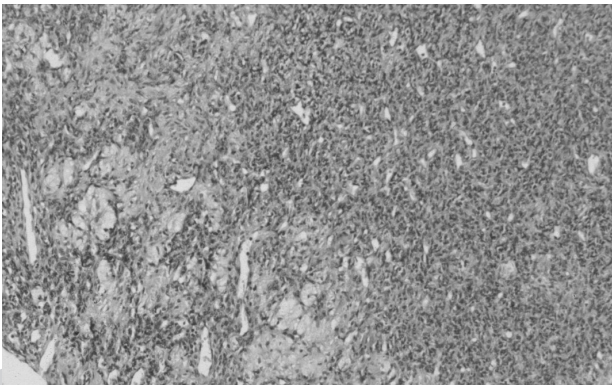
and can underestimate the full extent of the mass. MR imaging findings, albeit not specific, may reveal a well to fairly circumscribed lobular soft tissue mass with intermediate signal intensity on T1-weighted sequences, mild hyper-intensity on T2-weighted sequences and a marked gadolinium enhancement. A feeder vascular pedicle with radial branching wrapping a well-demarcated tumour stain, such as observed in our case, is reported as a characteristic angiographic finding in HPC, therefore it is not of unequivocal value in all cases.

The large number of possible diagnoses of swelling of the infratemporal fossa and aspecificity of the clinic-instrumental presentation make a suspect diagnosis extremely difficult and only a detailed histopathological assessment can lead to the correct definitive diagnosis (11).

A review of the ten reported cases of infratemporal fossa primary HPC (Table I), including our case described herein, revealed a slight sex predominance (6 females, 4 males) with a mean age of 39 years. The most common clinical complaint was a palpable painless mass (9/10). Radical surgery was the treatment of choice (9/10). Complete surgical resection is considered the mainstay of treatment for localized and resectable tumours, giving an approximately overall cure rate of 50% at all sites. Preoperative embolization has been suggested as



**Fig. 3.** Surgical specimen measuring 6.5 x 5 x 2.5 cm in its greatest dimensions.



**Fig. 4.** Haematoxylin and Eosin section showing marked proliferation of round to spindle-shaped cells with atypical cellularity around branching vessels (Original magnification X 150)

an adjunct for decreasing tumour vascularity and size in order to obtain a successful resection. Of the ten reported cases, only six patients received perioperative embolization, and virtually no bleeding was encountered during tumour resection, while the remaining HPCs were amenable to surgical resection without embolization.

The usefulness of adjuvant radiant therapy has not been fully supported in the literature, although several studies suggest that radiotherapy can be used in case of incomplete resection, unresectable or recurrent disease. Chemotherapy can be useful for preoperative tumour reduction as a postoperative adjunct for tumour metastases and for palliative purposes. Positive responses have been reported for Adriamycin alone or in combination with cyclophosphamide, vincristine, methotrexate or actinomycin D, although several authors still consider HPC chemotherapy-resistant. In our review, one patient with metastatic disease died within a short period of receiving chemotherapy.

In spite of light, scanning and transmission electron microscopy as well as immunohistochemical and electron microscopical studies, no definite histological criteria indicative of benign or malignant HPCs could be established. The relapses and/or occurrence of metastases even after many years, as observed in our review series, makes the existence of benign variant once again questionable. It appears appropriate to

**Table I.** Previous cases of primary HPCs involving the infratemporal fossa reported in the literature.

Case N°	Source	Sex/Age	Clinical Complaints	Treatment	Tumour size	Mitotic Features	Follow-up	Status
1	Philippou et al. (1992)	M/27	Painless facial swelling	Embolization-Surgery-Radiotherapy	4 cm	8 mitosis x 10 HPF	N.D.	NED
2	Philippou et al. (1992)	F/53	Slow growing mass	Surgery	8 cm	Sparse	16 years	Recurrent multiple relapses treated with radio-chemotherapy; death for liver metastatic disease
3	Piral et al. (1995)	F/24	Painless facial swelling	Embolization-Surgery	5 cm	Sparse	3 years	NED
4	Hemar et al. (1996)	M/61	Otitis, Epistaxis*	Embolization-Surgery	N.D.	N.D.	15 months	NED
5	Kanazawa et al. (2001)	M/42	Painless facial swelling, facial palsy	Embolization-Surgery	2.7 x 2.5 cm	Absent	5 years	NED
6	Bianchi et al. (2002)	F/72	Painless facial mass	Embolization-Surgery	3.2 x 4.2 cm	Sparse	3 years	NED
7	Boulaich et al. (2003)	M/16	Oropharyngeal mass, dysphagia	Surgery	N.D.	Sparse	10 years	NED
8	Boulaich et al. (2003)	F/60	Painless facial swelling	Surgery	N.D.	Absent	3 years	Death for untreatable local relaps and bone metastatic disease
9	Shetty et al. (2007)	F/12	Painless facial mass, visual disturbance	N.D.**	10 x 10 cm	Sparse	N.D.	N.D.
10	Pacino et al. 2019	F/23	Painless facial mass, intraoral bulging	Embolization-Surgery	6.5 x 5 cm	2 mitosis x 10 HPF	11 years	NED

N.D: not defined; NED: no evidence of disease; HPF: High-power fields. \* This patient had a history of three prior resection of HPC of the infratemporal fossa. \*\* In this patient only, a biopsy was performed

consider all HPCs as potentially malignant. The clinical course alone determines whether or not the tumour is clustered benign or malignant.

HPC of the head and neck are believed to behave more favourably compared with their counterparts in other anatomic sites. No apparent explanation for this less malignant behaviour is evident, and the reported recurrence rate in literature ranges from 40-50%. Data from our review series seem to support the aforementioned contention with a recurrence rate of 22%. Overall, metastases occur in 18-50% of patients, mostly to the lung, liver and bone. Given the rarity and lack of unequivocal opinions on the management of the pathology, it is very important to establish specific guidelines for the correct treatment of the same (12).

#### REFERENCES

1. Batsakis JG, Rice DH. The pathology of head and neck tumors: vasoformative tumors, part 9B. *Head Neck Surg* 1981; 3(4):326-39
2. Stout AP, Murray MR. Hemangiopericytoma: a vascular tumor featuring Zimmermann's pericytes. *Ann Surg* 1942; 116 (1):26-33. doi:10.1097/00000658-194207000-00004
3. McMaster MJ, Soule EH, Ivins JC. Hemangiopericytoma. A clinicopathologic study and long-term followup of 60 patients. *Cancer* 1975; 36(6):2232-44. doi:10.1002/cncr.2820360942
4. Enzinger FM, Smith BH. Hemangiopericytoma. An analysis of 106 cases. *Human Pathol* 1976; 7(1):61-82. doi:10.1016/s0046-8177(76)80006-8
5. Spinato G, Cazzato G, Ferlito S, et al. Therapeutical innovations and medical responsibility: What's new in otolaryngology. *Acta Medica Mediterranea* 2018; 34:307-12. doi:10.19193/0393-6384\_2018\_2\_49
6. Sutbeyaz Y, Selimoglu E, Karasen R, Ciftcioglu A, Ozturk A. Haemangiopericytoma of the middle ear: case report and literature review. *J Laryngol Otol* 1995; 109:977-79. doi:10.1017/S0022215100131809
7. Cocuzza S, Di Luca M, Maniaci A, et al. Precision treatment of post pneumonectomy unilateral laryngeal paralysis due to cancer. *Future Oncol* 2020 (London, England). doi:10.2217/fon-2019-0053
8. Galletti B, Gazia F, Freni F, Sireci F, Galletti F. Endoscopic sinus surgery with and without computer assisted navigation: A retrospective study. *Auris Nasus Larynx* 2019; 46(4):520-25. doi:10.1016/j.anl.2018.11.004
9. Abdel-Fattah HM, Adams GL, Wick MR. Hemangiopericytoma of the maxillary sinus and skull base. *Head Neck* 1990; 12(1):77-83
10. Cocuzza S, Marino S, Gulino A, et al. ENT involvement and orobuccal movements' disorders in Pandalis patients: assessment and rehabilitations tools. *Eur Rev Med Pharmacol Sci* 2019; 2 (10):4110117. doi:10.26355/eurrev\_201905\_17912
11. Shetty SR, Chatra L, Shenai KP. Orofacial haemangiopericytoma--a rare case. *Dentomaxillofac Radiol* 2007; 36(7):437-40. doi:10.1259/dmfr/57664386
12. Ciofalo A, Gulotta G, Iannella G et al. Giant Cell Arteritis (GCA): Pathogenesis, Clinical Aspects and Treatment Approaches. *Curr Rheumatol Rev* 2019; 15(4):259-68. doi:10.2174/1573397115666190227194014