



Contents lists available at ScienceDirect

International Journal of Surgery Case Reports

journal homepage: www.casereports.com

Skin-reducing mastectomy and direct-to-implant reconstruction in giant phyllodes tumour of breast: case report



Francesco Ciancio^{a,*}, Alessandro Innocenti^b, Luigi Cagiano^a, Aurelio Portincasa^c,
Domenico Parisi^c

^a Department of Plastic and Reconstructive Surgery, University of Bari, Foggia, Italy

^b Plastic and Reconstructive Microsurgery, Careggi Universital Hospital, Florence, Italy

^c Department of Plastic and Reconstructive Surgery, University of Foggia, Italy

ARTICLE INFO

Article history:

Received 23 August 2017

Received in revised form 3 November 2017

Accepted 3 November 2017

Keywords:

Skin reducing

Breast reconstruction

Breast cancer

Phyllodes

Mastectomy

Oncoplastic technique

ABSTRACT

BACKGROUND: The phyllodes tumour of the breast comprises about 0.5% of all neoplasms of the breast.

CASE REPORT: we present the case of a female patient (55 years old) suffering from giant phyllodes tumour (>10 cm) of the left breast, who underwent Skin Reducing Mastectomy (SRM) and reconstruction with silicone breast implant (Bostwick Technique).

DISCUSSION AND CONCLUSION: In selected patients with large sized breasts (C-D cup) and poor surface area of skin involved, a valid technique in the treatment of this pathology is the Skin-Reducing Mastectomy and immediate reconstruction with implants (DTI = direct to implant).

© 2017 The Author(s). Published by Elsevier Ltd on behalf of IJS Publishing Group Ltd. This is an open access article under the CC BY-NC-ND license (<http://creativecommons.org/licenses/by-nc-nd/4.0/>).

1. Introduction

The phyllodes tumour of the breast comprises about 0.5% of all neoplasms of the breast, and is more frequent in females, with higher incidence among those in their 40s and 50s. It can be histologically benign (60% of cases), borderline (10–30%) or malignant (about 10%) [1,2–3].

Benign lesions tend to have a high rate of recurrence so wide margins (approximately 1 cm) are always made during the exeresis, while the malignant forms are framed as sarcomas (cystosarcoma phyllodes) which have rapid growth and a tendency to metastasize via the blood [4].

In medium or small sized breasts, the extensive excision may lead to the need for a Skin-Nipple Sparing Mastectomy (if the lesion is 2 cm from the nipple areola complex), while in larger breasts it might be necessary to perform a Skin-Reducing Mastectomy (SRM) [5].

We present the case of a female patient (55 years old) suffering from giant phyllodes tumour (>10 cm) of the left breast, who underwent SRM and reconstruction with silicone breast implant (Fig. 1). The work has been reported in line with the SCARE criteria [6].

2. Case report

In January 2014 a 55-year-old female patient, not smoking with no comorbidity, came to our attention, presenting a subcutaneous lesion of the left breast that had grown rapidly over the past three months; breast tenderness was reported. On palpation, the mass appeared to have a hard, elastic consistency with a lack of mobility in the deep layers, and which distorted the normal breast profile.

The patient had not undergone regular mammography screening and checks; her last check-up, which dated back to about three years previously, showed a negative result for nodular disease. A mammography and ultrasound examination, which were immediately performed, highlighted the presence of a nodular lesion suggesting phyllodes tumour of the breast; the tumour exceeded 21 cm in diameter and involved 80% of the left breast (Fig. 2). The imaging tests on the contralateral breast produced negative results of nodular disease. Given the size of the neoformation phyllodes, extensive removal and reconstruction with breast implants were programmed; with the patient's agreement, we decided to perform a Skin-Reducing Mastectomy, saving the nipple areola complex (NAC), given the distance (>2 cm) of this from the mass. The contralateral breast was matched with inferior central pedicle breast reduction [7].

Consent, for the publication of this case report and any additional related information was taken from the patient involved in the study.

* Corresponding author at: Department of Plastic and Reconstructive Surgery, Foggia, CAP 71122 Viale Pinto n1, Italy.

E-mail address: francescociancio01@gmail.com (F. Ciancio).

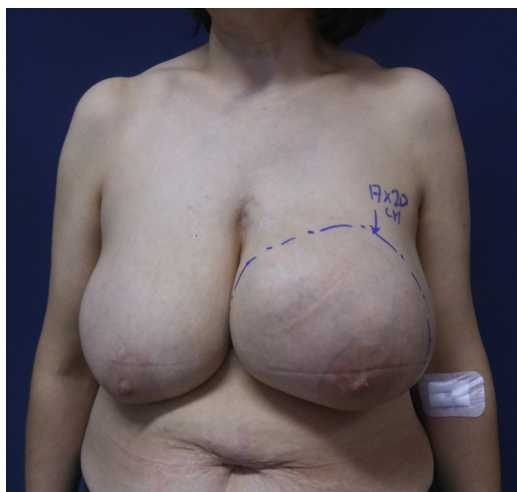

Fig. 1. female patient (55 years old) suffering from giant phyllodes tumour (>10 cm) of the left breast.

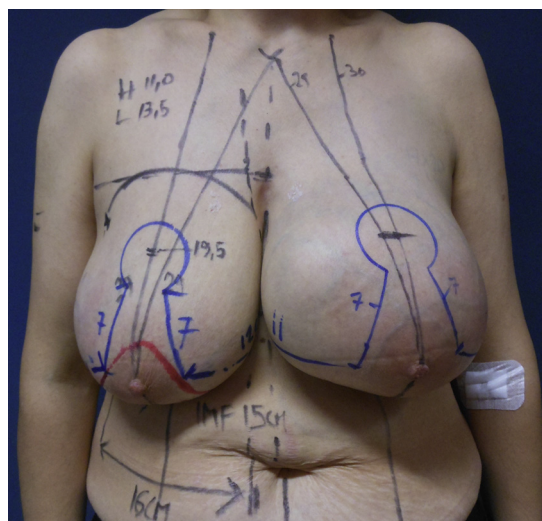


Fig. 3. preoperative marking.

3. Preoperative marking

With the patient standing up, the preoperative marking was made; first, the infra-mammary folds were identified, and then the sternal vertical line and midclavicular lines. The repositioning of the nipple-areola complex was established at about 19–20 cm from the sternal jugular notch, and finally a keyhole Wise pattern was drawn. Moreover, the dermal flap of the lower pole covering was also identified according to the Bostwick technique (Fig. 3) [8].

4. Surgical technique (Video)

The patient was placed on the operating table in the supine position with arms extended along the body. Local infiltration of incision lines with a 500-ml saline solution with 10 ml of Ropivacaine hydrochloride (Naropin, 7.5 mg/ml; AstraZeneca, London, United Kingdom), 20 ml of 2% lidocaine, adrenaline and 1 ml of 1 mg/ml was performed. The nipple areola complex was marked with areolotomo 42 mm, and preparation was made of a dermal flap of the lower pole of the breast. Following the creation of the dermal flap covering (approximately 15 cm long, 10 cm high and 4 mm

thick), the skin was cut following the preoperative marks. Dieresis of soft tissue and subcutaneous mastectomy were carried out, saving the areola nipple complex which was subsequently grafted on. The breast was removed en-bloc together with the neoplastic mass component, while the excess skin was excised in the form of a reversed “C”. Dissection of skin flaps should be kept at least 2 cm thick and stop 2–3 cm from the chest wall to avoid damage to intercostal and internal mammary perforators and thoracoacromial vessels.

A prosthetic submuscular pocket was prepared with incision of the pectoralis major muscle along its lower margin, and blunt dissection of it was carried out up to approximately 2 cm from the upper margin (Fig. 4). We positioned the chosen prosthetic implant (410 LX, 365 g) in the myo-dermal pocket and proceeded to suture the bottom margin of the pectoralis major muscle to the dermal flap covering with stitches of Vycril 2-0 absorbable. The areola was grafted into the keyhole with 4-0 interrupted nylon sutures and tie-over, and the medial and lateral skin flaps and skin closing were completed by two-layer interrupting 3-0 Vicryl (Ethicon, Inc., Somerville, N.J.) and 3-0 Prolene (Ethicon) sutures. Two suc-

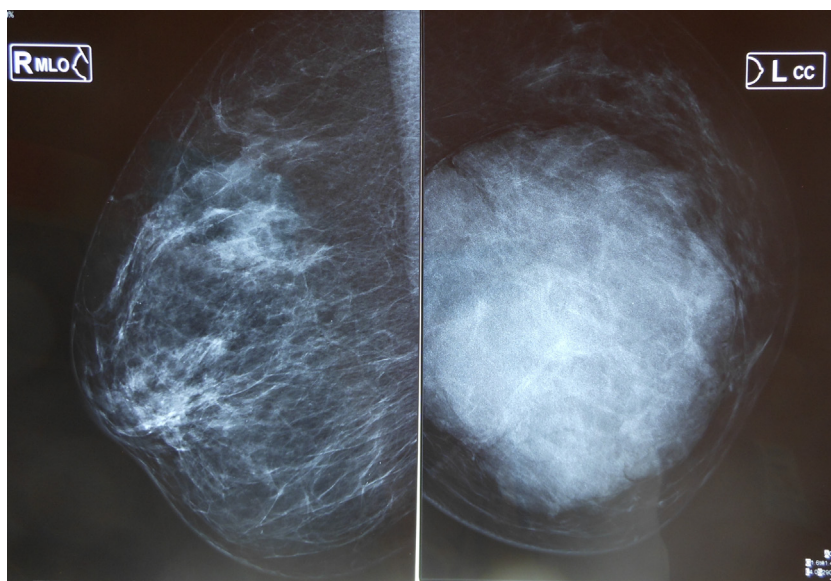


Fig. 2. bilateral mammography of breasts. It is noted the presence of a mass that involves 80% of the left breast.

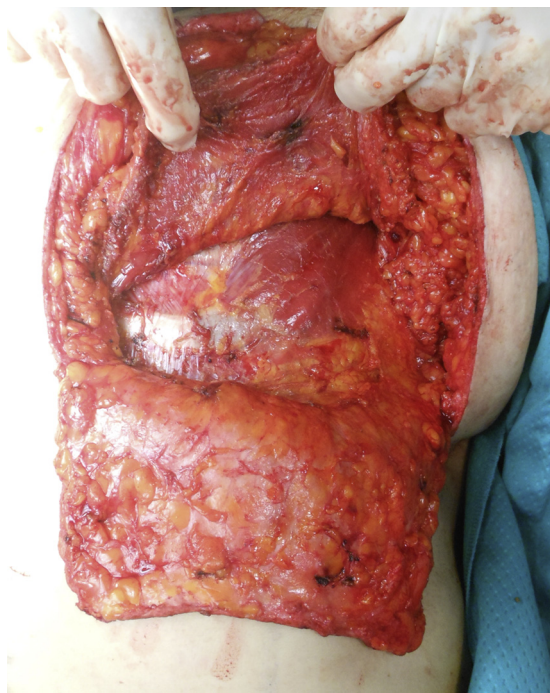


Fig. 4. preparation of the prosthesis pocket. Below you note the dermal flap to the lower pole, above the pectoralis major muscle.

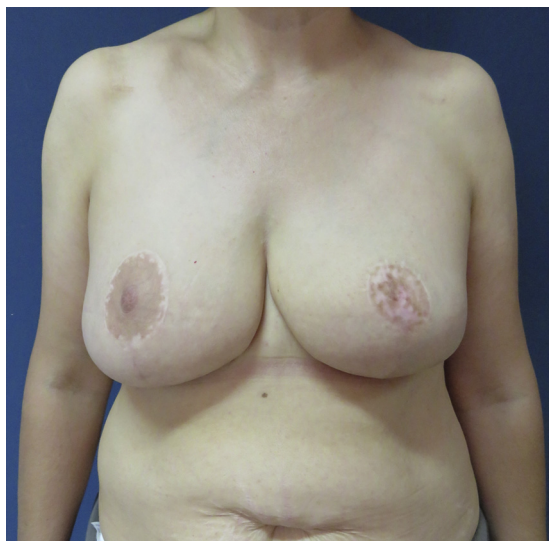

Fig. 5. photographic control at 1 year.

tion drains were placed in the myo-dermal pocket. The incision lines were taped with SteriStrips™ (3MTM Corporate Headquarters, 3M Center, St. Paul, MN, US), and loose dry dressings were applied. Antibiotic prophylaxis of 2 g of cefazolin iv was performed approximately 30 min before the start of surgery.

The surgical times were divided into two phases: the removal phase of approximately 108 min and the reconstructive phase of about 70 min. The patient had a good post-surgical recovery with no complications; she was hospitalized for five days, strictly followed the instructions received and wore a containment bra and an elastic band for 30 days. After a period of about 35 days she resumed sports activities. After 14 days histological examination reported a giant phyllodes tumour of the breast. Despite the large size, the tumor was benign.

After a year, the result is good and the patient is satisfied (Fig. 5).

5. Discussion and conclusion

The giant phyllodes tumour of the breast (>10 cm) is a challenge for the plastic surgeon, who often has to conduct extensive removal given the high rate of recurrence of this cancer. In selected patients with large sized breasts (C-D cup) and poor surface area of skin involved, a valid technique in the treatment of this pathology is the Skin-Reducing Mastectomy and immediate reconstruction with implants (DTI = direct to implant) [9,10].

The advantages offered by this technique lie in the possibility of conducting extensive removal with immediate breast reconstruction; moreover, when the tumour is located more than 2 cm away from the nipple-areola complex it is possible to save it. Preoperative planning is essential in the execution of this technique; in fact, through careful analysis of the physical characteristics of the breast, of the body and the patient's needs, it is possible to choose the ideal prosthesis (with a reasonable intra-operative variability). Mammography and ultrasound allowed us to exclude extensive skin involvement of the neoplasm, and so we opted for immediate reconstruction with implants.

A good alternative is the reconstruction with autologous tissues but this involves greater difficulties [11,12]. In our clinical practice we have treated giant phyllodes tumours of the breast where it is necessary to perform extensive skin removal. In these cases we use pedicle myocutaneous flaps, such as latissimus dorsi or rectus abdominis flap. These are surgical procedures involving increased morbidity for the patient, a longer post-operative course and a greater biological cost compared to immediate reconstruction with implants; for these reasons, in selected cases like the one just discussed, we believe that immediate reconstruction with implants may offer a viable alternative to these procedures [13,14].

Immediate breast reconstruction, rather than at a later stage, has the great advantage of producing a lower psychological impact on the patient [15,16].

SRM on benign neoplasms is very rare in the literature, since the size of this benign tumor is abnormal with respect to the nature of the same. It should be emphasized that, in the specific case, the use of unusual reconstructive techniques for benign pathologies has been fundamental in the management of this patient. Finally we can state that breast reconstruction after SRM has been largely accepted by the patient despite the benign nature of the mass, so the approach taken was not excessive.

The phyllodes tumour of the breast has a high tendency to recurrence, and metastasis via the blood in malignant forms. Surgeons are often forced to perform mastectomy to treat this disease, if it has not been caught in time and has increased in size. Adequate screening mammography/annual ultrasound in women over 40 years old could identify these tumours at an early stage and avoid extensive breast removal.

Conflicts of interest

the authors have no conflicts of interest to disclose.

Funding

Authors have not received funding or sponsor for paper production.

Ethical approval

To carry out this scientific work, there was no need to resort to the ethics committee.

Consent

Written informed consent was obtained from the patient for publication of this case report and accompanying images. A copy of the written consent is available for review by the Editor-in-Chief of this journal on request.

Author contribution

All the authors contributed equally to the writing of the paper.

Guarantor

Francesco Ciancio MD.

Appendix A. Supplementary data

Supplementary data associated with this article can be found, in the online version, at <https://doi.org/10.1016/j.ijscr.2017.11.009>.

References

- [1] M.S. Lenhard, S. Kahlert, I. Himsl, Phyllodes tumour of the breast: clinical follow-up of 33 cases of this rare disease, *Eur. J. Obstet. Gynecol. Reprod. Biol.* 138 (2) (2008) 217–221 [CrossRefPubMedGoogle Scholar](https://pubmed.ncbi.nlm.nih.gov/18111111/).
- [2] E. Guillot, B. Couturaud, F. Reyrol, Management of phyllodes breast tumors, *Breast J.* 17 (2) (2011) 129–137.
- [3] M. Nomura, Y. Inoue, S. Fujita, et al., A case of noninvasive ductal carcinoma arising in malignant phyllodes tumor, *Breast Cancer* 13 (1) (2006) 89–94, <http://dx.doi.org/10.2325/jbcs.13.89>.
- [4] M.A. Atalla, W.M. Rozen, et al., Recurrent phyllodes tumor of the breast: defining the role for skin-sparing mastectomy and autologous reconstruction, *J. Reconstr. Microsurg.* 27 (4) (2016) 267–272.
- [5] G. Singh, R.K. Sharma, Immediate breast reconstruction for phyllodes tumors, *Breast* 17 (3) (2008) 296–301.
- [6] R.A. Agha, A.J. Fowler, A. Saetta, I. Barai, S. Rajmohan, D.P. Orgill, SCARE Group, The SCARE Statement: Consensus-based surgical case report guidelines, *Int. J. Surg.* (2016).
- [7] A. Portincasa, F. Ciancio, et al., Septum-Enhanced mammoplasty in inferocentral pedicled Breast reduction for macromastia and gigantomastia patients, *Aesthet. Plast. Surg.* (2017), <http://dx.doi.org/10.1007/s00266-017-0868-1>, in press.
- [8] J. Bostwick, Total mastectomy with breast skin and volume reduction using an inverted 'T' incision, in: *Plastic and Recon-Structive Breast Surgery St Louis, Quality Medical Publisher Inc., 1990*.
- [9] G.W. Irwin, A. Black, et al., Skin-reducing mastectomy and one-stage implant reconstruction with a myodermal flap: a safe and effective technique in risk-reducing and therapeutic mastectomy, *J. Plast. Reconstr. Aesthet. Surg.* 66 (9) (2013) 1188–1194, <http://dx.doi.org/10.1016/j.bjps.2013.04.048>.
- [10] P. Püzl, T. Schoeller, et al., Unilateral breast enlargement 5 years after reduction mammoplasty, *Aesthet. Plast. Surg.* 29 (5) (2005) 404–406, <http://dx.doi.org/10.1007/s00266-005-0043-y>.
- [11] C.-L. Fang, C.-H. Hsu, C.-W. Tu, The reconstruction choice for giant phyllodes tumor of Breast: Bi-pedicled deep inferior epigastric perforator flap, *Aesthet. Plast. Surg.* (2017) 4–8, <http://dx.doi.org/10.1007/s00266-017-0792-4>.
- [12] K. Yano, K. Hosokawa, Nakai, et al., Skin-sparing mastectomy and immediate reconstruction with a deep inferior epigastric perforator flap, *Breast Cancer* 10 (3) (2003) 275–280, <http://dx.doi.org/10.1007/BF02966729>.
- [13] P. Veronesi, F. De Lorenzi, et al., Current trends in the oncologic and surgical managements of Breast cancer in women with implants: incidence, diagnosis, and treatment, *Aesthet. Plast. Surg.* 40 (April (2)) (2016) 256–265, <http://dx.doi.org/10.1007/s00266-016-0612-2> (Epub 2016 Feb).
- [14] G. Lo Russo, F. Spolveri, F. Ciancio, A. Mori, Mendeley: an easy way to manage, share, and synchronize papers and citations, *Plast. Reconstr. Surg.* 131 (6) (2013), <http://dx.doi.org/10.1097/PRS.0b013e31828bd400>, 946e–7e.
- [15] A. Innocenti, F. Mori, D. Melita, E. Dreassi, F. Ciancio, M. Innocenti, Evaluation of long-term outcomes of correction of severe blepharoptosis with advancement of external levator muscle complex: descriptive statistical analysis of the results, *Vivo* 31 (1) (2017) 111–115, <http://dx.doi.org/10.21873/invivo.11032>.
- [16] F. Ciancio, D. Parisi, A. Portincasa, A. Innocenti, Discussion: a new method of salvaging breast reconstruction after breast implant using negative-pressure wound therapy and instillation, *Aesthet. Plast. Surg.* (2016), <http://dx.doi.org/10.1007/s00266-016-0734-6>.

Open Access

This article is published Open Access at [sciencedirect.com](https://www.sciencedirect.com). It is distributed under the [IJSCR Supplemental terms and conditions](#), which permits unrestricted non commercial use, distribution, and reproduction in any medium, provided the original authors and source are credited.