


Available online at www.sciencedirect.com

ScienceDirect

journal homepage: <http://www.pediatr-neonatol.com>

Short Communication

Congenital tuberculosis after *in vitro* fertilization presenting with endobronchial granuloma

Elisabetta Venturini ^a, Carlotta Montagnani ^a, Antonio Boldrini ^b,
 Marco Moroni ^c, Elena Chiappini ^a, Maurizio de Martino ^a,
 Luisa Galli ^{a,*}

^a Department of Health Sciences, University of Florence, Meyer Children's University Hospital, Florence, Italy

^b U.O. Neonatology, Azienda Ospedaliero-Universitaria Pisana, Pisa, Italy

^c Neonatal Intensive Care Unit, Department of Pediatrics, Meyer Children's University Hospital, Florence, Italy

Received Feb 22, 2017; received in revised form Oct 28, 2017; accepted Feb 2, 2018
 Available online 7 February 2018

1. Background

Congenital tuberculosis (TB) is a rare and severe presentation of *Mycobacterium tuberculosis* infection. The infection may be transmitted to the fetus by hematogenous spread from the placenta or by the aspiration or ingestion of contaminated amniotic fluid at delivery. Mortality of congenital TB is very high at 50% of untreated infants and 20% of those receiving therapy. The diagnosis is based on revised criteria by Cantwell. Early diagnosis of congenital

TB is challenging because of nonspecific symptoms and poor sensitivity of diagnostic tests such as the tuberculin skin test (TST) and interferon- γ release assay.¹ Endobronchial TB is quite common in children, although the incidence is unknown because bronchoscopy is not routinely performed. However, studies report bronchial involvement in 41%–63% of children with suspected TB.

2. Case report

We present a case of congenital TB in a twin female. She was born prematurely at 27 weeks of gestation from a dichorionic diamniotic twin pregnancy after *in vitro* fertilization. After birth, she developed respiratory distress, and subsequently she was mechanically ventilated for 3 days. At 4 weeks of age, she developed a progressively worsening dyspnea that required ventilation with nasal continuous positive airway pressure. She was started with broad-spectrum antibiotics. Her twin sister died 60 days after birth as a result of respiratory distress and sepsis. The postmortem examination revealed disseminated TB.

List of abbreviation: TB, tuberculosis; TST, tuberculin skin test.

* Corresponding author. Department of Health Sciences, University of Florence, Pediatric Infectious Diseases Division, Department of Pediatric Medicine, Meyer Children's University Hospital, viale Pieraccini 24, I-50139, Florence, Italy. Fax: +39 0555662830.

E-mail addresses: elisabetta-venturini@virgilio.it (E. Venturini), carlottamontagnani@hotmail.it (C. Montagnani), a.boldrini@med.unipi.it (A. Boldrini), marco.moroni@meyer.it (M. Moroni), elena.chiappini@unifi.it (E. Chiappini), maurizio.demartino@unifi.it (M. de Martino), luisa.galli@unifi.it (L. Galli).

<https://doi.org/10.1016/j.pedneo.2018.02.001>

1875-9572/Copyright © 2018, Taiwan Pediatric Association. Published by Elsevier Taiwan LLC. This is an open access article under the CC BY-NC-ND license (<http://creativecommons.org/licenses/by-nc-nd/4.0/>).

The analysis of the mother's placenta showed acid-fast bacilli. The results of a TST and a QuantiFERON®-TB Gold In-Tube test (Quest Diagnostics, Secaucus, NJ) were negative. Gastric aspiration was performed and revealed negative results for acid-fast bacilli, but the results of culture and polymerase chain reaction were positive for *M. tuberculosis*. Therefore, the infant was transferred to our tertiary care children's university hospital. The result of an abdominal ultrasound was normal, and no growth of *M. tuberculosis* was found in the cerebrospinal fluid, blood, or urine. Treatment with isoniazid (10 mg/kg/d), rifampicin (20 mg/kg/d), pyrazinamide (30 mg/kg/d), ethambutol (15 mg/kg/d), and prednisone (1 mg/kg/d) was started. The treatment was well tolerated, and the patient was discharged to home with follow-up at the infectious diseases unit of our hospital. Antimicrobial sensitivities were available after 5 weeks of incubation, and they showed resistance to pyrazinamide. Prednisone was stopped after 1 month of treatment as was pyrazinamide owing to sensitivities, whereas ethambutol was continued for a total of 2 months.

At 4 months of age, the girl started to present mild intermittent respiratory distress. She was initially treated with nebulized adrenalin and oral betamethasone. Subsequently, she was readmitted to our hospital because of cervical lymphadenopathy, which drained spontaneously. A chest x-ray was done for increasing respiratory distress, and a complete opacity of the right lung with mild mediastinal shift was found (Fig. 1). Computed tomography revealed multiple enlarged mediastinal and subpleural lymph nodes with central hypodensity and atelectasis of the right lung. The patient was started back on prednisone and ethambutol. However, 2 weeks later she developed respiratory worsening, and bronchoscopy revealed a complete luminal obstruction of the right main bronchus caused by tuberculous granuloma (Fig. 2). Endobronchial treatment was performed with the patient under general anesthesia with a rigid bronchoscope and using a diode laser. The interventional bronchoscopy led to prompt clinical improvement.

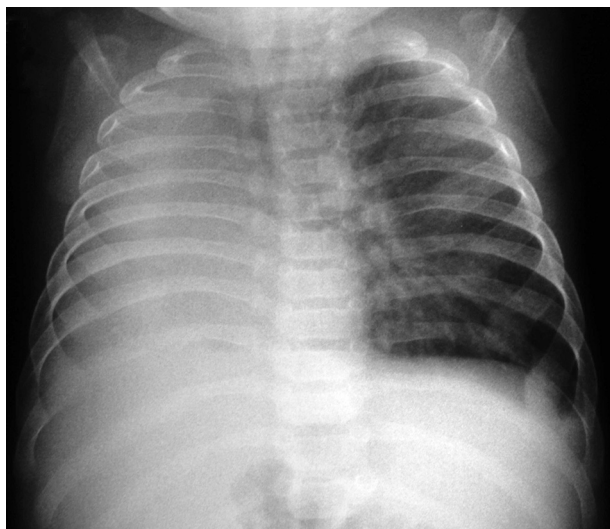


Figure 1 Chest x-ray showing a complete opacity of the right lung with mild mediastinal shift toward the affected side.

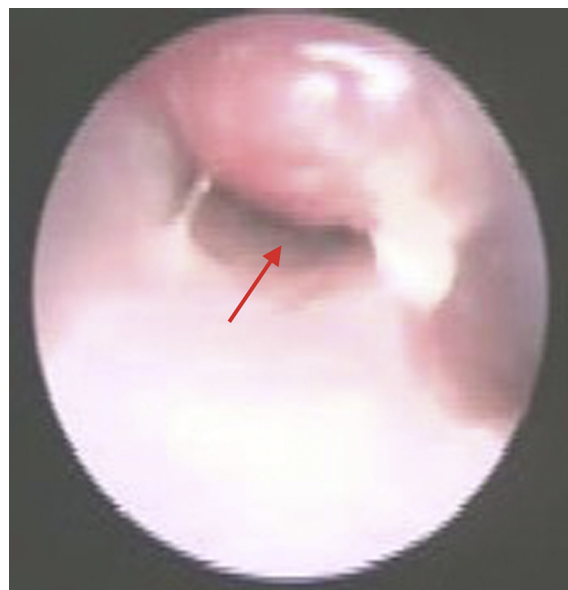

Figure 2 Bronchoscopy showing luminal obstruction of the right main bronchus caused by tuberculous granuloma.

At 9 months of age, another therapeutic bronchoscopy with clearance of a new granuloma of the right bronchus was required. Prednisone was stopped after 3 months, and the antituberculous drugs were stopped after 15 months of treatment. The result of follow-up bronchoscopy at 2 years of age was normal, and a chest x-ray showed nearly complete resolution of the TB lesions. At 6-year follow-up, the patient was developing well and was completely asymptomatic.

3. Discussion

Endobronchial TB is quite common in children, although the real incidence is unknown. To our knowledge, this is the first case of congenital TB with endobronchial granuloma successfully treated with therapeutic bronchoscopy. There are few techniques available to relieve tracheobronchial stenosis caused by endobronchial TB, including laser, cryosurgery, controlled heat application, balloon dilation, and stent insertion.² Laser energy, delivered via rigid or flexible bronchoscopes, is able to vaporize the granulomatous tissue. The main indications of this technique are obstructive lesions of the trachea, the left and right main bronchi, and the bronchus intermedius. This procedure requires specific training and expensive equipment, but complications are rare.²

Congenital TB after *in vitro* fertilization is an extremely rare occurrence. Fourteen cases have been reported in the literature worldwide to date.^{1,3–8} Genitourinary TB in women is an important cause of infertility, especially for women living in endemic countries, where it represents 3%–17% of all causes of TB. With the increasing availability of assisted reproductive technology, infertile women may become pregnant, which may lead to congenital TB infection in their neonates.¹ Three other sets of twins with congenital TB following *in vitro* fertilization have been reported.^{3,6}

In conclusion, the diagnosis of congenital TB should be considered in any neonate with pneumonia who fails to

respond to conventional treatment and supportive therapy. The diode laser is effective in removing endobronchial granulomas and can be used in cases of severe atelectasis, respiratory distress, or persistent obstruction despite the antitubercular treatment. We also wish to draw attention to the importance of searching for genital TB as the possible cause of congenital infection, even if the mother is asymptomatic. Preconception identification and treatment of female genital tract TB could prevent congenital infection.

Conflict of interest

The authors declare that they have no competing interests.

References

1. Zheng Y, Bai G, Zhang H. Congenital tuberculosis detected by T-SPOT.TB assay in a male infant after *in vitro* fertilization and followed up with radiography. *Ital J Pediatr* 2014;**40**:96.
2. Kashyap S, Solanki A. Challenges in endobronchial tuberculosis: from diagnosis to management. *Pulm Med* 2014;**2014**:594806.
3. Flibotte JJ, Lee GE, Buser GL, Feja KN, Kreiswirth BN, McSherry GD, et al. Infertility, *in vitro* fertilization and congenital tuberculosis. *J Perinatol* 2013;**33**:565–8.
4. Gleeson LE, Varghese C, Ryan E, Kane M, McDonald C, Gleeson N, et al. Untreated chronic tuberculous salpingitis followed by successful *in vitro* fertilization conception and congenital tuberculosis. *QJM* 2015;**108**:899–901.
5. Stuart RL, Lewis A, Ramsden CA, Doherty RR. Congenital tuberculosis after *in-vitro* fertilisation. *Med J Aust* 2009;**191**:41–2.
6. Altunhan H, Keser M, Pekcan S, Ural O, Ors R. Congenital tuberculosis in premature twins after *in vitro* fertilisation. *BMJ Case Rep* 2009;**2009**.
7. Mony VK, Polin J, Adler E, Munjal I, LaTuga MS, Kojaoghlanian T. Congenital tuberculosis: a missed opportunity. *J Pediatric Infect Dis Soc* 2014;**3**:e45–7.
8. Emiralioglu N, Dogru D, Oguz B, Yalcin E, Ozcelik U, Konuskan B, et al. Congenital tuberculosis after *in-vitro* fertilization in a woman previously undiagnosed with tuberculosis salpingitis. *Pediatr Neonatol* 2016;**57**:539–40.