



UNIVERSITÀ
DEGLI STUDI
FIRENZE

FLORE

Repository istituzionale dell'Università degli Studi di Firenze

Spontaneous Resolution of an Acquired Uterine Arteriovenous Malformation in an Elderly Primigravida

Questa è la Versione finale referata (Post print/Accepted manuscript) della seguente pubblicazione:

Original Citation:

Spontaneous Resolution of an Acquired Uterine Arteriovenous Malformation in an Elderly Primigravida / Ghizzoni, Viola; Gabbrielli, Silvia; Mannini, Luca; Sorbi, Flavia; Turrini, Irene; Fantappiè, Giulia; Pavone, Dora; Fambrini, Massimiliano; Noci, Ivo. - In: THE AMERICAN JOURNAL OF CASE REPORTS. - ISSN 1941-5923. - STAMPA. - 19:(2018), pp. 1140-1145. [10.12659/AJCR.909635]

Availability:

This version is available at: 2158/1149295 since: 2020-11-02T14:45:43Z

Published version:

DOI: 10.12659/AJCR.909635

Terms of use:

Open Access

La pubblicazione è resa disponibile sotto le norme e i termini della licenza di deposito, secondo quanto stabilito dalla Policy per l'accesso aperto dell'Università degli Studi di Firenze (<https://www.sba.unifi.it/upload/policy-oa-2016-1.pdf>)

Publisher copyright claim:

(Article begins on next page)

Received: 2018.02.25
Accepted: 2018.06.12
Published: 2018.09.27

e-ISSN 1941-5923
© Am J Case Rep, 2018; 19: 1140-1145
DOI: 10.12659/AJCR.909635

Spontaneous Resolution of an Acquired Uterine Arteriovenous Malformation in an Elderly Primigravida

Authors' Contribution:
Study Design A
Data Collection B
Statistical Analysis C
Data Interpretation D
Manuscript Preparation E
Literature Search F
Funds Collection G

BEF 1 **Viola Ghizzoni**
AB 2 **Silvia Gabbrielli**
BE 1 **Luca Mannini**
ADE 1 **Flavia Sorbi**
BF 1 **Irene Turrini**
F 1 **Giulia Fantappiè**
F 1 **Dora Pavone**
A 1 **Massimiliano Fambrini**
AEF 1 **Ivo Noci**

1 Department of Biomedical Clinical and Experimental Sciences, University of Florence, Florence, Italy
2 Department of Radiodiagnostics, Careggi Hospital, Florence, Italy

Corresponding Author: Irene Turrini, e-mail: irene.turrini@gmail.com
Conflict of interest: None declared

Patient: Female, 65
Final Diagnosis: Acquired uterine arteriovenous malformation
Symptoms: Vaginal bleeding
Medication: —
Clinical Procedure: Wait and see
Specialty: Obstetrics and Gynecology





Objective: Rare disease
Background: Uterine arteriovenous malformation (AVM) is an uncommon lesion characterized by an abnormal connection between arterial and venous circulation that can be congenital or acquired. Acquired uterine AVMs are generally traumatic and follow delivery, abortion, curettage, or uterine surgery.

Case Report: A 45-year-old female who was gravida 1 para 0 presented to our hospital with severe vaginal bleeding. Two weeks before, the patient underwent therapeutic abortion. At admission, a transvaginal ultrasound showed an unclear intrauterine lesion that spread out to the myometrium. Color Doppler evaluation demonstrated an elevated color score. Beta human chorionic gonadotropin (beta-hCG) levels were measured at admission and daily repeated, with a progressive decrease of values up to a negative level. A pelvic magnetic resonance imaging described an area of tubular and tortuous structures involving the myometrium. A computed tomography angiography confirmed the presence of a lesion infiltrating the endometrium and myometrium containing arteriovenous structures with a highly enhanced effect. Despite these findings, the patient was clinically stable. A diagnosis of uterine AVM was made and, after accurate counselling with the patient, she was discharged and underwent “watch and wait” management. After 35 days, the patient had a follow-up ultrasound that showed a complete resolution of the uterine lesion.

Conclusions: AVM should be considered in the presence of heavy and sudden vaginal bleeding in a patient with risk factors for acquired AVM. A color Doppler ultrasound scan should be performed as the first approach and an expectant management should be taken into account especially with a patient of childbearing age and hemodynamic instability.

MeSH Keywords: Arteriovenous Malformations • Dilatation and Curettage • Uterine Artery Embolization • Uterine Hemorrhage

Full-text PDF: <https://www.amjcaserep.com/abstract/index/idArt/909635>

 1603   6  13



Background

Uterine arteriovenous malformation (AVM) is an uncommon lesion characterized by an abnormal connection between arterial and venous circulation [1]. There can be congenital or acquired uterine AVM. Congenital forms are very rare and usually develop anomalies that exhibit histologic similarities to AVMs found at other sites with sometimes extensive extrauterine involvement. Acquired uterine AVMs are generally secondary to iatrogenic intrauterine procedures such as curettage or uterine surgery or pregnancy-related changes following delivery or abortion. The pathogenesis is thought to be dependent on shunting of blood from the capillary plexus to the less resistant venous system, possibly resulting in fistula formation after uterine procedures [2]. Patients with uterine AVM might be asymptomatic, although uterine AVMs generally cause abnormal vaginal bleeding. Diagnosis is performed with color Doppler ultrasound scan; angiography is the gold standard.

Uterine AVMs are in some cases followed up without interventions. Uterine artery embolization (UAE) may be indicated for unremitting uterine bleeding, although this technique is more often used to treat uterine symptomatic fibroids or adenomyosis. While the effect of UAE on fertility and pregnancy is unclear; it can be associated with risk of ovarian insufficiency and placental abnormalities during subsequent pregnancies [3]. Medical treatment is another therapeutic option.

We report a case of spontaneous resolution of acquired AVM following a therapeutic abortion; the AVM was managed with watchful waiting.

Case Report

A 45-year-old female who was gravida 1 para 0 presented to our tertiary care center with severe vaginal bleeding. Two weeks before, the patient had undergone a therapeutic abortion for fetal acrania. The procedure was performed with dilatation and curettage (D&C) under ultrasound control, which showed at the end of procedure a thin, not hypervascular endometrium. The patient's family history was negative for cardiovascular diseases and thrombotic disorders, and her medical history included previous laparoscopy for ovarian endometriosis and hysteroscopic polypectomy. Previously, the patient underwent an ultrasound examination and hysterosalpingography due to prolonged time of subfertility, and both examinations were negative for uterine pathology.

At admission, clinical examination of the abdomen was negative, while vaginal examination showed severe vaginal bleeding and an enlarged uterus. The patient's body temperature was 36.3°C, blood pressure was 130/80 mm Hg, heart rate was 65 bpm with regular rhythm, and oxygen saturation was 100%. Blood tests were normal with regular leukocytes count ($6.2 \times 10^9/L$), regular platelets count, normal coagulation set, and hemoglobin level equal to 12.5 g/dL.

A first level transvaginal ultrasound examination was performed on admission and showed a complex intrauterine lesion that spread through the myometrium. Color Doppler evaluation showed an elevated score (color score 4). Furthermore, the lesion was next to an intramural myoma. No intraperitoneal free fluid was registered (Figure 1).

The patient was admitted to our Gynecological Unit in order to investigate the aforementioned findings. In the suspicion of gestational trophoblastic disease or retained material of conception after the abortion, beta human chorionic gonadotropin

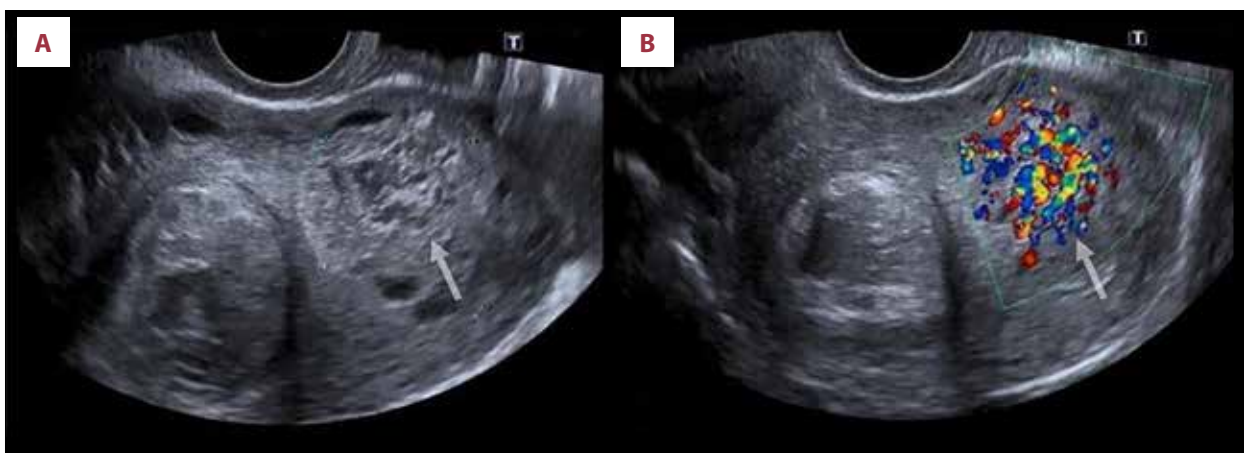


Figure 1. Transvaginal sonography without (A) and with (B) color Doppler imaging. A complex intrauterine lesion that spread through the myometrium (arrow) with color Doppler score 4. A fibroma was also detected near this hypervascular lesion.

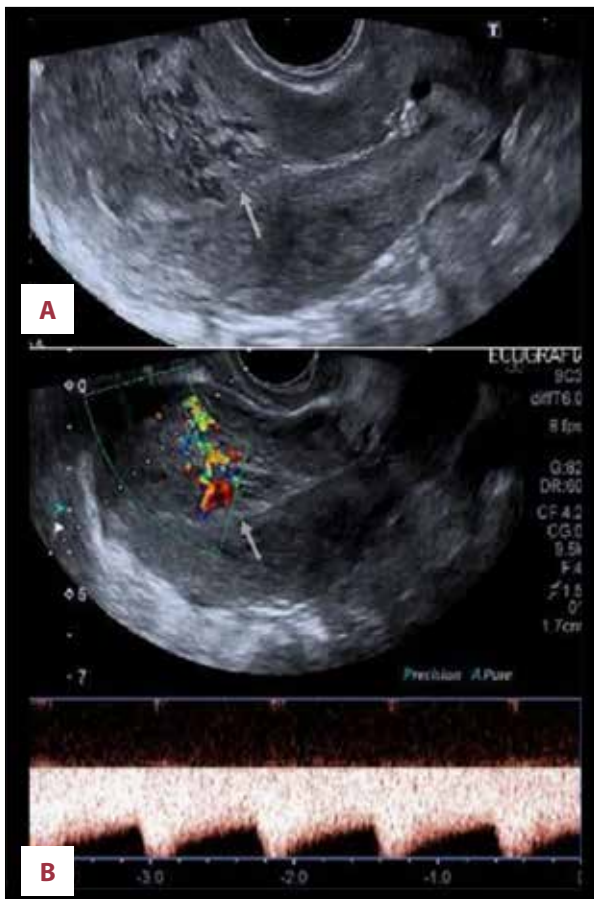


Figure 2. Color and spectral Doppler sonograms. A tangle of vessels (arrow) with multidirectional, turbulent flow with a color mosaic pattern (A) and a high flow, low resistance blood flow pattern (B).

(beta-hCG) were drawn on admission. Beta-hCG were 25 U/L on first measurement, and measurements were repeated during hospitalization with a progressive decrease of values up to

a negative level. Vaginal bleeding stopped after admission, but the patient remained hospitalized to obtain a certain diagnosis.

On the second day of admission, a second level transvaginal ultrasound scan was performed and confirmed not only the presence of a marked inhomogeneous area of tortuous and tangled vessels in the anterior wall extending from the endometrium to the myometrial without interruption, but also the presence of hemorrhagic fluid with internal thread-like structures, representing fibrin strands, in the pouch of Douglas (Figures 1, 2). Afterwards, a pelvic magnetic resonance imaging (MRI) study confirmed the aforementioned lesion, described as an area of tubular and tortuous structures involving the whole myometrial anterior wall of the uterus with a 3.5 cm thickness and not well-defined borders. After intravenous administration of paramagnetic contrast agent (Multihance, 11 mL), we observed a progressive enhancement in the dynamic sequences of the lesion (Figure 3).

Five days later, following the radiologist's indications, a computed tomography angiography (CTA) was performed to further assess the nature of the lesion. CTA revealed the presence of a hypervascular lesion inside endometrium and myometrium containing arteriovenous structures with a highly enhanced effect (Figures 4, 5).

Due to these findings, the diagnosis of uterine AVM was made. Since the patient was clinically and hemodynamically in stable condition, we decided, in consultation with the patient, to undergo watchful waiting management.

Indeed, the patient was strongly motivated to have a future pregnancy and after accurate counselling, she refused to undergo invasive procedures such as hysteroscopy or D&C if not strictly necessary, due to the possibility of complications eventually leading also to a possible hysterectomy. We agreed to

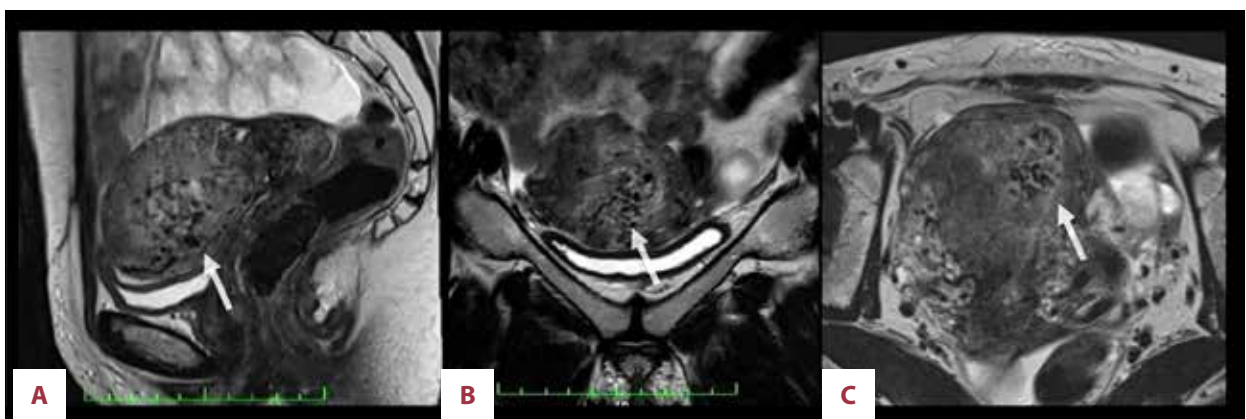


Figure 3. Pelvic MRI: sagittal (A), axial (B), and coronal (C). T2-weighted TSE sequences: ill-defined mass (arrow) of multiple vascular-like serpiginous structures with flow void involving the whole myometrial anterior wall of the uterus. MRI – magnetic resonance imaging; TSE – turbo spin-echo.

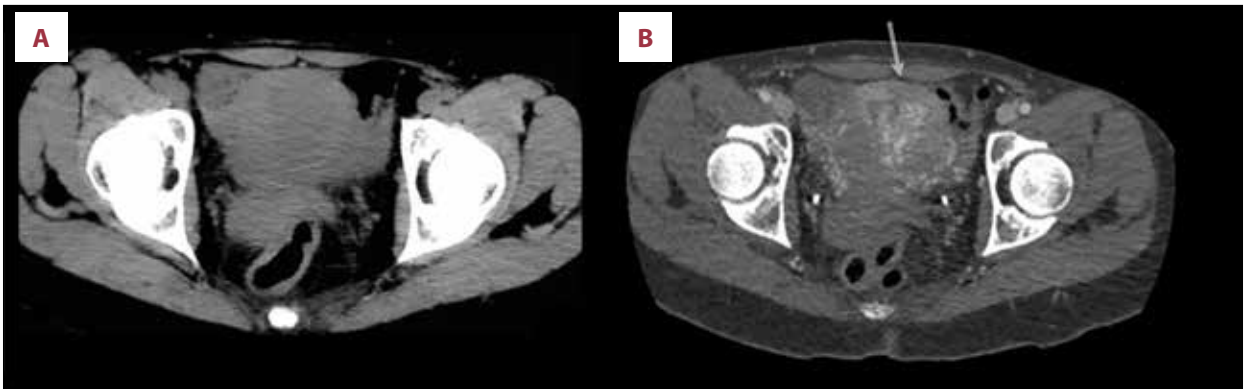


Figure 4. Computed tomography to pre-contrast IV axial scan (A) and post IV contrast arterial phase (B). An increased vascularity area (arrow) inside endometrium and myometrium with arteriovenous structures is recognizable. IV, intravenous.

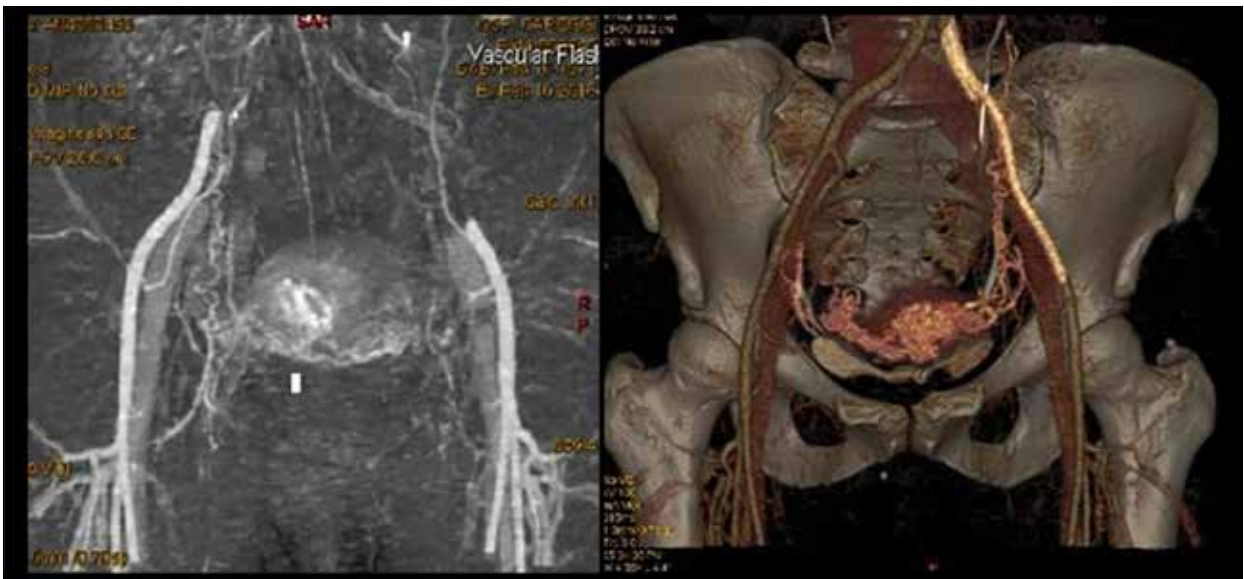


Figure 5. Computed tomography 3D-angiography: hypervascular lesion with arteriovenous shunting and a highly enhanced effect in hypertrophic and coiled vascular channels.

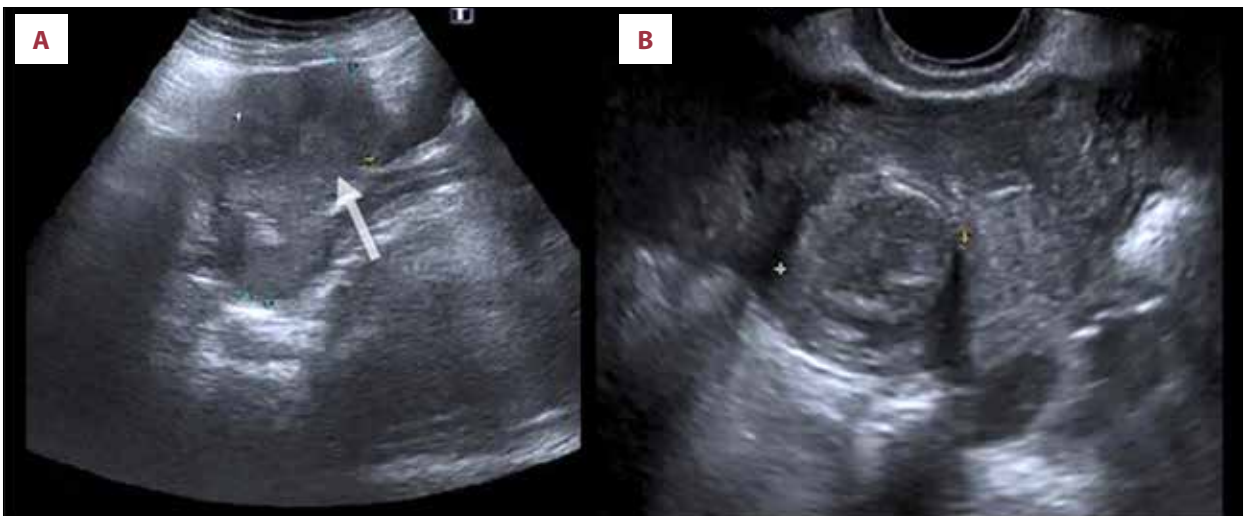


Figure 6. Pelvic ultrasound (A) and transvaginal ultrasound (B): complete resolution of the uterine lesion (arrow).

the patient desire since she was hemodynamically stable and hadn't had any more vaginal bleeding since admission. The patient was therefore discharged in day 9. After 35 days, the patient had a follow-up ultrasound that showed a complete resolution of the uterine lesion (Figure 6).

Discussion

We describe a case of acquired AVM with spontaneous resolution. Vascular uterine lesions include both congenital and acquired AVMs and are characterized by multiple abnormal connections between arteries and veins. AVMs are considered to be rare events [4], with an estimated incidence of 0.63% after abortions or delivery [4].

Congenital AVMs result from a defect in the differentiation of the primitive capillary system during fetal angiogenesis, whereas acquired AVMs are characterized by a shunt between uterine artery branches and myometrium venous plexus [1]. Generally, acquired AVMs develop from invasive procedures such as D&C, uterine surgery, delivery, or direct uterine trauma, and less commonly, endometrial cancers, gestational trophoblastic disease, fibroids, infection, intrauterine devices, or exposure to diethylstilbestrol [5]. Clinical presentations of acquired AVMs include general menorrhagia and metrorrhagia. Anemia and hypotension can be present due to blood loss. Other symptoms can be lower abdominal pain, urinary symptoms, and dyspareunia. Moreover, asymptomatic presentation is possible as well.

Diagnosis has changed in the last few decades. Indeed, in the past, AVMs were diagnosed after a hysterectomy, whereas nowadays non-invasive procedures are used for diagnosis of AVM [3]. Transvaginal ultrasounds with color Doppler-scanning is the first approach commonly used to investigate vaginal bleeding. Serpiginous vessels are usually detected with an irregular, turbulent, high-speed low-resistance blood flow [6], AVMs usually show a color score of 3 or 4. The color score, which is a subjective semi-quantitative assessment of the amount of blood flow within the examined lesion, was made according to the International Ovarian Tumor Analysis (IOTA) protocol. According to this system, a color score of 1 means that no color signal is observed within the mass, a score of 2 means that a minimal amount of color signal is detected, a score of 3 means that a moderate amount of color signal is observed, and a score of 4 means that abundant color Doppler signals are detected within the mass.

Because of multiplanar imaging and contrast media, MRIs can be used to confirm a suspected AVM. A typical MRI finding would be an enlarged uterus with an undefined mass of tortuous and dilated vessels involving the myometrium or

parametrium. Although CTA remains the gold standard imaging technique, it is an invasive approach and MR-angiography is considered comparable to evaluate the nature and the extent of the lesion [1,2]. However, CTA can give information concerning the involved vessels.

Differential diagnosis of uterine AVM includes retained products of conception and gestational trophoblastic diseases, which may give a hypervascular appearance with turbulent flow, resembling the radiologic aspect of uterine AVM. Beta-hCG levels may be helpful in diagnosis. Our patient did not have a high level or an increase in beta-hCG levels, which would be expected in gestational trophoblastic disease.

AVM management is currently under debate and depends on the degree of hemorrhage, signs of hypovolemia, and the desire of the patient for future fertility [4]. Indeed, AVMs can resolve spontaneously, although a "watch and wait" management should be chosen only in case of hemodynamic stability. In our case, the strong motivation of the patient to preserve fertility led us to choose watchful waiting since the patient's clinical condition allowed a conservative approach.

In the past, hysterectomy was the treatment of choice; however, nowadays a conservative approach is preferred. UAE has been shown to have high clinical success and a low complication rate [7]. Nevertheless, hysterectomy could be considered as the treatment of choice in post-menopausal patients and in life-threatening situations [8]. Moreover, a pharmacologic approach is another therapeutic choice, and the literature describes several medical options such as methylergometrine, gonadotropin-releasing hormone agonists, and danazol. These therapies have been used for their action in controlling bleeding [2].

In our case, the patient underwent D&C 2 weeks before profuse vaginal bleeding, and her imaging study was very suspicious for AVM. Regression of an AVM with a spontaneous resolution has been described by different authors [3,9–13]. In our case, due to the patient's hemodynamic stability and due to the absence of any further blood loss, a watchful waiting management strategy was considered safe and feasible. The acquired AVM resolved spontaneously after 35 days.

Conclusions

AVM should be considered in cases of heavy and sudden vaginal bleeding in a patient with risk factors for acquired AVM. A color Doppler ultrasound scan should be performed as the first approach and an expectant management should be taken into account especially for a patient of childbearing age who is hemodynamic instability. Uterine AVMs usually affect women

of a young age, and their treatment with UAE or hysterectomy results in a loss of fertility in those patients. We believe that guidelines should be available to assess the feasibility of an expectant management in select cases.

References:

1. Vijayakumar A, Srinivas A, Chandrashekar BM, Vijayakumar A: Uterine vascular lesions. *Rev Obstet Gynecol*, 2013; 6: 69–79
2. Yoon DJ, Jones M, Taani JA et al: A systematic review of acquired uterine arteriovenous malformations: Pathophysiology, diagnosis, and transcatheter treatment. *AJP Rep*, 2016; 6(1): e6–14
3. Keiko M, Sugiko O, Kozue A et al: Spontaneous regression of uterine arteriovenous malformations with conservative management. *Case Rep Obstet Gynecol*, 2017; 2017: 6437670
4. Yazawa H, Soeda S, Hiraiwa T et al: Prospective evaluation of the incidence of uterine vascular malformations developing after abortion or delivery. *J Minim Invasive Gynecol*, 2013; 20: 360–67
5. Tullius TG Jr., Ross JR, Flores M et al: Use of three-dimensional power doppler sonography in the diagnosis of uterine arteriovenous malformation and follow-up after uterine artery embolization: Case report and brief review of literature. *J Clin Ultrasound*, 2015; 43(5): 327–34
6. Yan X, Zhao C, Tian C et al: Ultrasound-guided high-intensity focused ultrasound ablation for treating uterine arteriovenous malformation. *BJOG*, 2017; 124(Suppl. 3): 93–96
7. Bazeries P, Paisant-Thouveny F, Yahya S et al: Uterine artery embolization for retained products of conception with marked vascularity: A safe and efficient first-line treatment. *Cardiovasc Intervent Radiol*, 2017; 40(4): 520–29
8. Chang KH, Park JK, Park SH et al: Uterine arteriovenous malformation caused by intrauterine instrumentation for laparoscopic surgery due to left tubal pregnancy. *Obstet Gynecol Sci*, 2014; 57: 419–23
9. Timmerman D, Van den Bosch T, Peeraer K et al: Vascular malformations in the uterus: Ultrasonographic diagnosis and 6 Case Reports in Obstetrics and Gynecology conservative management. *Eur J Obstet Gynecol Reprod Biol*, 2000; 92(1): 171–78
10. Sellers F, Palacios-Marques A, Moliner B, Bernabeu R: Uterine arteriovenous malformation. *BMJ Case Rep*, 2013; 2013: pii: bcr2012008443
11. Lee TY, Kim SH, Lee HJ et al: Ultrasonographic indications for conservative treatment in pregnancy-related uterine arteriovenous malformations. *Acta Radiologica*, 2014; 55(9): 1145–52
12. Dar P, Karmin I, Einstein MH: Arteriovenous malformations of the uterus: Long-term follow-up. *Gynecol Obstet Invest*, 2008; 66(3): 157–61
13. Timmerman D, Wauters J, Van Calenbergh S et al: Color Doppler imaging is a valuable tool for the diagnosis and management of uterine vascular malformations. *Ultrasound Obstet Gynecol*, 2003; 21: 570–77

Conflict of interest

None.