

Italian real-life experience on the use of ocriplasmin

Francesco Barca, Dario Pasquale Mucciolo, Tomaso Caporossi, Gianni Virgili, Ruggero Tartaro, Stanislao Rizzo, The Italian Ocriplasmin Group

To cite: Barca F, Mucciolo DP, Caporossi T, *et al.* Italian real-life experience on the use of ocriplasmin. *BMJ Open Ophthalmology* 2018;3:e000110. doi:10.1136/bmjophth-2017-000110

Received 18 August 2017
Revised 28 December 2017
Accepted 2 March 2018

ABSTRACT

Objective To evaluate the success of an intravitreal injection of ocriplasmin to release symptomatic vitreomacular traction (VMT) and close a full-thickness macular hole.

Methods and analysis An observational retrospective multicentre study conducted in Italy. Patients with symptomatic distortion and loss of vision secondary to VMT were included in the study. The patients received a single injection of ocriplasmin and were followed up for 1, 3 and 6 months. Best-corrected visual acuity (BCVA) and spectral domain OCT (SD-OCT) were performed for patient assessment, and adverse events were recorded and analysed.

Results 74 patients (74 eyes) were included in the study. 44 of 74 eyes (59.5%) experienced complete release of the VMT. Macular hole closure was obtained in eight eyes (40%). BCVA improved about three lines after 3 months of follow-up in the patients with VMT resolution in comparison with the patients who did not have VMT resolution ($p < 0.0001$). In 55/74 eyes of 55 patients (74.3%), no adverse events were reported, and most of them were transitory (17/19; 89.5%). The mean time to resolve VMT was 27.4 ± 21.9 days. No cases of retinal tear, retinal detachment or lens destabilisation were observed.

Conclusion Ocriplasmin is a potential alternative treatment for patients with symptomatic VMT and has a good safety profile. A more careful selection of patients, in clinical practice, may increase the success rate.

INTRODUCTION

Vitreomacular traction (VMT) syndrome is a disorder of the vitreomacular interface characterised by an incomplete and pathological separation between the vitreous and the macula. Resulting alterations in retinal morphology may lead to symptomatic metamorphopsia and decreased visual acuity.^{1–3} The purpose of therapy is to release vitreous traction on the macula before structural retinal damage occurs.¹ Ocriplasmin, a serine protease, is active against substrates, such as fibronectin and laminin, and is therefore able to cleave the vitreoretinal interface.³ The results of phase III studies demonstrated a clinically significant difference in favour of a single intravitreal injection of 125 mg of ocriplasmin over the placebo, and they achieved VMT resolution at day 28.³

Key messages

What is already known about this subject?

- ▶ Pharmacological vitreolysis with intravitreal ocriplasmin is a new, safe, non-surgical option for the treatment of vitreomacular traction (VMT), with or without full-thickness macular hole (MH).

What are the new findings?

- ▶ In our retrospective, multicentric, observational case series, the ocriplasmin injection showed the complete release of the VMT in 59.7% of the cases. Furthermore, MH closure was obtained in 40% of the cases.
- ▶ Moreover, a low rate of adverse effects was observed.

How might these results change the focus of research or clinical practice?

- ▶ A more careful selection of patients could increase the percentage of success after ocriplasmin injection.

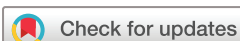Furthermore, release rates were found to be positively correlated with age less than 65 years, absence of an epiretinal membrane (ERM), VMT diameter of ≤ 1500 micra and phakic lens status.⁴ Concerning full-thickness macular hole (FTMH) treated with ocriplasmin, a closure rate of 40.6% was found versus 10.6% in the placebo group. Ocriplasmin was then approved for the non-surgical treatment of symptomatic VMT associated or not to FTMH less than 400 micra.³ Since the real-world use of the drug began, there have been favourable reports of visual improvement after ocriplasmin injection due to the release of VMT.^{5–7}

In this study, we examine a multicentric clinical experience (18 centres) of ocriplasmin injection for VMT with or without macular hole (MH), and we report on data from 74 collected eyes.

METHODS

Patients and baseline assessment

Informed consent was obtained from subjects (or their guardians).



© Author(s) (or their employer(s)) 2018. Re-use permitted under CC BY-NC. No commercial re-use. See rights and permissions. Published by BMJ.

Department of Surgical and Translational Medicine, Ophthalmology, University of Florence, Azienda Ospedaliera Universitaria Careggi, Florence, Italy

Correspondence to

Dr Ruggero Tartaro;
ruggertartaro@yahoo.it

Seventy-four consecutive patients were included in this study; they underwent a complete ophthalmological evaluation, including extensive history and optical coherence tomography (OCT). All patients with symptomatic vitreomacular adhesion or VMT who had the ocriplasmin injection (a single intravitreal injection of 125 mg ocriplasmin) were included; no injected patients were excluded. The primary end-point was VMT release at the end of follow-up (range 30–180 months postinjection).

Ocriplasmin injection protocol

All patients received an intravitreal injection of ocriplasmin (125 µg in a 0.10 mL volume) via pars plana. All intravitreal injections were performed under sterile conditions, as per standard protocol.

Patients were observed for 30 min after the injection and discharged if intraocular pressure was less than 30 mm Hg.

Statistical analysis

The patients were divided into subgroups according to traction width and MH size, if present.

The effect of baseline predictors of surgical success was assessed at 30 days as the primary analysis; anatomical response was a dichotomous variable (resolution of traction and closing the hole) in a logistic regression model. In secondary analyses, the anatomical and functional response (visual acuity) was assessed up to a follow-up of 6 months with linear mixed models, considering repeated measurements within the patient.

RESULTS

Findings at baseline

Seventy-four eyes of 74 patients (28 males, 20.7% and 46 females, 30.0%) were included in the study. Key baseline characteristics are summarised in table 1.

In 54 patients (73.0%), VMT was the only finding, while in 20 patients (27.0%), there was VMT combined with MH. The mean age of the studied cases was 71.3±11.2 years (range 32–91 years).

Sixty-one patients were phakic (82.4%), while 13 patients were pseudophakic (17.6%). At baseline, the mean BCVA was 0.48±0.31 logMar. Seventy-five patients at baseline (65/74 eyes; 87.3%) complained of metamorphopsia. Twelve of the 74 patients (12 eyes; 16.2%) had an ERM. The mean and the median extension of the preoperative VMT was 426.6±310.4 µm (range: 40–1600 µm) and 352.5 µm, respectively. Among patients with an MH, 13 patients (13/20 eyes; 17.6%) had FTMH width <250 µm, 3 patients (3/20 eyes; 15.0%) had FTMH width 250–400 µm and 4 patients (4/20 eyes; 20.0%) had FTMH width >400 µm. In particular, the mean diameter was 258.1±131.8 µm (range 82–550 µm).

Regarding the fellow eyes, 44 eyes were normal (44/74 eyes, 59.5%), 18 eyes were affected by VMT (18/74 eyes, 24.32%), in six eyes there was an FTMH (6/74 eyes, 8.1%) and vitrectomy was performed on six eyes (6/74, 8.1%).

Findings after ocriplasmin injection

Overall, 44 of 74 patients treated with ocriplasmin (59.5%) had VMT resolution at the end of follow-up. The mean follow-up period was 112±62.2 days (range: 30–180 days).

All patients without metamorphopsia at the baseline remained asymptomatic (9/74 eyes; 12.2%). Among patients that complained of metamorphopsia at the baseline, in 30 patients it was reduced (30/65 eyes; 30.8%), in 13 patients it disappeared (13/65 eyes; 20%), in 2 patients it worsened (2/65 eyes; 3.1%) and in 28 patients it was stable (28/65 eyes; 43.1%). In particular, among the patients with metamorphopsia at the baseline (40 eyes) who had a complete resolution of the VMT, 29 eyes also had metamorphopsia improvement, while among patients with metamorphopsia at baseline and no VMT resolution (25 eyes) metamorphopsia improved only in four eyes.

The VMT mean extension in the success group (resolution of the VMT) was 360±313.9 µm; in the group with no success (no resolution of VMT), it was 524±304.7 µm ($p=0.0481$) figure 1. In particular, we analysed the success rate (VMT resolution) in the four subgroups according to the baseline extension of the traction (each group differed by 499 µm; range 0–1600 µm). Regarding the VMT extension group (0–499 µm) success was obtained in 37 patients (37/54 eyes, 68%); regarding the second group (500–999 µm) in five patients (5/14 eyes; 35.7%); regarding the third group (1000–1499 µm), success was obtained in only one case (1/1 eyes; 100%) ($p=0.007$). Regarding the VMT extension group (>1500 µm), composed of only three eyes, no success was obtained.

Table 1 Findings at baseline

| | | |
|------------------------------|--------------------|---------------------|
| Cases | 74 | % |
| Sex | 46 F | 20.7 |
| | 28 M | |
| Age (mean) | 71 years | (range 32–91 years) |
| Eye | 44 left eye | 59.5 |
| | 30 right eye | 40.5 |
| Metamorphopsia | 65 yes | 87.3 |
| | 9 no | 12.1 |
| Lens status | 61 phakic | 82.4 |
| | 13 pseudophakic | 17.6 |
| VMT extension (mean, median) | 426±310 µm, 352 µm | (range 40–1600 µm) |
| FTMH | 20 | 27.0 |
| FTMH size (mean) | 258±131 µm | (range 82–550 µm) |
| ERM | 12 yes | 16.2 |
| | 62 no | 83.8 |
| BCVA (logMar) | 0.48±0.31 | (range 0–1.30) |

BCVA, best-corrected visual acuity; ERM, epiretinal membrane; FTMH, full-thickness macular hole; VMT, vitreomacular traction.

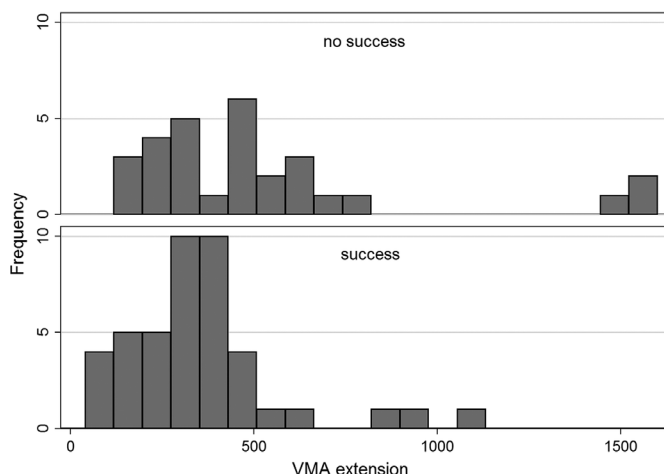


Figure 1 Histogram presenting the distribution of Vitreomacular traction (VMA) extension by surgical success outcome.

In the success group, the mean age was 66.8 ± 11.8 years, while in the no-success group, it was 76.6 ± 7.8 years ($p = 0.0001$).

The association between ERM or FTMH presence and VMT release was not significant ($p = 0.098$ and $p = 0.9319$). Furthermore, in this study, the association between lens status and VMT release after the injection of ocriplasmin ($p = 0.089$) was not significant.

FTMH closure occurred in eight patients (8/20 eyes; 40%). The patients with macular hole (MH) diameter $>400 \mu\text{m}$ did not present MH closure (0/4, 0%); regarding the holes of diameter $<250 \mu\text{m}$ 7/13 closed (53.8%); the holes of diameter $250\text{--}400 \mu\text{m}$ closed in a percentage of 33.3% patients.

Vitreotomy was performed on 12 patients, 12/74 (16.2%).

The distribution of logMAR BCVA is summarised in figure 2 and in figure 3 and subdivided according to success (resolution of VMT) or no success. The mean (BCVA) at baseline in the success group was 0.51 ± 0.32

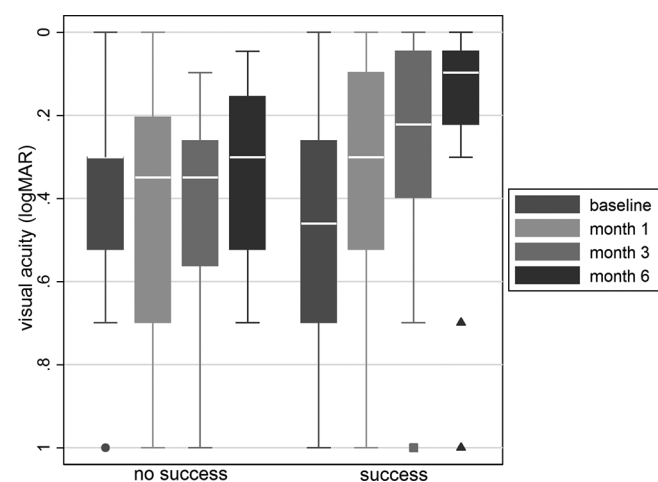


Figure 2 Boxplots of logMAR visual acuity at baseline and at 1, 3 and 6 months by surgical success outcome.

logMar; in the no-success group, it was 0.46 ± 0.38 logMar ($p = 0.5153$).

In 55/74 eyes of 55 patients (74.3%), no adverse events related to the ocriplasmin injection were reported; most of the adverse events were transitory (17/19, 89.5%). The mean time of adverse event resolution was 27.4 ± 21.9 days. Furthermore, no cases of retinal tear, retinal detachment, lens destabilisation and infections were found in this study. All the adverse events were reported within 1 week in table 2.

DISCUSSION

Spontaneous release rate of VMT is achieved only in 11%–47% of the cases over a mean time frame of 8–60 months,^{7,8} and even with spontaneous release abnormal structural changes in the macula and decreased visual acuity can persist, especially in chronic and/or severe cases of VMT. For VMT associated with FTMH, spontaneous closure rates are much lower (3%–11% of cases).^{9,10} Most MHs enlarge, with a progression rate of 84% from stage II to stage III/IV.¹⁰ Untreated FTMHs can result in significant and persistent decrease in visual acuity. The closure rates of MHs with current vitrectomy techniques are typically 88% or higher.¹¹

In VMT, treatment observation is shown to be ineffective; however, PPV is, today, the best treatment, but there is a higher risk of cataract formation, glaucoma, infection, retinal tears and detachment; for this reason, less invasive but effective treatment options are being developed.

Through the recently approved ocriplasmin (Jetrea; Thrombogenics, USA, Alcon/Novartis EU), pharmacological vitreolysis shows a possible safer alternative to surgery in patients affected by VMT.⁵

In our study, we report the Italian clinical experience using ocriplasmin for VMT with or without an MH. In phase III testing, the efficacy of ocriplasmin for VMT release was 26.5%,³ but this percentage can be higher (42%–67%) depending on the presence of positive predictive criteria like: age less than 65 years, focal adhesions $\leq 1500 \text{ mm}$, presence of FTMH, phakic status and absence of epiretinal membrane.⁴ Our results showed that VMT release occurred in 44 eyes (44/74 eyes; 59.5%). In 22 eyes (22/44, 50%), success occurred within the first month of follow-up. This difference between the clinical trials and the results of postmarketing studies could be due to our selection of the patients.

The closure rate of FTMH in our study was 40%; this finding is also consistent with data of the Microplasmin for intravitreal injection-traction release without surgical treatment (MIVI-TRUST) trials (40.6%).^{3,4} The MH diameter was shown to be an important prognostic factor; in fact, eyes with FTMH width of $\leq 250 \mu\text{m}$ at baseline were more likely to achieve pharmacological FTMH closure (53.8%) compared with those with FTMH width of $>250 \mu\text{m}$, who achieved closure only in 7% of the cases. Furthermore, our group included four patients with FTMH $>400 \mu\text{m}$, in whom the closure rate was 0%. Eyes

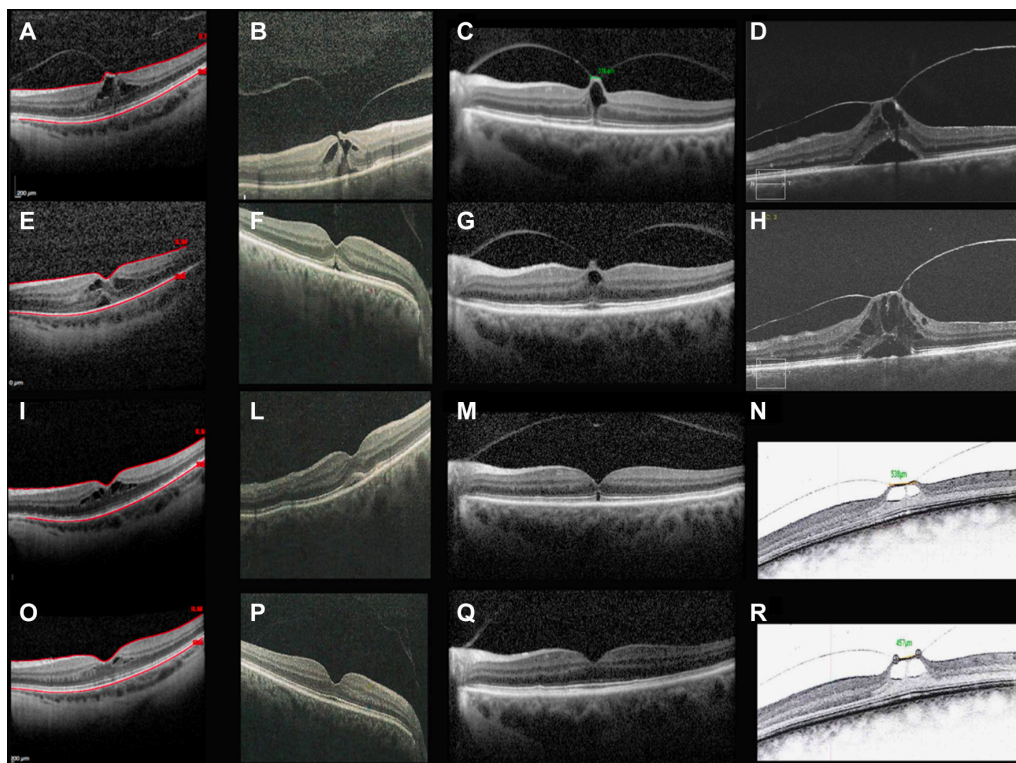


Figure 3 (A, E, I and O): OCT images show vitreomacular traction (extension 950 μm) at the baseline (A); 1 day after ocriplasmin injection (E); 1 month after ocriplasmin injection (I); and 6 months after ocriplasmin injection (O). Successful case. (B, F, L and P): OCT scans show an evident vitreomacular traction (extension 329 μm) with a full-thickness macular hole (diameter 82 μm) at the baseline (B); 1 month after ocriplasmin injection (F); 3 months after ocriplasmin injection (L); and 6 months after ocriplasmin injection (P). Successful case. (C, G, M and Q): OCT images show vitreomacular traction (extension 318 μm) at the baseline (C); 1 day after ocriplasmin injection (G); 1 month after ocriplasmin injection (M); and 6 months after ocriplasmin injection (Q). Successful case. (D and H): OCT scans show vitreomacular traction (extension 700 μm) at the baseline (D) and 2 months after ocriplasmin injection (H). Unsuccessful case. (N and R): OCT images show vitreomacular traction (extension 538 μm) at the baseline (N) and 6 months after ocriplasmin injection (R). Unsuccessful case. OCT, optical coherence tomography.

with FTMH width between 250 μm and 400 μm at baseline achieved a closure rate of 33.3%. These results are similar to those obtained by the clinical trials.⁴ In other reports, different closure rates were presented (17%–27%–28.6%–40%).^{5–7 12}

In figure 3, successful and unsuccessful cases are presented using OCT images.

VMT extension was shown to be, according to the clinical trials,⁴ an important prognostic factor; in fact, the success rate was 0% in the eyes with VMT extension ≥ 1500 micra. However, the association between ERM presence at baseline and VMT release was not significant

(p 0.931). This result is not in agreement with the clinical trials,⁴ in which the prevalence of ERM may have been underestimated. In the clinical trials, an old generation time-domain OCT was used, so patients with very evident epiretinal membrane were also included. Although we used the SD-OCT (more capacity of detection of epiretinal membranes), the prevalence of ERM in our patients was lower (16.2% vs 38.7%). This discrepancy is more probably due to improved patient selection for the ocriplasmin injection.

Regarding visual function, ocriplasmin showed important results: an improvement or complete resolution of metamorphopsia was achieved in 50.8% of the eyes. Furthermore, in our results, visual acuity at baseline did not influence VMT resolution after the injection (p 0.5153). The patients in which there was VMT resolution had better visual acuity; in fact, if we consider the difference between BVCA after 3 months of follow-up among the success and no-success groups, in the first group, there was significant improvement (about three lines) ($p < 0.0001$) figure 4.

This result could be explained in part by the complete restoration of the ellipsoid zone (EZ) integrity after the

Table 2 Number of adverse effects (AEs)

| AEs | Total events | % |
|---------------------------|--------------|------|
| Floater | 3 | 4.05 |
| Photopsias | 5 | 6.75 |
| Dyschromatopsia | 5 | 6.75 |
| Blurred vision | 4 | 5.40 |
| Subretinal fluid | 7 | 9.4 |
| Ellipsoid zone disruption | 3 | 4.05 |

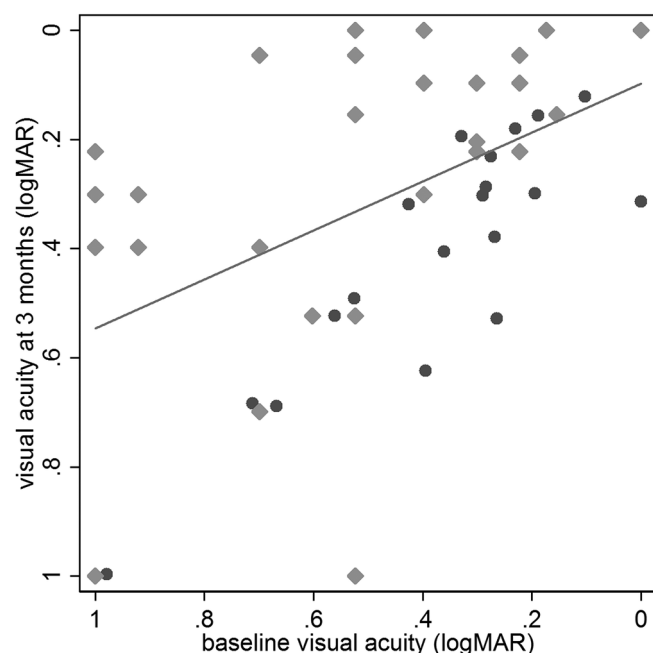


Figure 4 Scatterplot of baseline (x-axis) versus 3-month (y-axis) logMAR visual acuity. Eyes with surgical success are presented as light grey diamonds and those with no success are dark grey dots. Values above the diagonal (dashed) line are improved compared with baseline.

ocriplasmin injection, which takes about 3 months.¹³ In fact, it has been described in literature that transient OCT-based alterations were identified in a substantial number of the eyes after ocriplasmin therapy.¹⁴ These transient changes are particularly prominent in the EZ. In addition, the accumulation of subretinal fluid has also been described and appears to be closely linked to the changes in the EZ. The phase III trials used time-domain OCT, so the detection of these changes was difficult. The integrity of the EZ has been identified as an important factor for VA in multiple vitreoretinal conditions.^{15–17}

In two cases, we encountered a strong adhesion between the posterior hyaloid and the optic pit; however, performing active aspiration with the vitrectomy probe, even though after approximately 1 min of suction, we obtained the vitreous separation from the posterior pole.

In our series, we observed adverse events in only 25.7% of the eyes; the majority of these were transitory, and VMT resolution was observed in about 27 days; no serious adverse events were registered.

CONCLUSION

In conclusion, pharmacological vitreolysis with intravitreal ocriplasmin is a new, non-surgical option for the treatment of VMT, with or without FTMH. In our study, we have reported a high rate of success and a low rate of adverse effects. A more careful selection of patients could increase the percentage of success.

Acknowledgements Each author warrants that he or she has no commercial associations (eg, consultancies, stockownership, equity interest and patent/licencing arrangements) that might pose a conflict of interest in connection with the submitted article.

Collaborators The Italian Ocriclasmin group: Recchimurzo N, Niro A (Clinica Oculistica Università di Bari); Mariotti C; Orsini E (Clinica Oculistica Università di Ancona); Arpa P, Biraghi L (A.O.S Gerardo); Mura M (Università di Amsterdam); Iannetta D (Clinica oculistica Università di Cagliari); Scialdone A, Radice P (Ospedale oftalmico di Milano); Bruè C, Ramovecchi V (Ospedale di Macerata); Iaculli C (Clinica oculistica Università di Foggia); Morselli S, Cappello E, Toso A (Ospedale di Bassano del Grappa); Romano M (Clinica oculistica Università di Napoli); Caporossi A, Minnella A (Clinica oculistica Università Cattolica di Roma); Staurengi G, Cereda M (Clinica oculistica Università di Milano); Romani A, Peruzzi S, Pieri B (USL 8 oculistica Arezzo); Lovisolo C, Moretti A (Centro Oculistico Quattrorelle); Fanton G (Studio Medico Fanton); De Cilla S (Dipartimento di Scienze della Salute, Università del Piemonte orientale); Traversi C, Tosi Gian M (Clinica Oculistica Università di Siena); Carpineto P, Mastropasqua L (Clinica Oculistica Università di Chieti-Pescara).

Contributors SR, FB and TC planned the study. RT, FB, DPM and GV conducted the examinations. SR, FB, TC and GV performed the ocriclasmin injections. GV conducted the statistical analysis. RT is the corresponding author.

Funding The authors have not declared a specific grant for this research from any funding agency in the public, commercial or not-for-profit sectors.

Competing interests None declared.

Patient consent Obtained.

Ethics approval This is an approved retrospective, multicentric, observational case series adherent to the tenets of the Declaration of Helsinki and accepted by our ethics committee (AOUC Careggi, Firenze, Italy).

Provenance and peer review Not commissioned; externally peer reviewed.

Open access This is an open access article distributed in accordance with the Creative Commons Attribution Non Commercial (CC BY-NC 4.0) license, which permits others to distribute, remix, adapt, build upon this work non-commercially, and license their derivative works on different terms, provided the original work is properly cited, appropriate credit is given, any changes made indicated, and the use is non-commercial. See: <http://creativecommons.org/licenses/by-nc/4.0/>.

REFERENCES

- Sebag J. Anomalous posterior vitreous detachment: a unifying concept in vitreo-retinal disease. *Graefes Arch Clin Exp Ophthalmol* 2004;242:690–8.
- Jackson TL, Nicod E, Simpson A, *et al*. Symptomatic vitreomacular adhesion. *Retina* 2013;33:1503–11.
- Stalmans P, Duker JS, Kaiser PK, *et al*. Oct-based interpretation of the vitreomacular interface and indications for pharmacologic vitreolysis. *Retina* 2013;33:2003–11.
- Haller JA, Stalmans P, Benz MS, *et al*. Efficacy of intravitreal ocriclasmin for treatment of vitreomacular adhesion: subgroup analyses from two randomized trials. *Ophthalmology* 2015;122:117–22.
- Warrow DJ, Lai MM, Patel A, *et al*. Treatment outcomes and spectral-domain optical coherence tomography findings of eyes with symptomatic vitreomacular adhesion treated with intravitreal ocriclasmin. *Am J Ophthalmol* 2015;159:20–30.
- Sharma P, Juhn A, Houston SK, *et al*. Efficacy of intravitreal ocriclasmin on vitreomacular traction and full-thickness macular holes. *Am J Ophthalmol* 2015;159:861–7.
- Theodossiadis GP, Chatziralli IP, Sergentanis TN, *et al*. Evolution of vitreomacular adhesion to acute vitreofoveal separation with special emphasis on a traction-induced foveal pathology. A prospective study of spectral-domain optical coherence tomography. *Graefes Arch Clin Exp Ophthalmol* 2015;253.
- Odrobina D, Michalewska Z, Michalewski J, *et al*. Long-term evaluation of vitreomacular traction disorder in spectral-domain optical coherence tomography. *Retina* 2011;31:324–31.
- Ezra E, Fariss RN, Possin DE, *et al*. Immunocytochemical characterization of macular hole opercula. *Arch Ophthalmol* 2001;119:223–31.
- Hikichi T, Yoshida A, Trempe CL. Course of vitreomacular traction syndrome. *Am J Ophthalmol* 1995;119:55–61.
- Mester V, Kuhn F. Internal limiting membrane removal in the management of full-thickness macular holes. *Am J Ophthalmol* 2000;129:769–77.

12. Moisseiev J, Moroz I, Katz G. Effect of ocriplasmin on the management of macular holes: assessment of the clinical relevance of ocriplasmin. *JAMA Ophthalmol* 2014;132:709–13.
13. Kadosono K, Itoh N, Uchio E, *et al.* Staining of internal limiting membrane in macular hole surgery. *Arch Ophthalmol* 2000;118:1116–8.
14. Itoh Y, Ehlers JP. Ellipsoid zone mapping and outer retinal characterization after intravitreal ocriplasmin. *Retina* 2016;36:2290–6.
15. Singh R, Reddy DM, Barkmeier AJ, *et al.* Long-term visual outcomes following lens-sparing vitrectomy for retinopathy of prematurity. *Br J Ophthalmol* 2012;96:1395–8.
16. Freund KB, Shah SA, Shah VP. Correlation of transient vision loss with outer retinal disruption following intravitreal ocriplasmin. *Eye* 2013;27:773–4.
17. Nudleman E, Franklin MS, Wolfe JD, *et al.* Resolution of subretinal fluid and outer retinal changes in patients related to ocriplasmin. *Retina* 2016;36:738–43.