



UNIVERSITÀ
DEGLI STUDI
FIRENZE

FLORE

Repository istituzionale dell'Università degli Studi di Firenze

Acute liver injury following Garcinia cambogia weight-loss supplementation: case series and literature review

Questa è la Versione finale referata (Post print/Accepted manuscript) della seguente pubblicazione:

Original Citation:

Acute liver injury following Garcinia cambogia weight-loss supplementation: case series and literature review / Crescioli, Giada; Lombardi, Niccolò; Bettiol, Alessandra; Marconi, Ettore; Risaliti, Filippo; Bertoni, Michele; Menniti Ippolito, Francesca; Maggini, Valentina; Gallo, Eugenia; Firenzuoli, Fabio; Vannacci, Alfredo. - In: INTERNAL AND EMERGENCY MEDICINE. - ISSN 1828-0447. - ELETTRONICO. - 13:(2018), pp. 857-872. [10.1007/s11739-018-1880-4]

Availability:

This version is available at: 2158/1244214 since: 2022-05-04T12:37:12Z

Published version:

DOI: 10.1007/s11739-018-1880-4

Terms of use:

Open Access

La pubblicazione è resa disponibile sotto le norme e i termini della licenza di deposito, secondo quanto stabilito dalla Policy per l'accesso aperto dell'Università degli Studi di Firenze (<https://www.sba.unifi.it/upload/policy-oa-2016-1.pdf>)

Publisher copyright claim:

(Article begins on next page)



Acute liver injury following *Garcinia cambogia* weight-loss supplementation: case series and literature review

Giada Crescioli¹ · Niccolò Lombardi¹ · Alessandra Bettiol¹ · Ettore Marconi¹ · Filippo Risaliti² · Michele Bertoni² · Francesca Menniti Ippolito³ · Valentina Maggini^{4,5} · Eugenia Gallo^{4,5} · Fabio Firenzuoli⁵ · Alfredo Vannacci¹

Received: 8 March 2018 / Accepted: 17 May 2018
© SIMI 2018

Abstract

Herbal weight-loss supplements are sold as self-medication products, and are often used under the misconception that their natural origin guarantees their safety. Food supplements are not required to provide any benefit/risk profile evaluation before marketing; however, possible risks associated with use of herbal extracts in food supplements are becoming more and more documented in the literature. Some herbs are listed as the leading cause of herb-induced liver injury, with a severe or potentially lethal clinical course, and unpredictable herb–drug interactions. *Garcinia cambogia* (GC) extract and GC-containing products are some of the most popular dietary supplements currently marketed for weight loss. Here, we present four cases of acute liver failure in women taking GC extract for weight loss, and a literature review of clinical evidences about hepatic toxicity in patients taking dietary supplements containing GC extract.

Keywords Adverse events · Dietary supplements · *Garcinia cambogia* · Herb-induced liver injury · Hydroxycitric acid · Liver transplantation · Weight-loss supplements

Giada Crescioli and N. Lombardi contributed equally.

Electronic supplementary material The online version of this article (<https://doi.org/10.1007/s11739-018-1880-4>) contains supplementary material, which is available to authorized users.

✉ Giada Crescioli
giada.crescioli@unifi.it

¹ Department of Neurosciences, Psychology, Drug Research and Child Health, Section of Pharmacology and Toxicology, University of Florence, Viale G. Pieraccini, 6, 50139 Florence, Italy

² Division of General Medicine 2, New Hospital “Santo Stefano”, Prato, Italy

³ National Centre for Drug Research and Evaluation, National Institute of Health, Rome, Italy

⁴ Department of Experimental and Clinical Medicine, University of Florence, Florence, Italy

⁵ Referring Center for Phytotherapy, Tuscany Region Careggi, University Hospital, Florence, Italy

Introduction

Obesity has reached epidemic proportions globally, with at least 2.8 million people dying each year as a result of being overweight or obese [1]. Nonetheless, very few drugs are registered for this indication, while many dietary supplements containing medicinal plants are promoted for weight loss [2]. Their use is widespread and increasing in many European countries and in the United States, while the efficacy and safety data of these preparations are not required before marketing. Moreover, many claims cited by supplements are unsupported and inadequately regulated [3].

Medicinal plants and natural substances commonly used for weight loss include *Camellia sinensis*, *Amorphophallus konjac* (glucomannan), 1,3-dimethylamylamine, chitosan, usnic acid, *Cyamopsis tetragonolobus*, conjugate linoleic acid, *Ephedra*, *Garcinia cambogia* (GC), *Plantago ovata*, and *Citrus aurantium* [4].

Herbal weight-loss supplements are generally used as self-medication under the misconception that their natural origin guarantees their safety [5]. As described by Pajor and colleagues (2017), users and non-users of dietary supplements consider these products safe, and assign the occurrence of possible adverse effects (AEs) more to the

consumer status (e.g., excessive use, being ill, etc.) than to the product characteristics [6]. Indeed, some herbal chemicals have been related to herb-induced liver injury (HILI) with a severe or potentially lethal clinical course, leading to emergency department (ED) visit and liver transplant [7]. Regarding the herbal extract of GC, the main active component is the hydroxycitric acid (HCA), which acts as potential supplement to weight control by causing appetite suppression, and reducing the body's ability to form adipose tissue [8]. Nevertheless, there are contrasting findings on HCA safety [9], and several aspects on its effectiveness in weight-loss control are still poorly investigated [10].

Given that, regulations and pharmacovigilance regarding herbal products are incomplete and need to be improved [11].

To shed light on the benefit/risk ratio of the use of GC extract as dietary supplement [10], we present four cases of acute liver failure in women taking GC extract for weight loss, and a literature review of the clinical evidences on the onset of hepatic toxicity in patients taking dietary supplements containing GC extract.

Case series

Within the Italian Surveillance System of Natural Health Products, set up in 2002 and coordinated by the Italian National Institute of Health [12], a multidisciplinary group of experts collected the suspected AEs related to dietary supplements containing GC. In particular, AEs related to acute hepatotoxicity and leading to ED visit were evaluated. From April 2002 to December 2017, out of a total of 1510 reports, 14 concerned AEs to weight-loss supplements containing GC, 6 reported acute liver toxicity. The first case was registered in 2005 and subsequently documented [13]; nevertheless, another four cases occurred, and a description is included below. One case was excluded because the patient had been exposed to several dietary supplements other than GC, and it was difficult to clearly define the causality

assessment between herbal intake and related hepatotoxicity. Figure 1 shows principal hepatic parameters measured for each patient at the ED visit.

Case 1

A 61-year-old woman presented to ED with symptoms of 10-day abdominal pain, nausea, progressive weakness, jaundice, dark urine, and acholic stools. The patient's anamnesis denoted cholecystectomy, mixed dyslipidemia, and hypothyroidism in treatment with levothyroxine. There was no history of alcoholism or exposure to hepatotoxins; she also denied paracetamol abuse.

She reported taking one envelope/daily of SUPER ANANAS SLIM[®], for a period of 2 months to lose weight. This additional feed contained extracts of GC (HCA 60%), *Ananas comosus* (bromelain 334 GDU, Gelatin Dissolving Units), and *Ilex paraguariensis* (caffeine 2%).

Laboratory tests performed during the ED visit revealed that alanine aminotransferase (ALT), aspartate aminotransferase (AST), total bilirubin (TB), direct bilirubin, albumin, alkaline phosphatase (ALP), and gamma glutamyl transferase (GGT) values were out of the normal range. International normalized ratio (INR) at ED admission was in range (INR 1.6, range 0.83–1.9). Table 1 summarizes the trend of the main liver function indices from the acute phase after ED admission to the follow-up.

A 3-month prior routine check-up had found such parameters to be normal. The serum was negative for hepatitis viruses or autoantibodies as well as for Wilson's disease. Abdominal ultrasound, cholangio-magnetic resonance imaging (MRI), and portal vessel's Doppler were normal, and did not reveal steatosis.

The abdominal computed tomography scan revealed a small peritoneal effusion, perihepatic lymphadenopathy, and a hepatic biopsy which was consistent with cholestatic hepatitis. The progressive increase in TB levels up to 22.5 mg/dL was treated by clinicians with two sessions of plasmapheresis. Later, the levels of TB declined. Four weeks after the

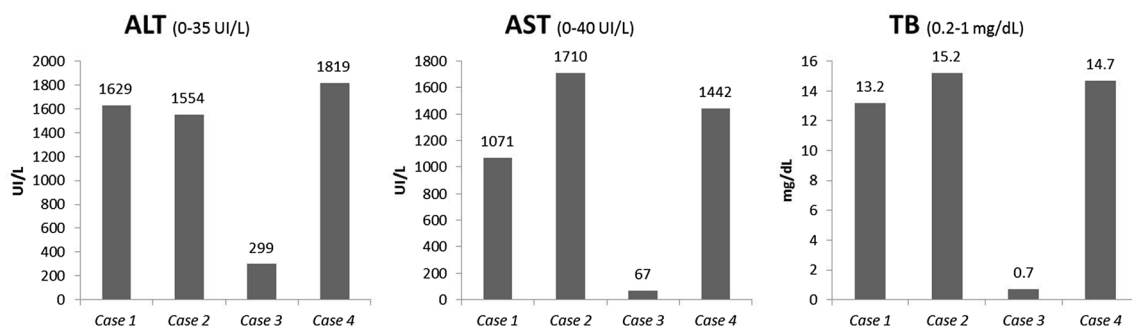


Fig. 1 Case series—principal hepatic parameters (ALT, AST, and TB) measured at ED visit. ALT alanine aminotransferase, AST aspartate aminotransferase, TB total bilirubin

Table 1 Case 1—serum and liver indices from ED visit to follow-up

Liver index	Acute phase	Discharge 21 days after admission	Follow-up 40 days after admission	Follow-up 60 days after admission	Follow-up 90 days after admission	Follow-up 150 days after admission
ALT (0–35 UI/L)	1629	821	525	187	72	56
AST (0–40 UI/L)	1121	1058	506	158	69	59
TB (0.2–1 mg/dL)	22.5	7.4	3.2	1.6	1	0.9
Direct bilirubin (0–0.25 mg/dL)	16.7	3.4	1.4	0.6	0.3	0.2
Albumin (3.5–5 g/dL)	2.2	3.1	3.4	3.5	3.5	3.8
Cholinesterase (4700– 14,000 UI/L)	1299	1587	3134	4247	5151	–
INR (0.83–1.9)	2.2	1.31	1.2	1.18	1.19	1.11
Fibrinogen (200–400 mg/dL)	165	283	340	366	420	485
ALP (42–98 UI/L)	150	126	166	165	164	178
GGT (7–32 UI/L)	47	47	57	42	22	16

ALP alkaline phosphatase, ALT alanine aminotransferase, AST aspartate aminotransferase, GGT gamma glutamyl transferase, INR international normalized ratio, TB total bilirubin

cessation of the GC-containing supplement intake, patient symptoms and liver function tests gradually improved, and she was discharged with no need for a liver transplant. Four months later, the levels of the above-mentioned laboratory tests reverted to normal values.

Clinicians also use the recently updated hepatotoxicity specific Council for International Organizations of Medical Sciences (CIOMS) scale as a tool to confirm the HILI diagnosis [14]. The total score and resulting causality grading for this case was 7 (score range 6–8), consistent with a probable diagnosis of HILI.

Case 2

A 39-year-old woman presented to the ED with symptoms of jaundice, asthenia, loss of appetite, and right hypochondrial pain. Her anamnesis denoted arterial hypertension, obesity (body mass index, BMI 44.9), and hiatal hernia. Current medications at the time of admission were methyl dopa 500 mg/die, domperidone 10 mg three times per day and omeprazole 20 mg two capsules per day.

She also reported taking two dietary supplements for weight loss recommended by her dietitian. The first, OBLESS[®], contained for each capsule: *C. aurantium* 140 mg of extract 10% (14 mg of synephrine), GC (72 mg of HCA), *Orthosiphon stamineus* (0.2 mg of sinensetin), and *Griffonia simplicifolia* (75 mg of 5-hydroxy-L-tryptophan). The second was a magistral preparation containing for each capsule: *C. aurantium* 350 mg of extract 6% (21 mg of synephrine), *Rhodiola rosea* 150 mg extract, and *O. stamineus* 200 mg extract. The patient declared that she had been taking the first dietary supplement for the previous month (1 capsule/day) and the magistral preparation for 15 days (1 capsule/day), simultaneously.

Laboratory tests performed in the ED revealed that principal hepatic markers (ALT, AST, and TB) were out of the normal ranges (Fig. 1). Moreover, for this patient, the following liver indices were also available: direct bilirubin (13.2 mg/dL; range 0–0.25 mg/dL), ALP (158 UI/L; range 42–98 UI/L), GGT (80 UI/L; range 7–32 UI/L), lactate dehydrogenase (399 UI/L; range 140–180 UI/L), C-reactive protein (1.91 mg/dL; range < 0.5 mg/dL), and mean corpuscular volume (76 fL/red cell; range 80–96 fL/red cell). Blood coagulation parameters and hemoglobin (Hb 13.2 g/dL) were in range. Serology was negative for hepatitis viruses, cytomegalovirus, and varicella–zoster virus. On the contrary, nonspecific antinuclear antibodies and biliary antibodies were positive. Abdominal ultrasound was normal, and did not reveal steatosis. Liver biopsy was not performed.

During the hospital stay, after the cessation of dietary supplements and concomitant medications intake, levels of TB spontaneously declined, and her symptoms and liver function tests gradually improved. After 12 days of hospitalisation, the patient was discharged with no need of supplementary therapies, and a diagnosis of acute cholestatic hepatitis related to the consumption of OBLESS[®] was made. With regard to hepatotoxicity, a role of the simultaneous use of methyl dopa, high dose of synephrine and HCA could not be excluded, although the total score and resulting causality grading for this case was 6, consistent with probable diagnosis of HILI.

Case 3

A 47-year-old woman was admitted to the ED with symptoms of severe abdominal pain (right hypochondrial). Her anamnesis denoted hypothyroidism (treated with levothyroxine 100 µg/day), arterial hypertension (treated with

enalapril 20 mg/day), and mild obesity. She also reported taking 2 capsules/day of THERMO GIALLO[®], a dietary supplement as self-medication for weight control. This product contains chromium 50 µg and GC 400 mg of extract 50% (200 mg of HCA), for each capsule. The patient reported that she had been taking this supplement for the previous month (2 capsules/day). Laboratory tests performed during the ED visit revealed a mild elevation of liver parameters: AST, TB, and ALT (Fig. 1). Serology was negative for hepatitis viruses or autoantibodies. No clinical evidences of steatosis were observed, and liver biopsy was not performed.

During the hospital stay, after the cessation of weight-loss supplement, the levels of TB spontaneously declined, and her symptoms and liver function tests rapidly improved, without the need of therapies. The patient was discharged with a diagnosis of acute hepatitis, and the total score and resulting causality grading was 6, consistent with probable diagnosis of HILI.

Case 4

A 52-year-old woman was admitted to the ED, and diagnosed with acute hepatitis. No significant diseases and medication therapies were reported in anamnesis. However, she was taking two JILL COOPER BE SLIM[®] products (1 capsule/day for each product) for weight control, containing GC 400 mg of extract 60% (240 mg of HCA) and *Green Coffee* 400 mg of extract 50% (200 mg of chlorogenic acid), respectively. The patient declared that she bought these supplements on a television channel, and she used them for the previous month before the ED visit.

Laboratory tests revealed a mild elevation of principal liver parameters: AST, TB, ALT (Fig. 1). Moreover, for this patient, the following liver indices were also available: GGT (223 UI/L), and ALP (204 UI/L). Serologies for hepatitis viruses and autoantibodies were also negative. No clinical evidences of steatosis were observed, and liver biopsy was not performed.

During the following days, after the cessation of weight-loss supplements, liver parameters spontaneously declined, and acute hepatitis completely resolved with no need of supplementary therapies. The total score grading for this case was consistent with probable diagnosis of HILI (total score 6).

Literature review

Data for this review were obtained by searching Medline or PubMed with a search strategy that included four domains: one related to GC, one to its use in humans for weight control, one related to safety, and one related to dietary supplements. We included only case reports and case

series, carried out in humans, and published in a scientific journal in the database of Science Citation Index or Medline between January 2000, and October 2017. We finally selected 24 case reports and 8 case series reporting AEs in a total of 66 patients after GC extract consumption. Once the articles had been selected, the following significant data were extracted: article, country, number of patients, gender, age (years), adverse events, diagnosis, symptoms, clinical outcome, clinical history, concomitant drugs, and exposure to GC before symptoms' onset. Characteristics of the analyzed studies are reported in Table 2.

Five studies report single cases of myocarditis, cardiomyopathy, serotonin toxicity, hypoglycaemia, and thrombocytopenic purpura [15–19]. Two patients presented acute pancreatitis and diabetic ketoacidosis [20, 21], three patients experienced rhabdomyolysis [22–24], and in five studies, the authors describe AEs of mania and multiple psychotic symptoms [25–29]. Most patients were women (62%) with no relevant medical history. Seventeen studies out of 32 describe cases of acute liver injury, liver failure, and hepatotoxicity, observed in 50 patients who consumed GC dietary supplements or GC pure extract [13, 30–45].

All patients with hepatic AEs consumed their food supplements following producers' indications, and developed similar symptoms. In particular, jaundice, weakness, abdominal pain, dark urine, nausea, and vomiting were the most reported AEs. Symptoms' onset and clinical outcome differed among cases. In fact, some patients were exposed to GC only for a few days or weeks, other patients took their dietary supplement for more than 1 year. Moreover, 38 patients improved, while 8 subjects needed a liver transplantation. One patient was diagnosed with liver cirrhosis and two patients died. The first one, a 45-year-old Italian woman, was taking montelukast because of chronic asthma (5-year treatment) and developed a rapid progressive liver failure after 7-day consumption of two dietary supplements containing GC and *C. aurantium*, taken simultaneously [13]. Authors postulated that HCA augmented the liver toxicity proper of montelukast. The second patient died because of complications following liver transplantation [33]. Laboratory tests performed during the ED visit showed similar liver serum indices among patients with hepatic AEs. Liver serum values, when reported in more than five studies, are listed in Supplementary Table 1.

In two case reports and five case series, authors used several algorithms and scales to estimate the causality assessment between observed AEs and GC consumption. In four studies CIOMS criteria were used, with a total of 1 possible, 2 certain, and 12 probable cases [31, 40, 42, 44].

Elinav and colleagues [33] using WHO criteria [46] to define causality assessment of AEs related to GC consumption, address three cases as certain, six as probable, and three as possible. Another case [45] was defined as probable

Table 2 Literature review—clinical characteristics of patients exposed to dietary supplements containing GC

Article	Country	No of patients	Gender	Age (years)	Adverse event and diagnosis	Symptoms	Clinical outcome	Clinical history	Concomitant drugs	Exposure to GC before symptoms onset
Actis, 2007 [13]	Italy	1	F	45	Fatal liver failure	Nausea, vomiting, malaise, jaundice	Death	Asthma; obesity	Montelukast	1 w
Allen, 2014 [15]	USA	1	F	48	Acute necrotizing eosinophilic myocarditis	Light-headedness, hypotension, chest heaviness, presyncopal event, tachycardia	Improvement	No medical history	None	2.5 w
Bystrak, 2017 [20]	USA	1	F	56	Diabetic ketoacidosis, pancreatitis, cardiomyopathy	Mild abdominal pain, vomiting, lethargy, confusion, peri-pancreatic stranding, pancreatic atrophy, tachycardia	Hospitalization	Diabetes mellitus; hypertension; hepatitis C infection; opioid abuse 18 years before the event; hyperlipidemia; anxiety	Insulin glargine 75 U daily; atorvastatin 20 mg daily; lisinopril 5 mg daily; hydrochlorothiazide 12.5 mg daily; metformin 2000 mg daily; metoprolol 25 mg daily; aspirin 81 mg daily; methadone 125 mg daily; diazepam 10 mg daily; dietary supplement with <i>Irvingia gabonensis</i> or African mango	1 mo (6 tablets daily)

Table 2 (continued)

Article	Country	No of patients	Gender	Age (years)	Adverse event and diagnosis	Symptoms	Clinical outcome	Clinical history	Concomitant drugs	Exposure to GC before symptoms onset
Chen, 2010 [30]	USA	3	F	31	Acute liver injury (DILI); multi-lobular necrosis, fulminant hepatitis	Fatigue, jaundice, and nausea, scleral icterus, and mild upper quadrant tenderness	Improvement	No medical history	None	1 year (2 tablets daily)
			F	37	Acute liver injury (DILI); centrilobular and periportal necrotizing hepatitis, bridging fibrosis	Diffuse abdominal pain, mild nausea, painless jaundice	Improvement	No medical history	None	3 mo
			F	53	Acute liver injury (DILI); cholestasis and drug-induced hepatitis	Painless jaundice, pruritus, scleral icterus, with evidence of exoriations	Improvement	No medical history	None	4 mo
Corey, 2016 [31]	USA	1	F	52	Acute liver failure; shrunken nodular liver; collapsing necrosis	Decrease appetite, worsening fatigue, intermittent confusion, jaundice	Liver transplantation	No medical history	Topical hormone cream (β -estrogen and progesterone); melatonin; dicyclomine; antifungal nail oil	3.5 w (2 tablets daily)
Cotovio, 2017 [25]	USA	1	F	51	Hypomania	Irritability, agitation, increased energy, decrease need for sleep	Full remission of all symptoms	Bipolar disorder type I	Valproic acid 1250 mg/day; paroxetine 20 mg/day	2 w

Table 2 (continued)

Article	Country	No of patients	Gender	Age (years)	Adverse event and diagnosis	Symptoms	Clinical outcome	Clinical history	Concomitant drugs	Exposure to GC before symptoms onset
Dara, 2008 [32]	USA	2	F	40	Hepatotoxicity	Crampy, mid-epigastric abdominal pain, diarrhea, fever, chills, nausea and vomiting, anorexia, profound fatigue	Improvement	Hypothyroidism	Levothyroxine	1 w (6 pills daily)
			F	33	Acute hepatitis	Jaundice, nausea, crampy abdominal pain, alcoholic stools, dark-colored urine, pruritus, profound fatigue	Improvement	Pituitary adenoma	Ortho-Novum® contraceptive (2.5 years)	2 w
Dehoney, 2009 [22]	USA	1	M	18	Rhabdomyolysis	Bilateral leg pain, weakness, leg tenderness	Improvement after 6 L of 0.9% sodium chloride i.v.	NR	Naproxen 220 mg; Adderall® (dextroamphetamine salts) 15 mg monthly per os; hydrocodone-acetaminophen; cyclobenzaprine	4 caplets daily
Elinav, 2007 [33]	Israel	12	11 F 1 M	Mean 49.5; range 23–78	Acute idiopathic liver injury in association with Herbalife® consumption	Fatigue, jaundice, weight loss (11 patients)	11 pts improved; 1 pt died after liver transplantation	1 pt positive for hepatitis B; 1 pt with primary biliary cirrhosis; 10 pts with no relevant medical history	1 pt aspirin, metformin, statins; 1 pt α -adrenergic blocker; 2 pts hormone replacement therapy; 1 pt ursodeoxycholic acid; 1 pt oral contraceptives; 1 pt bisphosphonates, aspirin; 5 pts none	Mean \pm SD 11.9 \pm 11.1 mo

Table 2 (continued)

Article	Country	No of patients	Gender	Age (years)	Adverse event and diagnosis	Symptoms	Clinical outcome	Clinical history	Concomitant drugs	Exposure to GC before symptoms onset
Fong, 2010 [34]	USA	8	2 F 6 M	Mean 30.9; range 17–54	Severe liver injury	Jaundice (all 6 pts), fatigue and vomiting (all pts), abdominal pain (4 pts)	3 pts improved after liver transplant; 5 pts improved	All pts with no relevant medical history	1 pt prednisone	Median 6 w 1 pt 52 w 1 pt 104 w
Hendrickson, 2016 [29]	USA	3	M	50	Mania	Grandiosity, irritability, pressured speech, excessive spending, increased social activity, decreased need for sleep	Improvement; hospital discharge with olanzapine and valproic acid therapy	Bipolar disorder type I	NR	2 mo (2 pills daily)
			M	25	Mania; psychosis; bipolar disorder type I	Inflated self-esteem, grandiosity, decreased need for sleep, increased activities, excessive spending, pressured speech, paranoia, religious delusions	Improvement; hospital discharge with olanzapine and valproic acid therapy	No medical history	NR	2 mo (1–2 pills daily)
			F	34	Mania	Irritability, pressured speech, decreased need for sleep, agitation	Improvement; hospital discharge with low-dose lorazepam therapy	Bipolar disorder type II; past SSRI-induced hypomania	Aripiprazole; bupropion; topiramate	4–6 w
Hines, 2015 [23]	USA	1	M	40	Severe rhabdomyolysis	Muscle soreness, dark urine	Improvement	No medical history	None	2 w (1 capsule daily)
Jones, 2007 [35]	USA	1	M	19	Acute liver injury	Nausea, vomiting, jaundice, scleral icterus	Improvement	No medical history	None	4 mo

Table 2 (continued)

Article	Country	No of patients	Gender	Age (years)	Adverse event and diagnosis	Symptoms	Clinical outcome	Clinical history	Concomitant drugs	Exposure to GC before symptoms onset
Joseph, 2014 [16]	USA	1	F	51	Cardiomyopathy; hypokinesias of the left ventricle	Shortness of breath, new onset of palpitations, hypertension	Improvement	No medical history	None	1 w
Kotadia, 2016 [36]	USA	1	F	36	Hepatotoxicity; liver mild echotexture coarsening; small ascites	Low-grade fever, nausea, vomiting, abdominal pain, scleral icterus, malaise, fatigue, anorexia, jaundice, tender hepatomegaly	Improvement	No medical history	None	4 w
Lopez, 2014 [17]	USA	1	F	35	Serotonin Toxicity	Stuttering speech, profuse sweating, hypertension, tachycardia, diaphoresis, spontaneous ankle clonus	Improvement	Chronic pain syndrome	Oxycodone and cannabis for chronic pain syndrome; escitalopram 20 mg for 1 year; sertraline 50 mg/day 1.5 w prior to admission; baclofen; gabapentin; omeprazole; oxycodone; sildenafil; solifenacin; diphenhydramine	2–3 mo (6 capsules daily)
Lunsford, 2016 [37]	USA	1	M	34	Acute liver failure; submassive necrosis	Nausea, vomiting, abdominal pain, dark urine, asterixis, jaundice, confusion	Liver transplantation	No medical history	NR	5 mo (6 capsules daily)
Mansi, 2004 [24]	USA	1	F	54	Rhabdomyolysis	Spasmodic chest pain, breath shortness	Improvement	Moderate obesity	NR	3 h

Table 2 (continued)

Article	Country	No of patients	Gender	Age (years)	Adverse event and diagnosis	Symptoms	Clinical outcome	Clinical history	Concomitant drugs	Exposure to GC before symptoms onset
McDonnell, 2009 [38]	USA	1	M	25	Fulminant hepatic failure	Tea-colored urine, fatigue, nausea, vomiting, aches, fever	Liver transplantation	No medical history	None	1.5 w
Melendez-Rosado, 2015 [39]	USA	1	F	42	Acute hepatitis	Abdominal pain, nausea, clamminess	Improvement	Hypertension; chronic kidney disease; diabetes mellitus type 2; chronic back pain; hemochromatosis; obesity	Hydralazine; hydrocodone/acetaminophen 7.5/325 mg every 4–6 h for back pain 3 days prior to admission	1 w
Narasimha, 2013 [26]	India	1	M	23	Mania	Extreme irritability, aggression, hallucinatory behavior, decreased sleep	Improvement	No medical history	NR	1 mo (1–2 capsules daily)
Nguyen, 2017 [27]	USA	1	F	22	Mania	Expansive mood, psychomotor agitation, disorganized and pressured speech, flight of ideas, grandiosity, delusions, auditory hallucinations	Hospitalization for 8 days and treatment with olanzapine 10 mg, lithium 300 mg 3 times per day and quetiapine 50–100 mg nightly for 1–3 mo	No medical history	Etonogestrel subdermal implant; 2 dietary supplements: G cambogia Plus™ (500 mg per capsule, 60% HCA); Cleanse and Detox® (raspberry ketones, licorice root, pumpkin seed, buckthorn root, <i>Cascara sagrada</i> , African mango, rhubarb, citrus pectin, acidophilus, <i>Cape aloe</i>)	1 w (1–3 capsules daily)
Roche, 2014 [18]	USA	1	F	67	Hypoglycemia	Syncope, hypoglycaemia	Improvement	Hypertension	Venlafaxine; lisinopril-hydrochlorothiazide; alprazolam	2 d

Table 2 (continued)

Article	Country	No of patients	Gender	Age (years)	Adverse event and diagnosis	Symptoms	Clinical outcome	Clinical history	Concomitant drugs	Exposure to GC before symptoms onset
Schoepfer, 2007 [40]	Switzerland	10	6 F 4 M	Mean 51 Range 30–69	Hepatotoxicity: 7 pts hepatic necrosis; 1 pt fulminant liver failure; 1 pt sinusoidal obstruction syndrome; 1 hepatocellular injury	Fatigue, loss of appetite, jaundice	1 pt improved after liver transplantation; 1 pt diagnosed with proven cirrhosis; 8 pts improved	1 pt positive for hepatitis A and B; 1 pt positive for hepatitis E; 1 pt with alcohol consumption (50 g/die)	At least 1 year before presentation: 1 pt amiloride/HCT; 1 pt cyproterone/ethinyl estradiol; 1 pt ASA and diphenhydramine; 1 pt losartan	Median 5 mo
Shim, 2009 [41]	USA	1	M	28	Hepatotoxicity	Fatigue, dyspnea on exertion, jaundice, dark urine	Improvement	No medical history	Acetaminophen/ASA/caffeine 250/250/65 mg 4 times per day 10 d prior to admission	3 mo (4–6 tablets daily)
Sidhu, 2016 [21]	USA	1	M	36	Acute Pancreatitis	Left upper quadrant pain	NR	No medical history	NR	7 mo
Sikka, 2016 [19]	USA	1	F	59	Drug-induced immune thrombocytopenia, small subacute subdural hematoma	Painless GI bleed, abdominal and oral petechia, mild headache	CVA	NR	ASA	1 mo
Smith, 2016 [42]	USA	1	M	26	Liver failure, massive hepatic necrosis	Icteric sclera and skin, fatigue	Liver transplantation	No medical history	Whey protein powder food supplement (1 w)	1 w (10 w prior to admission)
Stevens, 2005 [43]	USA	2	M	27	Acute liver injury	Fatigue, jaundice	Improvement	No medical history	None	5 w (9 tablets daily)
			M	30	Acute liver injury	Jaundice, fever, vomiting, fatigue	Improvement	No medical history	None	5 d (9 tablets daily)

Table 2 (continued)

Article	Country	No of patients	Gender	Age (years)	Adverse event and diagnosis	Symptoms	Clinical outcome	Clinical history	Concomitant drugs	Exposure to GC before symptoms onset
Stickel, 2009 [44]	Switzerland	2	F	78	Severe hepatotoxicity; cholestatic and lobular/portal hepatitis	Nausea, painless jaundice, light stools, dark brown urine, pruritus	Improvement	Hypertension; hip endoprosthesis; appendectomy; cholecystectomy; alcohol consumption (60–80 g/w)	All treatments started more than 1 year prior to symptoms' onset: irbesartan/HCT (300 mg/12.5 mg); carvedilol (25 mg); omeprazole 20 mg (occasionally); zolpidem 10 mg	3 year
Vitalone, 2016 [45]	Italy	1	F	39	Severe hepatotoxicity; cirrhosis	Weakness, painless jaundice and fluctuating lower abdominal pain intermittently for several years, pruritus	Improvement	Cholecystectomy; hysterectomy for myoma	None	1 year
Wong, 2016 [28]	USA	1	M	43	Multiple psychotic symptoms	Auditory and visual hallucinations, paranoid thoughts, loss of appetite and sleep	Improvement; therapy with risperidone 2 mg, diphenhydramine 25 mg twice daily, cyanocobalamin 1000 mcg	No medical history	None	NR
									5 food supplements: GC, Brain Support, Brain Awake®, a probiotic, Absorb-max™	NR

ASA, acetylsalicylic acid, CVA cerebrovascular accident, *d* days, *F* female, *GI* gastrointestinal, *HCT* hydrochlorothiazide, *M* male, *mo* months, *NR* not reported, *pt/ppts* patient/patients, *w* week

according to the same WHO criteria [46]. Finally, using the Drug-Induced Liver Injury Network (DILIN) study criteria [47], two cases were classified as probable, two possible, and five highly likely related to GC utilization [34].

Discussion

GC is a small fruit with traditional culinary use, and potential medicinal applications. In fact, several clinical interactions of GC have already been documented in the literature, for example, in the context of: appetite control [11, 48], neuroprotection [49], lipoproteins and cholesterol control [50], alterations in blood cell count [50], fat mass control [51], glucose metabolism [52], hormones regulation, and interactions with organ system (i.e., kidney) [53].

GC is a source of HCA (structurally related to citric acid), one of the isomers [(–)-hydroxycitric acid], which is thought to help in weight control [54]. The mechanism of action is inhibiting an enzyme called citric acid lyase, which is required in the synthesis of fatty acids. Preclinical evidence suggests that oral consumption of HCA reliably reduces food intake and body weight [51]. Studies in humans, for the most part, fail to replicate this. Some isolated studies do note weight loss, but it appears to be quite variable and unreliable.

Although there is some limited potential for HCA as a weight-loss inducer, the magnitude of effect is quite low, and the benefit is unreliable; making it hard to recommend this compound as a fat burner or anti-obesity agent. Beside poor evidence on GC efficacy as dietary compound, safety issues regarding this extract also represents a major clinical concern.

Present work suggests a potential causal association between consumption of GC products and development of acute liver injury. Although in some cases liver damage progressed slower than in others, this association is also supported by clinical outcomes of improvement after the cessation of dietary supplement intake. Symptoms of liver damage were similar in all patients, and were also confirmed, if available, by liver biopsies.

Length of GC treatment appears to be very heterogeneous among cases. However, given the lack of individual factors, such as comorbidities, concomitant treatment, and genetic factors, we were not able to evaluate the possible relationship between length of GC exposure and HILI severity, particularly for cases coming from the literature review.

Cavalieri et al. (2017) confirmed hepatitis, cholestasis accompanied with jaundice, pruritus, prominent elevation of alkaline phosphatase, and mild elevation of aminotransferases as clinical evidences of drug- and herb-induced hepatotoxicity [55].

HILI and drug-induced liver injury (DILI) are both caused by chemicals, but as HILI is primarily a human rather than an animal disease, experimental models to study in detail the mechanisms leading to injury are rarely available [56]. Usually, dietary supplements contain several ingredients, thus the substance specifically responsible for liver damage can be difficult to identify. Nevertheless, the case presented by Lunsford et al. (2016) was the first acute liver failure associated with a purified extract of GC, and as HCA was the main active principle of this kind of extract, it was the first substance to be suspected [37].

The HCA mechanism of toxicity on the liver is not clearly defined. In 2007, a study conducted in Houston (USA) shows that Super CitriMax (HCA-SX), a salt of (–)-hydroxycitric acid, reduces food intake, weight gain, and also attenuates the increase of inflammation, oxidative stress, and insulin resistance in obese rats [57]. Kim and colleagues (2013) studied the long-term effect of GC extract in obese mice, but find conflicting results [58]. The supplementation of GC confirms the action in weight control, significantly lowering visceral fat accumulation and adipocyte size by the inhibition of fatty acid synthesis and enhancing fatty acid β -oxidation. However, HCA increases hepatic collagen accumulation, lipid peroxidation, mRNA levels of genes related to oxidative stress (superoxide dismutase and glutathione peroxidase), and inflammatory responses (tumor necrosis factor- α and monocyte chemoattractant protein-1). Furthermore, GC-supplemented mice exhibit impaired liver function showing elevated plasma ALT and AST levels. Oxidative stress plays an important role in progression of steatohepatitis and hepatocellular injury [59]. In fact, reactive oxygen species can damage DNA, lipids, and proteins, inducing necrosis and apoptosis of hepatocytes and promoting inflammatory response.

Evidence highlights that the percentage of women attempting to control weight using dietary supplements is higher than that of men. In fact, all Italian cases herein described and the majority of patients (62%) described in the literature review were women. It is well-known that the percentage of women dissatisfied with their current weight and attempting to lose weight is also higher than that of men [60]. This might be explained by the common desire for a perfect body and thinness among women [60]. In this context, we believe that healthcare professionals (physicians, pharmacists, dieticians, herbalists, etc.) should pay particular attention to women, who represent the population with the higher use of herbal preparations, and thus the higher risk of potential related AEs [60].

Furthermore, certain patients could have genetic predisposition leading to hepatotoxicity, such as cytochrome P450 polymorphisms promoting toxic accumulation of metabolites [61–64]. Several liver diseases (e.g., hepatitis, cirrhosis, etc.) that are possible alternative causes for liver damage

were excluded both for our patient and for the majority of cases reported in the literature.

The risk of herb–drug interaction (HDI), a well-recognized public health problem leading to AEs, could not be excluded in all reported cases [65]. Concomitant intake of herbal supplements and prescribed medications is very commonly reported in patients suffering from chronic diseases, and HDI has been documented in several observational studies and case reports [66–68].

Currently, the harmful potential of herbal supplements is not systematically investigated before the products are made available to the general population. This lack of information compounded the difficulties in event-reporting and history-taking concerning herbal supplement composition and use [64].

In a prospective study conducted in the United States, herbal and dietary supplements are found to be implicated in 10% of DILI cases [69]. A double-blind, randomized crossover trial performed in Australia on 8 diabetic patients and 12 healthy subjects who received intraduodenal infusion of HCA, did not detect differences in sensations of hunger, fullness, and nausea between HCA patients and control individuals [70]. Al-kuraishy and colleagues (2016) studied the effect of orlistat alone and in combination with GC in 99 obese male patients randomized to orlistat alone (120 mg/die), GC in capsules (166 mg/die) and a third group treated with both orlistat and GC. All groups included 33 subjects. Compliance with treatment was defined as good, but in the GC treated group, patients reported side effects: headache (12 patients), heartburn (9), constipation (5), abdominal pain (4), flatulence (2), and diarrhea (3) [71]. In 2014, 60 overweight Brazilian women were randomized in two groups to receive standardized GC extract (2.4 g/die) or placebo for 60 days. During the treatment, the analysis of hepatic transaminases and creatinine clearance did not show signs of acute toxicity. Mainly the AEs reported during treatment with GC extract were gastric discomfort, increased evacuation, and nausea [72]. A literature review published in 2012 analyzed a total of 13 studies that report the mid-term effects of HCA administration (equivalent dose range 1500–4667 mg/day) in a total of 930 subjects. None of these papers find serious AEs attributable to the intake of GC extract: the main side effects were nausea and headache. Generally, there were no differences between patients treated with GC and control subjects in side effects frequency. Only one of the studies included reported leg cramps, heartburn, diarrhea, flatulence, increased appetite, headaches, stomach burn, and menstrual disorders [54].

Although evidence coming from the present work suggests a potential causal association between GC products exposure and development of HILI, our findings are limited by the lack of data on factors influencing the severity of HILI, as drug–drug interactions, HDIs, and presence of

acute on chronic liver injury (i.e., non-alcoholic steatohepatitis), especially for cases derived from the literature.

Therefore, further research is required to elucidate the efficacy and safety of GC long-term use in humans and, at the meantime, caution is needed when using GC supplements for weight management.

Conclusion

The constant influx of newly developed drugs and a growing risk from unfamiliar herbal and dietary supplements are making HILI an increasing and significant clinical challenge that can lead to acute liver failure, and to the requirement for liver transplantation. Although herbal hepatotoxicity is of great clinical and regulatory importance, lack of a stringent causality assessment remains a major issue for patients with suspected HILI. Since most studies in humans have been conducted on small samples and mainly in the short term, patients and healthcare professionals should be cautious when interpreting GC extracts efficacy and safety evidences available in literature. In this clinical context, further studies can be conducted to isolate, purify, and examine the effects of herbal active principles, especially because they are often used over the counter and with no medical supervision. Efforts might lead to an appropriate use of food supplements, as those taken for weight control, ensuring the best efficacy and safety for all patients, especially women. Continuous monitoring of herbal dietary supplements should be promoted to finally characterize their risk profile, thus supporting regulatory bodies for appropriate actions.

Compliance with ethical standards

Conflict of interest The authors declare that they have no conflict of interest.

Statement of human and animal rights This article does not contain any studies with human participants or animals performed by any of the authors.

Informed consent None.

References

- 10 facts on obesity. <http://www.who.int/features/factfiles/obesity/en/>. Accessed 07 May 2018
- Skeie G, Braaten T, Hjartaker A, Lentjes M, Amiano P, Jakszyn P et al (2009) Use of dietary supplements in the European prospective investigation into cancer and nutrition calibration study. *Eur J Clin Nutr* 63(Suppl 4):S226–S238
- Dietz B, Bolton JL (2007) Botanical dietary supplements gone bad. *Chem Res Toxicol* 20:586–590

4. Pittler MH, Schmidt K, Ernst E (2005) Adverse events of herbal food supplements for body weight reduction: systematic review. *Obes Rev* 6:93–111
5. Bray GA (2008) Are non-prescription medications needed for weight control? *Obesity* 16:509–514
6. Pajor EM, Oenema A, Eggers SM, de Vries H (2017) Exploring beliefs about dietary supplement use: focus group discussions with Dutch adults. *Public Health Nutr* 20:2694–2705
7. Garcia-Cortes M, Robles-Diaz M, Ortega-Alonso A, Medina-Caliz I, Andrade RJ (2016) Hepatotoxicity by dietary supplements: a Tabular listing and clinical characteristics. *Int J Mol Sci* 17:537
8. Fassina P, Scherer Adami F, Terezinha Zani V, Kasper Machado IC, Garavaglia J, Quevedo Grave MT et al (2015) The effect of *Garcinia cambogia* as coadjuvant in the weight loss process. *Nutr Hosp* 32:2400–2408
9. Semwal RB, Semwal DK, Vermaak I, Viljoen A (2015) A comprehensive scientific overview of *Garcinia cambogia*. *Fitoterapia* 102:134–148
10. Onakpoya I, Hung SK, Perry R, Wider B, Ernst E (2011) The use of garcinia extract (Hydroxycitric Acid) as a weight loss supplement: a systematic review and meta-analysis of randomised clinical trials. *J Obes* 2011:509038
11. Ohia SE, Opere CA, LeDay AM, Bagchi M, Bagchi D, Stohs SJ (2002) Safety and mechanism of appetite suppression by a novel hydroxycitric acid extract (HCA-SX). *Mol Cell Biochem* 238:89–103
12. Mazzanti G, Moro PA, Raschi E, Da Cas R, Menniti-Ippolito F (2017) Adverse reactions to dietary supplements containing red yeast rice: assessment of cases from the Italian surveillance system. *Br J Clin Pharmacol* 83:894–908
13. Actis GC, Bugianesi E, Ottobrelli A, Rizzetto M (2007) Fatal liver failure following food supplements during chronic treatment with montelukast. *Digestive Liv Dis* 39:953–955
14. Teschke R, Wolff A, Frenzel C, Schwarzenboeck A, Schulze J, Eickhoff A (2014) Drug and herb induced liver injury: council for international organizations of medical sciences scale for causality assessment. *World J Hepatol* 6:17–32
15. Allen SF, Godley RW, Evron JM, Heider A, Nicklas JM, Thomas MP (2014) Acute necrotizing eosinophilic myocarditis in a patient taking *Garcinia cambogia* extract successfully treated with high-dose corticosteroids. *Can J Cardiol* 30(1732):e13–e15
16. Joseph DJM, Levine M (2014) Stress induced cardiomyopathy after ingestion of *Garcinia cambogia*. *Clin Toxicol* 52:739–740
17. Lopez AM, Kornegay J, Hendrickson RG (2014) Serotonin toxicity associated with *Garcinia cambogia* over-the-counter supplement. *J Med Toxicol* 10:399–401
18. Roche B, Chenoweth JA, Radke JB, Poppenga RH, Sutter ME (2014) Hypoglycemia associated with *Garcinia Cambogia* ingestion. *Clin Toxicol* 52:736
19. Sikka G, Gupta A, Bachan M, Khan Z (2016) “Uber-trim” causes immune thrombocytopenic purpura: a life threatening case report. *Chest* 150:392A
20. Bystrak T, Cervera-Hernandez ME, Reddy N, King Z, Bratberg J (2017) *Garcinia Cambogia*, diabetic ketoacidosis, and pancreatitis. *R I Med J* 100:48–50
21. Sidhu RLS, Khehra L (2016) *Garcinia cambogia*: a link between the “miracle” weight loss pill and acute pancreatitis. *Am J Gastroenterol* 111:S560–S561
22. Dehoney S, Wellein M (2009) Rhabdomyolysis associated with the nutritional supplement Hydroxycut. *Am J Health Syst Pharm* 66:142–148
23. Hines EQDTE, Melville LD, Su MK (2015) Severe rhabdomyolysis associated with *Garcinia cambogia*. *Clin Toxicol* 53:746–747
24. Mansi IA, Huang J (2004) Rhabdomyolysis in response to weight-loss herbal medicine. *Am J Med Sci* 327:356–357
25. Cotovio G, Oliveira-Maia AJ (2017) Hypomania induced by a *Garcinia cambogia* supplement. *Aust N Z J Psychiatry* 51:641–642
26. Narasimha A, Shetty PH, Nanjundaswamy MH, Viswanath B, Bada Math S (2013) Hydroxycut—dietary supplements for weight loss: can they induce mania? *Aust N Z J Psychiatry* 47:1205–1206
27. Nguyen DC, Timmer TK, Davison BC, McGrane IR (2017) Possible *Garcinia cambogia*-induced mania with psychosis: a case report. *J Pharm Pract* 1:897190017734728
28. Wong MK, Darvishzadeh A, Maler NA, Bota RG (2016) Five supplements and multiple psychotic symptoms: a case report. *Prim Care Companion CNS Disord*. <https://doi.org/10.4088/PCC.15br01856>
29. Hendrickson BP, Shaikh N, Occhiogrosso M, Penzner JB (2016) Mania induced by *Garcinia cambogia*: a case series. *Prim Care Companion CNS Disord*. <https://doi.org/10.4088/PCC.15i01890>
30. Chen GC, Ramanathan VS, Law D, Funchain P, Chen GC, French S et al (2010) Acute liver injury induced by weight-loss herbal supplements. *World J Hepatol* 2:410–415
31. Corey R, Werner KT, Singer A, Moss A, Smith M, Noelting J et al (2016) Acute liver failure associated with *Garcinia cambogia* use. *Ann Hepatol* 15:123–126
32. Dara L, Hewett J, Lim JK (2008) Hydroxycut hepatotoxicity: a case series and review of liver toxicity from herbal weight loss supplements. *World J Gastroenterol* 14:6999–7004
33. Elinav E, Pinsker G, Safadi R, Pappo O, Bromberg M, Anis E et al (2007) Association between consumption of Herbalife nutritional supplements and acute hepatotoxicity. *J Hepatol* 47:514–520
34. Fong TL, Klontz KC, Canas-Coto A, Casper SJ, Durazo FA, Davern TJ 2nd et al (2010) Hepatotoxicity due to hydroxycut: a case series. *Am J Gastroenterol* 105:1561–1566
35. Jones FJ, Andrews AH (2007) Acute liver injury associated with the herbal supplement hydroxycut in a soldier deployed to Iraq. *Am J Gastroenterol* 102:2357–2358
36. Kothadia JPRR, Olivera-Martinez M (2016) Hepatotoxicity associated with *Garcinia cambogia* used as a weight loss supplement. *Am J Gastroenterol* 111:S881
37. Lunsford KE, Bodzin AS, Reino DC, Wang HL, Busuttill RW (2016) Dangerous dietary supplements: *Garcinia cambogia*-associated hepatic failure requiring transplantation. *World J Gastroenterol* 22:10071–10076
38. McDonnell WM, Bhattacharya R, Halldorson JB (2009) Fulminant hepatic failure after use of the herbal weight-loss supplement exilis. *Ann Intern Med* 151:673–674
39. Melendez-Rosado J, Snipelisky D, Matcha G, Stancampiano F (2015) Acute hepatitis induced by pure *Garcinia cambogia*. *J Clin Gastroenterol* 49:449–450
40. Schoepfer AM, Engel A, Fattinger K, Marbet UA, Criblez D, Reichen J et al (2007) Herbal does not mean innocuous: ten cases of severe hepatotoxicity associated with dietary supplements from Herbalife products. *J Hepatol* 47:521–526
41. Shim M, Saab S (2009) Severe hepatotoxicity due to Hydroxycut: a case report. *Dig Dis Sci* 54:406–408
42. Smith RJ, Bertilone C, Robertson AG (2016) Fulminant liver failure and transplantation after use of dietary supplements. *Med J Aust* 204:30–32
43. Stevens T, Qadri A, Zein NN (2005) Two patients with acute liver injury associated with use of the herbal weight-loss supplement hydroxycut. *Ann Intern Med* 142:477–478
44. Stickel F, Droz S, Patsenker E, Bogli-Stubler K, Aebi B, Leib SL (2009) Severe hepatotoxicity following ingestion of Herbalife nutritional supplements contaminated with *Bacillus subtilis*. *J Hepatol* 50:111–117
45. Vitalone A, Menniti-Ippolito F, Moro PA, Firenzuoli F, Raschetti R, Mazzanti G (2011) Suspected adverse reactions associated with herbal products used for weight loss: a case series reported

- to the Italian national institute of health. *Eur J Clin Pharmacol* 67:215–224
46. The use of the WHO-UMC system for standardised case causality assessment. <https://www.who-umc.org/media/2768/standardised-case-causality-assessment.pdf>. Accessed 07 May 2018
 47. Fontana RJ, Watkins PB, Bonkovsky HL, Chalasani N, Davern T, Serrano J et al (2009) Drug-Induced Liver Injury Network (DILIN) prospective study: rationale, design and conduct. *Drug Saf* 32:55–68
 48. Hayamizu K, Hirakawa H, Oikawa D, Nakanishi T, Takagi T, Tachibana T et al (2003) Effect of *Garcinia cambogia* extract on serum leptin and insulin in mice. *Fitoterapia* 74:267–273
 49. Amin KA, Kamel HH, Abd Eltawab MA (2011) The relation of high fat diet, metabolic disturbances and brain oxidative dysfunction: modulation by hydroxy citric acid. *Lipids Health Dis* 10:74
 50. Oluymi KA, Omotuyi IO, Jimoh OR, Adesanya OA, Saalu CL, Josiah SJ (2007) Erythropoietic and anti-obesity effects of *Garcinia cambogia* (bitter kola) in Wistar rats. *Biotechnol Appl Biochem* 46:69–72
 51. Heymsfield SB, Allison DB, Vasselli JR, Pietrobello A, Greenfield D, Nunez C (1998) *Garcinia cambogia* (hydroxycitric acid) as a potential antiobesity agent: a randomized controlled trial. *JAMA* 280:1596–1600
 52. Cheng IS, Huang SW, Lu HC, Wu CL, Chu YC, Lee SD et al (2012) Oral hydroxycitrate supplementation enhances glycogen synthesis in exercised human skeletal muscle. *Br J Nutr* 107:1048–1055
 53. Amin KA, Kamel HH, Abd Eltawab MA (2011) Protective effect of *Garcinia* against renal oxidative stress and biomarkers induced by high fat and sucrose diet. *Lipids health Dis* 10:6
 54. Marquez F, Babio N, Bullo M, Salas-Salvado J (2012) Evaluation of the safety and efficacy of hydroxycitric acid or *Garcinia cambogia* extracts in humans. *Crit Rev Food Sci Nutr* 52:585–594
 55. Cavalieri ML, D'Agostino D (2017) Drug-, herb- and dietary supplement-induced liver injury. *Archivos argentinos de Pediatría* 115:e397–e403
 56. Frenzel C, Teschke R (2016) Herbal hepatotoxicity: clinical characteristics and listing compilation. *Int J Mol Sci*. <https://doi.org/10.3390/ijms17050588>
 57. Asghar M, Monjok E, Kouamou G, Ohia SE, Bagchi D, Lokhandwala MF (2007) Super CitriMax (HCA-SX) attenuates increases in oxidative stress, inflammation, insulin resistance, and body weight in developing obese Zucker rats. *Mol Cell Biochem* 304:93–99
 58. Kim YJ, Choi MS, Park YB, Kim SR, Lee MK, Jung UJ (2013) *Garcinia Cambogia* attenuates diet-induced adiposity but exacerbates hepatic collagen accumulation and inflammation. *World J Gastroenterol* 19:4689–4701
 59. Sanchez-Valle V, Chavez-Tapia NC, Uribe M, Mendez-Sanchez N (2012) Role of oxidative stress and molecular changes in liver fibrosis: a review. *Curr Med Chem* 19:4850–4860
 60. Dickinson A, MacKay D (2014) Health habits and other characteristics of dietary supplement users: a review. *Nutr J* 13:14
 61. Gallo E, Maggini V, Berardi M, Pugi A, Notaro R, Talini G et al (2013) Is green tea a potential trigger for autoimmune hepatitis? *Phytomedicine* 20:1186–1189
 62. Nicoletti P, Aithal GP, Bjornsson ES, Andrade RJ, Sawle A, Arrese M et al (2017) Association of liver injury from specific drugs, or groups of drugs, with polymorphisms in HLA and other genes in a genome-wide association study. *Gastroenterology* 152:1078–1089
 63. Krupa R, Czarny P, Wigner P, Wozny J, Jablkowski M, Kordek R et al (2017) The relationship between single-nucleotide polymorphisms, the expression of DNA damage response genes, and hepatocellular carcinoma in a polish population. *DNA Cell Biol* 36:693–708
 64. Brewer CT, Chen T (2017) Hepatotoxicity of herbal supplements mediated by modulation of cytochrome P450. *Int J Mol Sci*. <https://doi.org/10.3390/ijms18112353>
 65. Awortwe C, Makiwane M, Reuter H, Muller C, Louw J, Rosenkranz B (2018) Critical evaluation of causality assessment of herb-drug interactions in patients. *Br J Clin Pharmacol* 84(4):679–693
 66. Prasad GV, Wong T, Meliton G, Bhaloo S (2002) Rhabdomyolysis due to red yeast rice (*Monascus purpureus*) in a renal transplant recipient. *Transplantation* 74:1200–1201
 67. Wong AL, Chan TY (2003) Interaction between warfarin and the herbal product quilinggao. *Ann Pharmacother* 37:836–838
 68. Lee NJ, Fermo JD (2006) Warfarin and royal jelly interaction. *Pharmacotherapy* 26:583–586
 69. Kennedy J (2005) Herb and supplement use in the US adult population. *Clin Ther* 27:1847–1858
 70. Thazhath SS, Wu T, Bound MJ, Checklin HL, Standfield S, Jones KL et al (2016) Effects of intraduodenal hydroxycitrate on glucose absorption, incretin release, and glycemia in response to intraduodenal glucose infusion in health and type 2 diabetes: a randomised controlled trial. *Nutrition* 32:553–559
 71. Al-Kuraishy HM, Al-Gareeb AI (2016) Effect of orlistat alone or in combination with *Garcinia cambogia* on visceral adiposity index in obese patients. *J Intercult Ethnopharmacol* 5:408–414
 72. Vasques CA, Schneider R, Klein-Junior LC, Falavigna A, Piazza I, Rossetto S (2014) Hypolipemic effect of *Garcinia cambogia* in obese women. *Phytother Res* 28:887–891