



## Case report

## Eye-opening in brain death: A case report and review of the literature

Martina Focardi<sup>a</sup>, Barbara Gualco<sup>a</sup>, Maenia Scarpino<sup>b,\*</sup>, Manuela Bonizzoli<sup>c</sup>, Beatrice Defraia<sup>a</sup>, Riccardo Carrai<sup>b</sup>, Giovanni Lanzo<sup>b</sup>, Silvia Raddi<sup>a</sup>, Ilenia Bianchi<sup>a</sup>, Antonello Grippo<sup>b</sup>

<sup>a</sup> Forensic Medical Sciences, Health Sciences Department, University of Florence, Largo Brambilla 3, 50134 Florence, Italy

<sup>b</sup> Neurophysiology Unit, Careggi University Hospital, Florence, Italy

<sup>c</sup> Intensive Care Unit and Regional ECMO Referral Center, Careggi University Hospital, Florence, Italy



## ARTICLE INFO

## Article history:

Received 15 January 2022

Received in revised form 8 March 2022

Accepted 23 March 2022

Available online 19 May 2022

## Keywords:

Brain death

Cerebral angiography

Eyelid elevation

Physical examination spinal reflexes

## ABSTRACT

**Background:** According to Italian law, brain death is diagnosed when the patient is in a coma, showing the absence of respiratory drive under specific clinical conditions, and without any brain stem reflexes. On the other hand, presence of spinal reflexes, when correctly identified, does not hamper the diagnosis.

**Case report:** We present a case of eyelid elevation two seconds after thoracic pain stimulation in a patient who otherwise fulfilled all clinical and instrumental brain-death criteria due to a residual preserved function of the superior cervical ganglion.

**Conclusion:** Although the observed reflex is to be considered extracerebral, and therefore it should not hamper the diagnosis of BD, the authors propose implementing cerebral flow evaluation, considered “prudential”, as a preliminary assessment before determining BD.

Published by Elsevier B.V. on behalf of International Federation of Clinical Neurophysiology. This is an open access article under the CC BY-NC-ND license (<http://creativecommons.org/licenses/by-nc-nd/4.0/>).

## 1. Introduction

Brain death is defined as the complete and permanent absence of all brain functions (Busl and Greer, 2009). Protocols for ascertaining brain death vary widely from country to country (Kondziella, 2020). In Italy, a patient is considered brain dead when he is in a coma, showing apnoea under particular clinical parameters, and having no brain stem reflexes (Legge 29.12.1993 n. 578; Decreto Ministero della Salute 11.04.2008). On the other hand, presence of spinal reflexes, when correctly identified, does not hamper the diagnosis. However, distinguishing between “extracerebral” reflexes and persistent brainstem function at times is challenging, as in the case of eyelid elevation, which is determined by two separate mechanisms. In one case, it can be considered a residual brainstem activity due to the action of the eyelid elevator muscle that is innervated from the fibres of the III cranial nerve. In other cases, it can be considered an “extracerebral” reflex because of the action of the Muller’s muscle innervated from sympathetic fibres. We report a case of eyelid elevation following pain stimulation in a patient who met all clinical and instrumental brain-death criteria. Following a review of the literature, we propose an approach to similar cases to allow the timely diagnosis of legal

brain death, which is especially important in cases involving potential organ donors.

## 2. Case report

A 43-year-old woman with a history of craniopharyngioma and pituitary insufficiency was admitted to the emergency room in a deep coma state and acute renal failure following a urinary infection. Fifteen days after admission, her condition rapidly deteriorated, and she suddenly entered cardiopulmonary arrest. An electrocardiogram showed pulseless electrical activity. Cardiopulmonary resuscitation (CPR) was promptly started and 1 mg adrenaline was administered. She was intubated and moved to the intensive care unit (ICU). CPR continued for about two hours. After resuscitation, she remained comatose with bilateral mydriasis and a Glasgow Coma Scale (GCS) score of 3. Brain computed tomography (CT) showed brainstem and intraventricular haemorrhage with hydrocephalus in the brainstem. On the following day, 24 h after resuscitation, her neurological status had not changed; hence, a neurophysiological evaluation for the long-term neurological prognosis was performed (Scarpino et al., 2018). The electroencephalogram (EEG) showed an isoelectric pattern (Fig. 1), while the somatosensory evoked potentials (SEPs) after stimulation of the median nerves at the wrist revealed the absence of both bulbar and cortical responses in the presence of peripheral and spinal responses (Fig. 2). Since these neurophysiological findings suggested the presence of brain death (Scarpino et al., 2017), her

\* Corresponding author at: Careggi University Hospital, Largo Brambilla 3, 50134 Florence, Italy.

E-mail address: [scarpinom@aou-careggi.toscana.it](mailto:scarpinom@aou-careggi.toscana.it) (M. Scarpino).

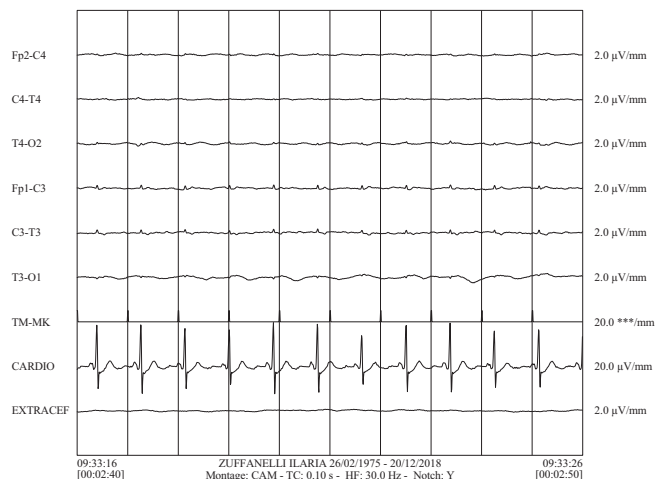

Fig. 1. Isoelectric EEG recorded 24 h after resuscitation.

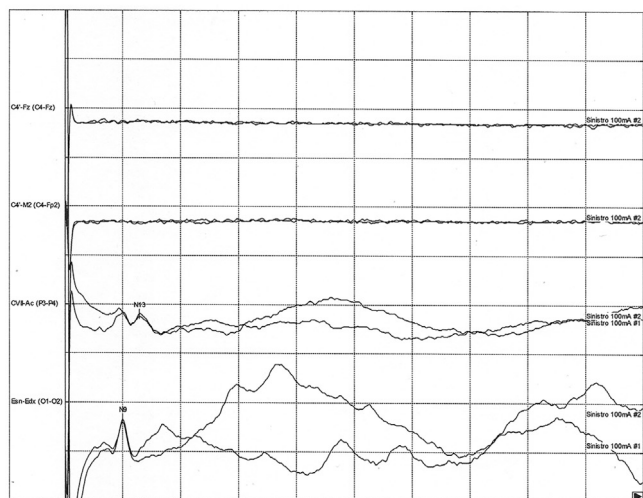
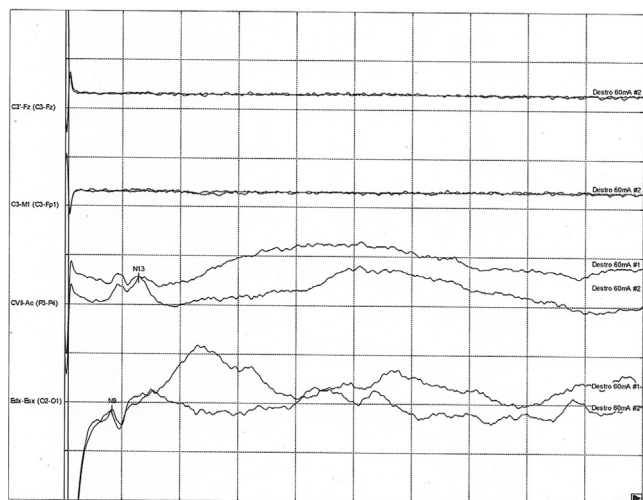


Fig. 2. Left- (A) and right-sided (B) median somatosensory evoked potentials. The only evoked response recorded were the brachial plexus (Erb-Erb) and cervical (Cv7-Ac) potential. Neither bulbar (C4-M2; C3-M1) or cortical (C3-Fz; C4-Fz) responses were recordable.

brainstem function was tested. Neurological examination showed the absence of the photomotor, oculovestibular, corneal, gag, and cough cranial reflexes. Moreover, the patient, after being hypoven-

tilated (4 acts per minute with a tidal volume of 250 cc) until reaching a blood gas CO<sub>2</sub> value >60 mmHg, was disconnected for one minute from the ventilator, showing the absence of respiratory drive. Even though there was no facial motor response after painful stimulation in the trigeminal territory, the patient presented partial bilateral eyelid elevation, after about two seconds, in response to painful stimulation of the left or right nipple (Fig. 3). Immediately after cessation of the painful stimulation, the eyelid slowly returned to baseline. Inspection of the pupils showed no diametric change. Consequently, intensivists suspended the brain death ruling and scheduled a reevaluation. Two hours later, after re-examination, the same neurological signs were observed. The diagnosis of brain death was again not established and another evaluation was scheduled for the following day. Given the persistence of the same clinical conditions associated with an EEG confirming an isoelectric pattern for the other two days (three days subsequent to cardiac arrest), a cerebral CT angiography was thus arranged, showing no opacification of intracranial arterial circulation and of venous circulation. Therefore, the medical board convened on the same day and established a diagnosis of BD. Eyelid elevation after painful nipple stimulation was no longer present in addition to the absence of other confounding factors for reaching the diagnosis of BD, including episodes of hypotension, hypoxaemia or drug administration. The legal tutor consented to organ donation and no autopsy was performed.

### 3. Ethical statements

According to Italian law, case reports do not need to be approved by the Ethics Committee; however, the work complies with the ethical guidelines of the Helsinki declaration and the Oviedo convention, as well as the ethical standards of the University of Florence.

### 4. Discussion

According to Italian law (Legge 29.12.1993 n. 578; Decreto Ministero della Salute 11.04.2008), a first documentation of clinical signs, a repetition of clinical testing and a confirmation of the absence of bioelectrical activity in the brain (EEG) are required in order to establish a diagnosis of brain death (Zappa et al., 2020). The prerequisite for brain death assessment is a body temperature not altering the functions of the brain (usually >35 °C), and a known cause of brain injury. To establish the diagnosis, a Legal Committee must include a medico-legal doctor (delegate of the Head of Hospital or a pathologist), an anaesthetist and a neurophysiologist (either a neurologist or neurosurgeon with an expertise in electroencephalography) who must express a unanimous judgment on the time of death if the specific criteria are present

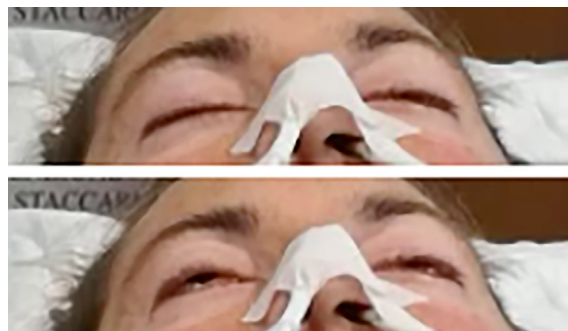

Fig. 3. Eyelid movements. A. Before stimulation. B. Bilateral eyelid opening in response to nipple painful stimulation.

after two evaluations taken 6 h apart (Decreto Ministero della Salute 11.04.2008). Criteria (Legge 29.12.1993 n. 578; Zappa et al., 2020; Wijdicks et al., 2010; Centro Nazionale Trapianti, 2009) for brain death diagnosis are summarized in Table 1. Spontaneous or triggered spinal activity has no relevance in the diagnosis of brain death (Decreto Ministero della Salute 11.04.2008). During brain death assessment, the request for organ donation is made to whoever legally qualifies.

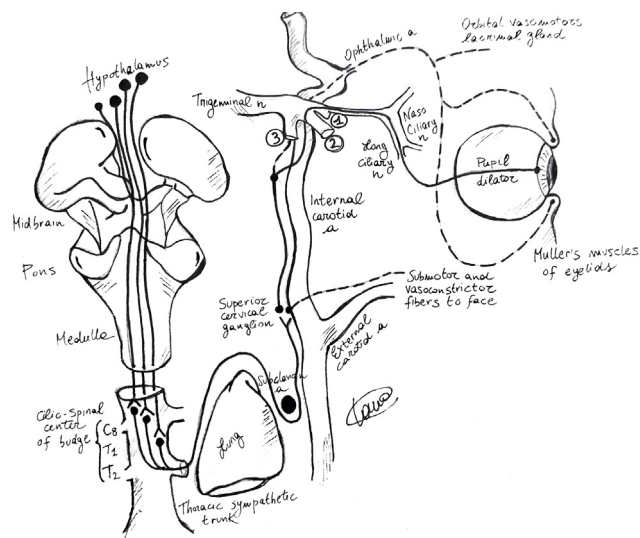
We presented the case of a patient with a primary acquired brain injury who met all of the clinical criteria for brain death except for the presence of an unknown reflex: bilateral eyelid elevation evoked by painful stimulation on both the right and left nipples, which caused a delay in reaching a diagnosis of brain death.

Eyelid elevation is determined by the action of two muscles with different innervation. This neurological sign might have occurred due to the action of the eyelid elevator muscle that is innervated from the fibres of the III cranial nerve originating in the oculomotor nucleus, located in the mesencephalon. On the other hand, the eyelid elevation might result from Muller's sympathetic muscle function. The sympathetic fibres, originating from the superior cervical ganglion, are divided into two branches. The first branch travels to where the carotid joins the VI cranial nerve and later the ophthalmic branch of the V cranial nerve, entering the orbit through the optic foramen and supplying the pupil (Parkinson et al., 1978). The second branch, instead, which is directed to the Muller's muscle, leaves the intrapetrous carotid plexus through the petrosal nerve, vidian nerve, and sphenopalatine ganglion reaching the orbit via the inferior orbital fissure (Duke-Elder and Wybar, 1961) (Fig. 4).

In our case, given both the strong clinical and instrumental (SEPs; cranial CT angiography) evidence of lack of any preserved brainstem function, the eyelid opening has been attributed to a residual preserved function of the superior cervical ganglion which was activated by thoracic pain fibres following stimulation to both right and left nipple levels.

Additionally, the patient's partial and slow eyelid opening was consistent with the activity of a smooth muscle, such as the Muller's muscle, rather than with the activity of a striated skeletal muscle such as the eyelid elevator muscle, innervated by the III cranial nerve.

Finally, the absence of pupil dilation in the presence of partial eyelid elevation could be attributed to a greater resistance to the loss of intracranial blood flow of the fibres innervating the Muller's



**Fig. 4.** Drawing showing the anatomy of the oculo-sympathetic pathway. Sympathetic fibers in the posterolateral hypothalamus pass through the lateral brain stem and to the cilio-spinal center of Budge and Waller in the intermedialateral gray column of the spinal cord at C8–T1. Preganglionic sympathetic neurons exit from the Cilio-spinal center of Budge and pass above the pulmonary apex and ascend up the carotid sheath to the Superior cervical ganglion. The postganglionic sympathetic neurons originate in the superior cervical ganglion and travel up the wall of the internal carotid artery. The sympathetic fibers, which travel with the carotid and supply the pupil, join the sixth nerve and later the ophthalmic branch (1) of the 5th nerve to enter the orbit through the optic foramen, whereas sympathetic fibers to Muller's muscle leave the intrapetrous carotid plexus through the petrosal nerve, vidian nerve, and the sphenopalatine ganglion reaching the orbit via the inferior orbital fissure. Abbreviations: a, artery; n, nerve.

muscle compared to the fibres innervating the pupil (Santamaria et al., 1999).

According to the literature, patients fulfilling all clinical and instrumental criteria of brain death with the exception of neurological signs of eyelid openings are described in only a few previously published papers and all of them differ in some way from our case (Santamaria et al., 1999, Friedman, 1984).

In the paper by Friedman (Friedman, 1984), the author described a monolateral eyelid opening triggered by twisting the ipsilateral nipple. A similar case was also described by Santamaria et al. (Santamaria et al., 1999). Both authors considered the eyelid opening to be an extracranial reflex, although brain death was not declared in either case. Furthermore, the cause of death in the first case (Friedman, 1984) was unknown, whereas the patient in the second case (Santamaria et al., 1999) died from cardiac arrest. To date, we have not found any other similar case reports.

Clinical and instrumental features of these previous patients satisfying clinical and instrumental criteria of brain death except for the presence of an eyelid opening sign are reported in Table 2.

In our case, the patient showed bilateral eyelid elevation evoked by painful stimulation of both right and left nipple levels, regardless of the presence of all other clinical and instrumental (EEG) criteria for a diagnosis of brain death. The brain death diagnosis was halted in order to monitor the clinical conditions. However, based on the hypothesis that this neurological sign was obtained by an extracerebral reflex caused by the presence of a residual preserved function of the superior cervical ganglion activated by thoracic pain fibres following stimulation at both the right and left nipple levels, an angiography was thus performed, revealing the absence of cerebral flow.

In our experience, backed by the scientific literature, a slow partial eyelid opening in response to painful nipple stimulation, with no changes in the pupil diameter, rarely occurs in brain death

**Table 1**  
Clinical and instrumental criteria for brain death ascertainment.

Clinical criteria	Instrumental criteria
Unconsciousness	Electroencephalogram for 30 minutesMandatory to revealing absence of spontaneous or triggered brain electric activity greater than 2 microvolts in all cerebral regions
absence of following brain stem reflexes: <ul style="list-style-type: none"> <li>Oculovestibular reflex</li> <li>Corneal reflex</li> <li>Gag reflex</li> <li>Cough reflex</li> <li>Pupillary inactivity to bright light in both eyes</li> <li>Motor response after painful stimulation applied to the trigeminal and facial territories;</li> </ul>	cerebral CT angiography or transcranial Doppler:only if <ul style="list-style-type: none"> <li>– using of drugs depressant on cerebral functions</li> <li>– impossibility of evaluating brain stem reflexes or electroencephalogram</li> <li>– age &lt; 12 months</li> <li>– post-anoxic coma from cardiac arrest that occurred within 24 h</li> </ul>
absence of spontaneous breath for 60 sec without ventilator if pCO <sub>2</sub> > 60 mmHg and pH < 7.40	

**Table 2**

Relevant clinical features of patients with periodic eyelid opening and those with opening after painful stimulation.

Source	Sex	Age years	Etiology of Brain Injury	Time to fulfilling of BD criteria	Characteristics of eye opening	EEG	Other test	Cause of death
Friedman, 1984	M	57	Prolonged Hypotension	24 h	Monolateral, triggered by twisting ipsilateral nipple Associated with abdominal movements.	Isoelectric	Stellate block	Not known
Santamaria et al., 1999	M	47	Brain-stem Hematoma	4 days	Monolateral, triggered by twisting ipsilateral nipple No other motor manifestations	Isoelectric	Cerebral Angiography	Cardiac Arrest
Present Case	F	43	Intraparenchinal hemorrhage and cardiac arrest	24 h	Bilateral Triggered by twisting left or right nipple. No associated with other motor manifestations	Isoelectric	Somatosensory Evoked Potentials, Cerebral Angiography	Brain Death

BD = Brain Death; M = Male; F = Female.

patients. This exceptional clinical phenomenon should not prevent a diagnosis of BD in a patient who otherwise fulfils the standard criteria for BD, i.e., coma, apnoea, and loss of oculo-vestibular, corneal, gag, cough, and photomotor reflexes. This unusual response may suggest a residual lower cervical/upper thoracic cord sympathetic function. Notwithstanding the pathophysiological opinion confirming the extracranial origin of eyelid opening, a specific test consisting of the stellate ganglion block could ideally be performed for the confirmation of the clinical suspicion but, this procedure is to date not readily available in the clinical practice. Although the eyelid elevation in our case was considered of reflex nature, the legal committee considered it prudent to also perform cerebral flow evaluation, considering that Italian law requires the observations to proceed in case the BD criteria are met.

Therefore, in this particular clinical condition of slow eyelid opening in response to painful stimulation of the left or right nipple in a patient who otherwise fulfilled all clinical and instrumental BD criteria, we believe that the implementation of cerebral flow evaluation, as well as already performed for other confounding factors, is considered “prudential” as a preliminary assessment prior to determining BD to confirm the absence of any brainstem function.

### Acknowledgements

We thank Antonio Maiorelli for drawing the Fig. 4.

### Conflict of Interest

The authors declare that there is no conflict of interest regarding the publication of this article.

### Funding information

This research received no grant from funding agencies in the public, commercial, or not-for-profit sectors.

### References

- Busl, K.M., Greer, D.M., 2009. Pitfalls in the diagnosis of brain death. *Neurocrit. Care* 11, 276–287. <https://doi.org/10.1007/s12028-009-9231-y>.
- Centro Nazionale Trapianti (CNT), 2009. Determinazione di morte con standard neurologico. Elementi informativi essenziali.
- Decreto Ministero della Salute 11 Aprile 2008, Aggiornamento del decreto 22 agosto 1994, n. 582: “Regolamento recante le modalità per l'accertamento e la certificazione di morte”.
- Duke-Elder S., Wybar K.C., 1961. The anatomy of the visual system. In: Duke-Elder S (editor). *System of Ophthalmology*, vol II. Mosby, St. Louis, pp. 849–857.
- Friedman A.J., 1984. Sympathetic response and brain death. *Arch. Neurol.* 41: 15.
- Kondziella, D., 2020. The neurology of death and the dying brain: A pictorial essay. *Front. Neurol.* 11, 736. <https://doi.org/10.3389/fneur.2020.00736>.
- Legge 29.12.1993 n. 578. Norme per l'accertamento e la certificazione di morte.
- Santamaria, J., Orteu, N., Iranzo, A., Tolosa, E., 1999. Eye opening in brain death. *J. Neurol.* 246, 720–722. <https://doi.org/10.1007/s004150050439>.
- Scarpino, M., Lanzo, G., Lolli, F., Moretti, M., Carrai, R., Migliaccio, M.L., Spalletti, M., Bonizzoli, M., Peris, A., Amantini, A., Grippo, A., 2017. Is brain computed tomography combined with somatosensory evoked potentials useful in the prediction of brain death after cardiac arrest? *Neurophysiol. Clin.* 47, 327–335. <https://doi.org/10.1016/j.neucli.2017.07.002>.
- Scarpino, M., Grippo, A., Lanzo, G., Lolli, F., 2018. The burden of clinical neurophysiology for the neurological prognosis of coma. *Future Neurol.* 13, 127–129. <https://doi.org/10.2217/fnl-2018-0013>.
- Wijdicks, E.F., Varelas, P.N., Gronseth, G.S., Greer, D.M., American Academy of Neurology, 2010. Evidence-based guideline update: determining brain death in adults: report of the Quality Standards Subcommittee of the American Academy of Neurology. *Neurology* 74, 1911–1918. <https://doi.org/10.1212/WNL.0b013e3181e242a8>.
- Zappa, S., Fagoni, N., Bertoni, M., Selli, C., Venturini, M.A., Finazzi, P., Metelli, M., Rasulo, F., Piva, S., Latronico, N., Imminent Brain Death (IBD) Network Investigators, 2020. Determination of imminent brain death using the full outline of unresponsiveness score and the Glasgow Coma Scale: A prospective, multicenter, pilot feasibility study. *J. Intensive Care Med.* 35, 203–207.