



Veno-venous extra-corporeal membrane oxygenation in complex tracheobronchial resection

Luca Voltolini^{1,2}, Alberto Salvicchi¹, Alessandro Gonfiotti^{1,2}, Sara Borgianni¹, Giovanni Cianchi³, Giovanni Mugnaini¹, Stefano Bongiolatti¹

¹Thoracic Surgery Unit, Careggi University Hospital, Florence, Italy; ²Department of Experimental and Clinical Medicine, University of Florence, Florence, Italy; ³Intensive Care Unit and Regional ECMO Referral Center, Careggi University Hospital, Florence, Italy

Contributions: (I) Conception and design: S Bongiolatti, L Voltolini; (II) Administrative support: S Bongiolatti, L Voltolini; (III) Provision of study materials or patients: S Bongiolatti, A Salvicchi, A Gonfiotti; (IV) Collection and assembly of data: S Bongiolatti, G Mugnaini; (V) Data analysis and interpretation: S Bongiolatti, G Cianchi; (VI) Manuscript writing: All authors; (VII) Final approval of manuscript: All authors.

Correspondence to: Alberto Salvicchi, MD. Thoracic Surgery Unit, Careggi University Hospital, Largo Brambilla, 1, 50134 Florence, Italy. Email: alberto.salvicchi@libero.it.

Background: Elective extra-corporeal membrane oxygenation (ECMO) is rarely used in thoracic surgery, apart from lung transplantation. The purpose of this study was to summarize our institutional experience with the intraoperative use of veno-venous (VV) ECMO in selected cases of main airway surgery.

Methods: We retrospectively analyzed the data of 10 patients who underwent main airway surgery with the support of VV-ECMO between June 2013 and August 2022.

Results: Surgical procedures included: three carinal resection and reconstruction with complete preservation of the lung parenchyma, one right upper double-sleeve lobectomy and hemi-carinal resection, and one sleeve resection of the left main bronchus after previous right lower bilobectomy, for thoracic malignancies; four tracheal/carinal repair for extensive traumatic laceration; one extended tracheal resection due to post-tracheostomy stenosis in a patient who had previously undergone a left pneumonectomy. The median intraoperative VV-ECMO use was 162.5 minutes. In three cases with complex resection and reconstruction of the carina and in one case of extended post-tracheostomy stenosis and previous pneumonectomy, high-flow VV-ECMO allowed interruption of ventilation for almost 3 hours. In four patients, VV-ECMO was prolonged in the postoperative period to ensure early extubation. There were no perioperative deaths, no complications related to the use of ECMO and no intraoperative change in the planned type of ECMO. Significant complications occurred only in one patient who developed a small anastomotic dehiscence that led to stenosis and required placement of a Montgomery tube. At the median follow-up of 30 months, all 10 patients were still alive.

Conclusions: The use of intraoperative VV-ECMO allows safe and precise performance of main airway surgery with minimal postoperative morbidity in patients requiring complex resections and reconstructions and in cases that cannot be managed with conventional ventilation techniques.

Keywords: Complex airway surgery; veno-venous extra-corporeal membrane oxygenation (VV-ECMO); veno-arterial extra-corporeal membrane oxygenation (VA-ECMO); tracheal resection; extracorporeal life support (ECLS)

Submitted Sep 07, 2023. Accepted for publication Dec 21, 2023. Published online Feb 27, 2024.

doi: 10.21037/jtd-23-1416

View this article at: <https://dx.doi.org/10.21037/jtd-23-1416>

Introduction

The two most important requirements for airway surgery are adequate oxygenation and safe airway control. Although in the vast majority of cases airway surgery can be successfully performed with conventional cross-table ventilation with periodic apneic phases, there are situations where airway control is predictably very difficult, if not impossible. In complex airway surgery cases, intraoperative extracorporeal life support (ECLS) may be the right way to achieve both adequate gas exchange and safe airway control. In recent years, veno-arterial extra-corporeal membrane oxygenation (VA-ECMO) and veno-venous (VV) ECMO (VV-ECMO) (1) have replaced conventional cardio-pulmonary bypass (CPB) thanks to their undeniable advantages (2-4).

Firstly, ECMO offers a clear, unobstructed (tubeless) surgical field (especially with peripheral cannulation), allowing precise and rapid dissection and reconstruction. Secondly, ECMO can fully support breathing. On the other hand, the risk of bleeding can be minimized by only partial heparinization and monitoring of coagulation with the various methods available, such as activated clotting time (ACT) or activated partial thromboplastin time (aPTT) (5,6). So, more extended the resection is, more complex the reconstruction is, more the patient is intolerant to apnea

because of limited pulmonary reserve then ECMO represents a real advantage (7-9). However, despite the potential advantages, elective ECMO is rarely used in thoracic surgery, apart from lung transplantation (10). Even the configuration of the device is controversial. Theoretically, VA-ECMO should be used in cases of hemodynamic instability or heart failure, while VV-ECMO is sufficient when only respiratory support is required. However, the boundaries are quite labile and the decision also depends on the preference of the treating physicians (10,11). Thus, the most important case series ever published concerning the carinal surgery using ECMO comes from the Vienna group in which VA-ECMO was used (4). In fact, only case reports or very small retrospective series or technical papers have been published reporting on main airway surgery on VV-ECMO.

The aim of this study was to summarize our institutional experience with the intraoperative use of VV-ECMO in selected cases of main airway surgery, either due to the complexity of the planned reconstruction or in situations where the patient's limited respiratory reserve prohibits conventional ventilation techniques. We present this article in accordance with the STROBE reporting checklist (available at <https://jtd.amegroups.com/article/view/10.21037/jtd-23-1416/rc>).

Methods

We retrospectively reviewed the medical records of 73 patients who underwent main airway surgery at Careggi University Hospital of Florence between June 2013 and August 2022. The data of 10 patients (study group) who underwent main airway surgery under VV-ECMO support were collected and analyzed in terms of clinic-pathological, perioperative and follow-up outcomes. This retrospective study was conducted in accordance with the Declaration of Helsinki (as revised in 2013). The retrospective analysis of the data did not require approval of the Institutional Review Board. Informed consent was obtained from each patient at the moment of the hospital admission.

As cardiocirculatory support was not considered necessary, VV-ECMO with peripheral percutaneous cannulation in double site configuration under ultrasound guidance using the Seldinger technique was performed in all cases of the study group. VV-ECMO with double cannulation was preferred to VV-ECMO with single cannulation as it allows a higher extracorporeal blood flow and less recirculation and thus better gas exchange.

Highlight box

Key findings

- Veno-venous extra-corporeal membrane oxygenation (VV-ECMO) is a safe and effective ventilation strategy for complex airway surgery.

What is known and what is new?

- The majority of main airways surgery can be performed with standard cross-field ventilation and periodic apneic phases.
- However, there are situations where the use of extracorporeal life support (e.g., VV-ECMO) is almost mandatory to maintain a stable respiratory condition, such as previous extensive contralateral lung resection, traumatic disruption of the main airways or tumors that affect both bronchial systems and preclude safe intubation and ventilation.

What is the implication, and what should change now?

- VV-ECMO enables the safe and precise performance of complex main airway procedures with minimal postoperative morbidity and could be the extracorporeal support of choice in cases that cannot be managed with conventional ventilation techniques.

VV-ECMO cannulation was performed by the anesthesiologists and cardiologists of the institutional ECMO team after a single administration of unfractionated heparin (2,000–5,000 I.U.), with the exception of two patients (cases 1 and 4) who did not receive anticoagulation due to an extensive post-traumatic tracheal laceration. An ECMO referral center for respiratory diseases is active in our institution with a mobile ECMO team available 24 hours/day, 365 days/year, to serve other hospitals in Tuscany and central Italy (12,13).

ECMO was performed using the Maquet Cardiohelp System (GETINGE AB, Gothenburg, Sweden), Heart-Lung Support (HLS) cannulae (GETINGE AB): a multistage drainage cannula of 23 or 25 F and an infusion cannula of 17–19 F were used according to the size of the patient and the vein diameter determined by ultrasound before cannulation.

If possible, the internal jugular vein and the femoral vein were our preferred cannulation sites. In patients with cervical trauma, it was necessary to use the two femoral veins instead. In elective patients, transesophageal echocardiography was performed to assist with optimal cannula placement and to monitor cardiac function during surgery.

To limit bleeding during surgery, heparin infusion was maintained at low intensity regimen and targeted to an aPTT of 50–60 s (5,6). Anticoagulation was measured at the bedside using a portable device (Hemocron Signature Elite, Werfen-Instrumentation Laboratory SpA, Milan, Italy). The aPTT was preferred to the ACT to allow a more precise assessment at lower levels of anticoagulation (14). Heparin infusion was interrupted during ECMO removal or in case of bleeding. Heparin was continued after surgery and until ECMO was withdrawn and heparin infusion was suspended 30–60 min before de-cannulation with no reversal therapy. In the early postoperative period, standard clinical monitoring was performed, including serial blood gas analyses and daily chest X-rays in trans-thoracic patients. If necessary, flexible bronchoscopy was performed to remove secretions. The neck was always kept in a slightly flexed position, with some pillows being used. In selected cases of very complex airway anastomoses or in particularly frail patients, VV-ECMO was prolonged after surgery to ensure safe extubation and to maintain low pressure ventilation on challenging anastomoses. A flexible bronchoscopy was performed before discharge from hospital and on postoperative day 7 to assess regular healing of the anastomosis.

Statistical analysis and data reporting

Continuous variables were expressed as median and interquartile range (IQR), whereas the categorical variables were depicted as the count and percentage. Statistical analysis was performed using SPSS 24.0 software (IBM SPSS Statistics for Macintosh, Version 24.0., IBM Corp, Armonk, NY, USA).

Results

Of the 73 patients who underwent main airway surgery, 63 (86.3%) patients underwent surgery (n=13 tracheal sleeve pneumonectomies, n=48 tracheal resections and anastomoses, n=2 tracheoesophageal fistula repairs) by cross-field ventilation, while 10 patients [7 males and 3 females, median age 61.5 (IQR, 38) years] who formed the study group underwent main airway surgery under VV-ECMO support placed through either a femorofemoral (n=5) or femoral-jugular (n=5) cannula at the start of the procedure.

Table 1 lists the indications for the use of VV-ECMO. In four cases, the indication for ECMO support was the complexity of the planned trachea-bronchial reconstruction, including three cases of carinal resection and reconstruction with complete parenchymal preservation (cases 2, 8 and 9; *Figure 1*) and one case of double-sleeve right upper lobectomy with hemi-carinal resection and reconstruction (case 3).

Four emergency cases received VV-ECMO either for extensive traumatic tracheal/carinal injuries (n=2, cases 1 and 4), iatrogenic extensive tracheal laceration (n=1, case 5) and for iatrogenic left main bronchus laceration during endoscopic treatment of tracheal stenosis involving the proximal left main bronchus (n=1, case 6). Impaired lung function, which ruled out a one-lung ventilation strategy due to a previous pulmonary resection, was the indication for the use of VV-ECMO in two cases. In case 7, a resection of the left main bronchus was performed in a patient who had undergone an inferior bilobectomy 4 years earlier. In case 10, a left pneumonectomy had been performed 4 years earlier due to an extensive post-traumatic abscess in the left lung in a tetraparetic patient. He had developed tracheal stenosis associated with tracheomalacia after the tracheostomy, which was treated with multiple endoscopic laser treatments and dilatation, resulting in double tracheal stenosis.

Regarding the oncological pathology, we operated on

Table 1 Demographic data, indications, setting (elective/emergency), type of procedure, approach of the whole cohort

Case	Sex	Age (years)	Pathology	Comorbidity	Indication to ECMO	Location	Surgical approach	Surgical procedure
1	M	37	Carinal and both main bronchi laceration	–	Emergency (impossible ventilation)	Carina + main bronchi	PLT, right	Carinal repair
2	M	68	Carinal SCC	–	Complex reconstruction	Carina	PLT, right	Carinal resection and reconstruction (Eschapassee technique)
3	M	72	Right main bronchus/carinal SCC	–	Complex reconstruction	Right main bronchus/carina	PLT, right	Right upper double sleeve lobectomy and carinal resection and reconstruction
4	M	19	Tracheobronchial post-traumatic laceration	–	Emergency (respiratory failure)	Trachea/carina	Cervical incision	Tracheal repair
5	F	85	Iatrogenic tracheal laceration	Urgent tracheal intubation for respiratory failure	Emergency	Trachea	Cervico-sternotomy	Tracheal repair
6	F	31	Iatrogenic left main bronchus laceration	Tracheal stenosis	Emergency	Left main bronchus	PLT, left	Left main bronchus repair
7	M	71	Left main bronchus SCC	Previous inferior right lower bilobectomy	Previous lung extensive resection	Left main bronchus	PLT, left	Left main bronchus resection
8	M	78	Carinal chondrosarcoma	Previous tracheal resection and reconstruction	Complex resection and reconstruction	Carina	PLT, right	Carinal resection and reconstruction (Eschapassee technique)
9	M	54	Carinal IgG 4 disease	–	Complex reconstruction	Carina + both main bronchi	PLT, right	Carinal resection and reconstruction (Eschapassee technique)
10	M	55	Double site laryngo-tracheal stenosis post-tracheotomy	Tetraparesis incomplete and previous left pneumonectomy for abscess	Previous left pneumonectomy	Trachea	PLT, right	Tracheal resection and anastomosis

ECMO, extra-corporeal membrane oxygenation; M, male; PLT, postero-lateral thoracotomy; SCC, squamous cell carcinoma; F, female.

three patients for centrally located squamous cell carcinoma (cases 2, 3 and 7) and one patient for local recurrence of tracheal chondrosarcoma (case 8). One patient underwent carinal resection and reconstruction for IgG4-related disease (case 9).

Surgical procedures included: three carinal resections and reconstructions with complete pulmonary preservation according to the Eschapassee procedure (15) (*Figure 2*); one right upper double-sleeve lobectomy and hemi-carinal resection; one sleeve resection of the left main bronchus after previous right lower bilobectomy; four

tracheal/carinal repair for extensive traumatic laceration; n=1 extended tracheal resection for post-tracheostomy stenosis in a patient who had previously undergone a left pneumonectomy. In the cases performed by thoracotomy, the tracheobronchial tree was mobilized by releasing the hilum and pericardium (16).

The median intraoperative VV-ECMO time (*Table 2*) was 162.5 (IQR, 351) min and the median operative time was 178.5 (IQR, 235.5) min. In all three cases of complex resection and reconstruction of the carina with complete preservation of the parenchyma and in one case (case 10)

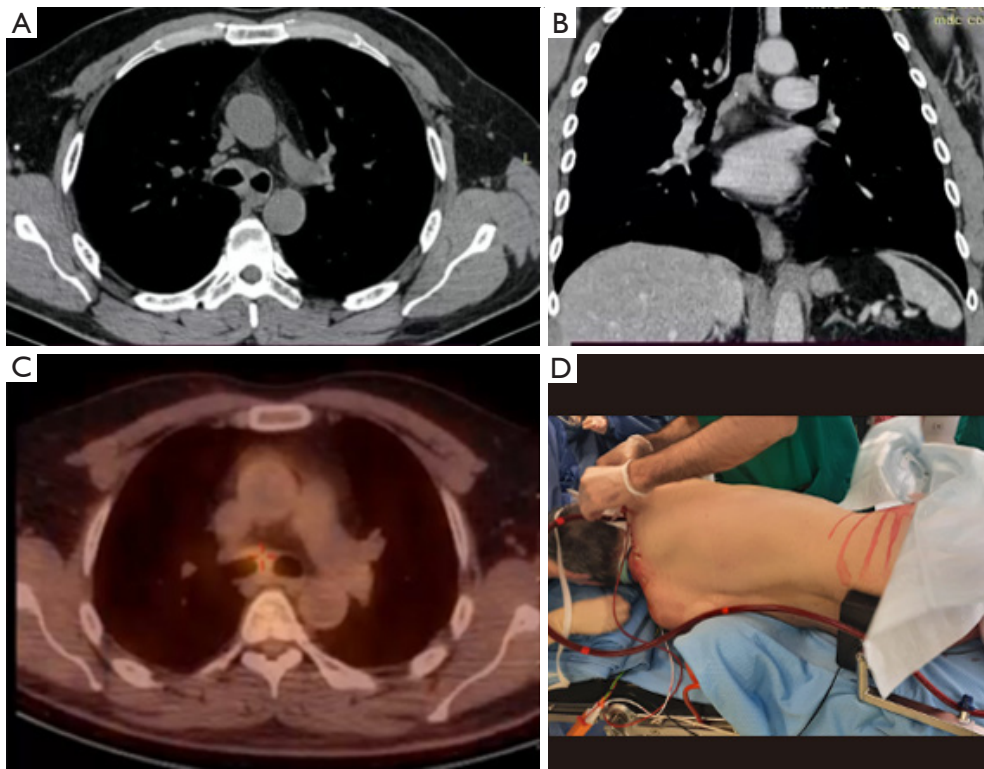


Figure 1 Pre-operative chest-CT scan (A,B), 18-fluorodeoxyglucose-positron emission tomography (C) and lateral decubitus position (D) after the insertion of VV-ECMO cannulae of the case 9. CT, computed tomography; VV-ECMO, veno-venous extra-corporeal membrane oxygenation.

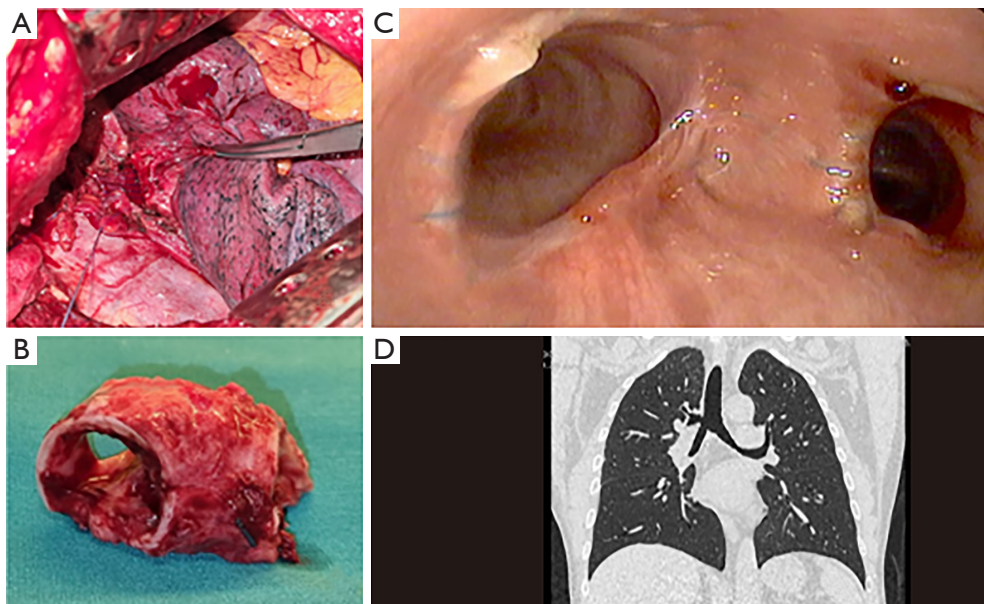


Figure 2 Some pictures of a carinal resection and reconstruction with complete parenchymal preservation (Eschaspasse procedure, case 9): (A) intraoperative left anastomosis; (B) anatomical specimen of the involved carina; (C) post-operative bronchoscopy showing the complete patency of the anastomosis and (D) post-operative chest-CT scan focusing on the reconstructed carina. CT, computed tomography.

Table 2 Site of cannulation, intra-operative and post-operative results

Case	Site of cannulation	ECMO duration (min)	Operative time (min)	Prolonged ECMO	ECMO flow rate	Outcomes	Complications
1	Femoro-Femoral (19–25 F)	96	118	No	3.96 L/min	Discharge 7 th post-op	None
2	Femoro-Jugular (19–25 F)	167	175	No	4.2 L/min	Discharge 10 th post-op	None
3	Femoro-Jugular (17–23 F)	105	182	No	3.85 L/min	Discharge 8 th post-op	AF
4	Femoro-Femoral (19–25 F)	420	385	Yes (17.16 h)	4.65 L/min	Discharge 12 nd post-op	None
5	Femoro-Femoral (19–25 F)	95	118	Yes (102 h)	4.08 L/min	Rehabilitation 45 th post-op	Long recover
6	Femoro-Femoral (19–25 F)	575	345	Yes (250 h)	3.9 L/min	Discharge 51 st post-op	Long recover
7	Femoro-Femoral (19–25 F)	108	120	No	4.51 L/min	Discharge 7 th post-op	None
8	Jugular-Femoral (19–25 F)	178	198	Yes (3 h)	4.2 L/min	Discharge 8 th post-op	None
9	Jugular-Femoral (19–25 F)	158	154	No	3.9 L/min	Discharge 7 th post-op	None
10	Jugular-Femoral (19–25 F)	555	435	No	4.2 L/min	Discharge 62 nd post-op	Tracheal dehiscence + Montgomery tube

ECMO, extra-corporeal membrane oxygenation; post-op, post-operative; AF, atrial fibrillation.

of extended post-tracheostomy stenosis and previous left pneumonectomy, high-flow VV-ECMO (approximately 4 L/min) achieved by Femoro-Jugular cannulation allowed interruption of ventilation for almost 3 hours, avoiding cross-field ventilation. Six patients were weaned from VV-ECMO at the end of surgery and extubated in the operating room. In the other four patients (cases 4, 5, 6 and 8), VV-ECMO was prolonged in the postoperative period to ensure safe and early extubation and to guarantee adequate gas exchange without mechanical ventilation, thus reducing the risk of dehiscence of a recent anastomosis (*Table 2*).

There were no perioperative deaths or reimplantation of VV-ECMO. There were no complications related to the use of ECMO and there was no intraoperative change in the planned type of ECMO. Postoperative complications occurred in two patients: one case developed atrial fibrillation that resolved with antiarrhythmic drugs, while the patient with the double long tracheal stenosis developed a small anastomotic dehiscence that healed with an abnormal proliferation of scar tissue, resulting in a tracheal stenosis that required placement of a Montgomery T-tube. Two emergency patients (cases 5 and 6) had a long stay in the intensive care unit (ICU) with a correspondingly long functional recovery due to the initial trauma and were discharged to rehabilitation facilities due to the initial trauma. However, no airway complications occurred in these patients.

The median hospital stay was 9 (IQR, 39.5) days and there were no postoperative readmissions in the first 90 postoperative days.

At a median follow-up of 30 months, all 10 patients were still alive with no evidence of neoplastic disease in oncological patients. Patient number 10 had a recurrence of the anastomotic stenosis and underwent several endoscopic dilatations with insertion of a Montgomery T tube and finally a permanent tracheostomy.

Discussion

Surgery of the main airways requires simultaneously optimal surgical exposure and safe and adequate maintenance of ventilation and oxygenation. The majority of main airway surgeries can be successfully performed with standard cross-field ventilation and periodic apneic phases, possibly in combination with so-called “apneic oxygenation” (7,9,17) or, more rarely, with the use of high-flow jet ventilation (HFJV) (18,19). However, there are situations in which the use ECLS support is almost mandatory to maintain a stable respiratory condition, and it could be beneficial in complex resections and reconstructions of the tracheal carina, where a clean surgical field is very useful to perform a perfect surgical technique with complete cardiorespiratory stability of the patient.

In the latter situation, the use of ECMO is controversial.

Some surgeons prefer to avoid its use as much as possible (4), while others maintain a low threshold for the use of ECMO, even in the case of right tracheal sleeve pneumonectomy (20), a procedure that can be easily performed with cross-field ventilation (9).

Our study has shown that VV-ECMO is a safe ventilation strategy with no post-operative mortality, a low incidence of overall complications and no ECMO-related adverse events. In three cases of carinal resection and reconstruction and one case of extended post-tracheostomy stenosis and prior left pneumonectomy, high-flow VV-ECMO achieved through a Femoro-Jugular cannula was highly effective, allowing apnoea for a median of three hours, avoiding cross-field ventilation and facilitating surgery with faster and more precise suture placement, as well as stable cardiorespiratory conditions.

In order to perform surgery without ventilation, a relatively high ECMO flow of about 4 L/min must be maintained. For this reason, we prefer double venous cannulation and especially the femoral-jugular setting is absolutely appropriate to avoid or minimize recirculation between inflow and outflow. Another significant advantage of ECMO, especially in this configuration, is the possibility of prolonging its use in the postoperative period, allowing the patient to be extubated immediately after the procedure and avoiding mechanical ventilation and the associated mechanical stress on the fresh suture line. In our experience, prolonged ECMO after surgery was required in four cases (cases 4, 5, 6 and 8).

These results are also possible thanks to a very active collaboration between thoracic surgeons, anesthesiologists and the institutional ECMO team, where all elective cases of complex main airway surgery were discussed in a multidisciplinary meeting.

Conventional CPB was the first tool used for intraoperative cardiorespiratory support and remains indispensable when the surgical procedure involves opening the cardiac cavities or during surgery of the aortic arch or the main trunk of the pulmonary artery (21-23). Apart from these cases, ECMO has replaced CPB as extracorporeal respiratory support during surgery due to its known advantages, including the need for less anticoagulation with a lower risk of intraoperative and postoperative bleeding and a lower systemic inflammatory response due to its greater biocompatibility.

The first application of intraoperative VV-ECMO in two cases of complex trachea-bronchial resections and reconstructions was described by Horita *et al.* in 1996 (24).

Subsequently, the Vienna group reported their more solid experience with 10 complex trachea-bronchial resections and reconstructions in patients with non-small cell lung cancer (NSCLC) using VA-ECMO (4), achieving excellent results with no postoperative mortality and an R0 resection of 89%. The multi-institutional French experience (10), which included all cases of thoracic surgery under ECMO except lung transplantation, reported a 30-day mortality of 7%, a high weaning rate (92.8%) and low complications and bleeding in the 28 patients operated under ECMO with total respiratory support in an elective setting (group 1).

VA-ECMO is advisable in heart failure or in cases where manipulation of the great vessels is expected, as in some cases of left carinal resection through sternotomy. For exclusively respiratory indications, such as carinal resection or traumatic interruption of the main airways, VV-ECMO should be preferred over VA-ECMO to avoid the risk of arterial injury or acute ischemia of the limb (in the case of peripheral cannulation); moreover, the potential consequences of air or clot embolization from the circuit are less severe. However, the literature describing complex or extended airway resections using VV-ECMO is limited to date due to the small number of cases (10,25,26).

In our recent institutional experience, the use of ECMO was deemed necessary in the case of a previous contralateral lung resection with impaired lung function, such that conventional one-lung ventilation was insufficient to ensure adequate gas exchange throughout the procedure.

In case 7, a previous right lower bilobectomy precluded a conventional ventilation strategy, as adequate gas exchange with ventilation of the remaining right upper lobe would have been insufficient. In case 10, a previous left pneumonectomy had resulted in a mediastinal shift, which prompted us to address the long and distal tracheal stenosis with a right thoracotomy. VV-ECMO was also strongly recommended in the three cases with extensive and distal airway injuries (cases 1, 4, 5), as it was difficult and risky to pass the orotracheal tube beyond the defect site. Indeed, in patients with extensive traumatic injury to the main airways, it might be impossible or unsafe to attempt to bridge the defect, leading to loss of airway and thus dangerous complications such as pneumomediastinum and tension pneumothorax. Furthermore, in the case of a distal tracheal injury, bridging would generally lead to unilateral intubation, which is often poorly tolerated by patients. From a technical point of view, suturing the posterior wall of the trachea without tubes and without the pressure of apnea ensures better surgical outcomes and clinical results

(15,20,23,26).

Finally, we used VV-ECMO support in four complex resections and reconstructions of the tracheal carina (cases 2, 3, 8 and 9) (15) that could have been performed with conventional cross-field or jet ventilation, but at the cost of greater technical difficulty in performing the procedure, especially in the second anastomosis and with longer operating time and repeated insertion of tubes into the airway. We believe that the use of ECMO has undeniable advantages in terms of optimal surgical exposure with a clean and tube-free surgical field, allowing complex major airway surgery to be performed accurately and safely in a setting of sufficient gas exchange throughout the entire procedure and also allowing protective ventilation of patients with chronically diseased lungs. We have not observed any cases of acute respiratory distress syndrome (ARDS), which is often the result of aggressive ventilation techniques that are necessarily used in cases where single lung ventilation cannot provide adequate gas exchange. We have also reported only one case of an airway anastomosis complication, a small dehiscence due to a large portion of the trachea resected with a subsequent tension anastomosis that healed with abnormal scar tissue and resulted in tracheal stenosis.

Regarding problems potentially related to the use of ECMO, we did not observe any complications related to the cannulae placement, including bleeding, wound infection at the cannulation site, and deep venous thrombosis or peripheral ischaemia. No cases required conversion from VV to VA ECMO or CPB and there was no hypoxic or embolic cerebral damages or deep vein thrombosis. Even surgical bleeding was not a problem thanks to the low anticoagulation (3,000–5,000 units of heparin) that ECMO requires thanks to its heparin-coated system. In fact, no patient required surgical revision for intra- or post-operative bleeding.

Our study has several limitations. First, this is a retrospective report from a single institution on a prospectively collected cohort of patients, which is undoubtedly small, precluding any statistical analysis, inference and comparison. The size of the cohort is directly related to the rarity of the diseases treated and also to the infrequent use of the ventilation strategy with ECMO. Second, our study population could be considered heterogeneous in terms of pathology, as we included airway trauma, tumours, fibroinflammatory diseases and stenosis.

Conclusions

Despite all these limitations, our experience leads us to conclude that the use of intraoperative VV-ECMO in patients requiring complex resections and reconstructions, and in cases that cannot be managed with conventional ventilation techniques, allows for safe and precise performance of main airway surgery with minimal postoperative morbidity.

We believe that VV-ECMO should be part of the surgical armamentarium of teams that frequently deal with complex resections and reconstructions of the main airway.

Acknowledgments

Funding: None.

Footnote

Reporting Checklist: The authors have completed the STROBE reporting checklist. Available at <https://jtd.amegroups.com/article/view/10.21037/jtd-23-1416/rc>

Data Sharing Statement: Available at <https://jtd.amegroups.com/article/view/10.21037/jtd-23-1416/dss>

Peer Review File: Available at <https://jtd.amegroups.com/article/view/10.21037/jtd-23-1416/prf>

Conflicts of Interest: All authors have completed the ICMJE uniform disclosure form (available at <https://jtd.amegroups.com/article/view/10.21037/jtd-23-1416/coif>). L.V. serves as an unpaid editorial board member of *Journal of Thoracic Disease* from October 2022 to September 2024. The other authors have no conflicts of interest to declare.

Ethical Statement: The authors are accountable for all aspects of the work in ensuring that questions related to the accuracy or integrity of any part of the work are appropriately investigated and resolved. This retrospective study was conducted in accordance with the Declaration of Helsinki (as revised in 2013). The retrospective analysis of the data did not require approval of the Institutional Review Board. Informed consent was obtained from each patient.

Open Access Statement: This is an Open Access article

distributed in accordance with the Creative Commons Attribution-NonCommercial-NoDerivs 4.0 International License (CC BY-NC-ND 4.0), which permits the non-commercial replication and distribution of the article with the strict proviso that no changes or edits are made and the original work is properly cited (including links to both the formal publication through the relevant DOI and the license). See: <https://creativecommons.org/licenses/by-nc-nd/4.0/>.

References

1. Broman LM, Taccone FS, Lorusso R, et al. The ELSO Maastricht Treaty for ECLS Nomenclature: abbreviations for cannulation configuration in extracorporeal life support - a position paper of the Extracorporeal Life Support Organization. *Crit Care* 2019;23:36.
2. Tonna JE, Abrams D, Brodie D, et al. Management of Adult Patients Supported with Venovenous Extracorporeal Membrane Oxygenation (VV ECMO): Guideline from the Extracorporeal Life Support Organization (ELSO). *ASAIO J* 2021;67:601-10.
3. Reeb J, Olland A, Massard G, et al. Extracorporeal life support in thoracic surgery. *Eur J Cardiothorac Surg* 2018;53:489-94.
4. Lang G, Ghanim B, Hötzenecker K, et al. Extracorporeal membrane oxygenation support for complex tracheo-bronchial procedures†. *Eur J Cardiothorac Surg* 2015;47:250-5; discussion 256.
5. Esper SA, Levy JH, Waters JH, et al. Extracorporeal membrane oxygenation in the adult: a review of anticoagulation monitoring and transfusion. *Anesth Analg* 2014;118:731-43.
6. McMichael ABV, Ryerson LM, Ratano D, et al. 2021 ELSO Adult and Pediatric Anticoagulation Guidelines. *ASAIO J* 2022;68:303-10.
7. Hoetzenecker K, Klepetko W, Keshavjee S, et al. Extracorporeal support in airway surgery. *J Thorac Dis* 2017;9:2108-17.
8. Abdelmalak BB, Doyle DJ. Recent trends in airway management. *F1000Res* 2020;9:F1000 Faculty Rev-355.
9. Weder W, Inci I. Carinal resection and sleeve pneumonectomy. *J Thorac Dis* 2016;8:S882-8.
10. Rinieri P, Peillon C, Bessou JP, et al. National review of use of extracorporeal membrane oxygenation as respiratory support in thoracic surgery excluding lung transplantation. *Eur J Cardiothorac Surg* 2015;47:87-94.
11. Beckmann A, Benk C, Beyersdorf F, et al. Position article for the use of extracorporeal life support in adult patients. *Eur J Cardiothorac Surg* 2011;40:676-80.
12. Cianchi G, Lazzeri C, Bonizzoli M, et al. The 8-Year Experience of the Florence Referral ECMO Center and Retrieval Team for Acute Respiratory Failure. *J Cardiothorac Vasc Anesth* 2018;32:1142-50.
13. Cianchi G, Lazzeri C, Bonizzoli M, et al. Activities of an ECMO Center for Severe Respiratory Failure: ECMO Retrieval and Beyond, A 4-Year Experience. *J Cardiothorac Vasc Anesth* 2019;33:3056-62.
14. Reiner JS, Coyne KS, Lundergan CF, et al. Bedside monitoring of heparin therapy: comparison of activated clotting time to activated partial thromboplastin time. *Cathet Cardiovasc Diagn* 1994;32:49-52.
15. Voltolini L, Salvicchi A, Cianchi G, et al. Extracorporeal membrane oxygenation support in carinal resection for recurrent chondrosarcoma after previous distal tracheal resection. *Interact Cardiovasc Thorac Surg* 2022;35:ivac148.
16. He J, Zhong Y, Suen HC, et al. The procedure and effectiveness of release maneuvers in tracheobronchial resection and reconstruction. *Transl Lung Cancer Res* 2022;11:1154-64.
17. Oliveira J E Silva L, Cabrera D, Barrionuevo P, et al. Effectiveness of Apneic Oxygenation During Intubation: A Systematic Review and Meta-Analysis. *Ann Emerg Med* 2017;70:483-494.e11.
18. Klain M, Smith RB. High frequency percutaneous transtracheal jet ventilation. *Crit Care Med* 1977;5:280-7.
19. Biro P. Jet ventilation for surgical interventions in the upper airway. *Anesthesiol Clin* 2010;28:397-409.
20. Mazzella A, Bertolaccini L, Petrella F, et al. Venovenous extra-corporeal membrane oxygenation-assisted right tracheal-sleeve pneumonectomy. *Interact Cardiovasc Thorac Surg* 2021;33:649-51.
21. Ulicny KS Jr, Schmelzer V, Flege JB Jr, et al. Concomitant cardiac and pulmonary operation: the role of cardiopulmonary bypass. *Ann Thorac Surg* 1992;54:289-95.
22. Wiebe K, Baraki H, Macchiarini P, et al. Extended pulmonary resections of advanced thoracic malignancies with support of cardiopulmonary bypass. *Eur J Cardiothorac Surg* 2006;29:571-7; discussion 577-8.
23. Park BJ, Bacchetta M, Bains MS, et al. Surgical management of thoracic malignancies invading the heart or great vessels. *Ann Thorac Surg* 2004;78:1024-30.
24. Horita K, Itoh T, Furukawa K, et al. Carinal reconstruction under venovenous bypass using a percutaneous cardiopulmonary bypass system. *Thorac*

- Cardiovasc Surg 1996;44:46-9.
25. Chen L, Wang Z, Zhao H, et al. Venovenous extracorporeal membrane oxygenation-assisted tracheobronchial surgery: a retrospective analysis and literature review. *J Thorac Dis* 2021;13:6390-8.
 26. Tombelli S, Viggiano D, Gatteschi L, et al. Video-assisted transcervical-transtracheal repair of posterior wall laceration of thoracic trachea: A new approach. *Case Report. Front Surg* 2023;10:1120404.

Cite this article as: Voltolini L, Salvicchi A, Gonfiotti A, Borgianni S, Cianchi G, Mugnaini G, Bongiolatti S. Venovenous extra-corporeal membrane oxygenation in complex tracheobronchial resection. *J Thorac Dis* 2024;16(2):1279-1288. doi: 10.21037/jtd-23-1416