Original Paper

Stereotact Funct Neurosurg 2002;79:202–213
DOI: 10.1159/000070833

Stereotactic and Functional Neurosurgery

Stereotactic Interstitial Radiosurgery with a Miniature X-Ray Device in the Minimally Invasive Treatment of Selected Tumors in the Thalamus and the Basal Ganglia

Pasquale Gallina[a] Paolo Francescon[e] Carlo Cavedon[e]
Franco Casamassima[b] Raffaello Mungai[c] Paolo Perrini[a]
Serenella Russo[d] Nicola Di Lorenzo[a]

[a]Department of Neurosurgery, [b]Clinical Radiobiological Unit, [c]Department of Radiation Oncology, [d]Department of Medical Physics, University of Florence, Florence, [e]Department of Medical Physics, S. Bortolo Hospital, Vicenza, Italy

Key Words

Basal ganglia · Brain tumors · Interstitial radiosurgery · Photon radiosurgery system · Minimally invasive therapy · Thalamus

Abstract

The aim of this study was to evaluate the role of interstitial radiosurgery (IR) using the photon radiosurgery system (PRS) in the treatment of selected tumors within the thalamus and the basal ganglia. The PRS is a miniature X-ray generator that was developed for interstitial irradiation. This series included 14 patients (5 with glioblastomas, 4 with low-grade astrocytomas and 5 with metastases) harboring spheroidal lesions with dimensions ranging from 13 to 42 mm (mean 30 mm). After stereotactic biopsy, a radiation dose ranging from 6 to 15.4 Gy (mean 11.3 Gy) was delivered at the target volume margins. Follow-up varied from 3 to 26 months (mean 10.2 months). In the group of glioblastomas, 3 patients died (3–12 months after

KARGER
Fax + 41 61 306 12 34
E-Mail karger@karger.ch
www.karger.com

1011–6125/02/0794–0202$18.50/0

Accessible online at:
www.karger.com/sfn

Pasquale Gallina, MD, Department of Neurosurgery
University of Florence, CTO Hospital
Largo P. Palagi 1, IT–50139 Florence (Italy)
Tel. +39 0554278225, Fax +39 0554278070
E-Mail pgal@unifi.it

the procedure) because of tumor progression, while the remaining had tumor control. Two patients with metastases died from systemic disease (4–9 months after the treatment), and 3 were alive and well at the end of the study. Local control was achieved in all metastases. Patients with low-grade astrocytomas were well and imaging studies showed tumor control PRS IR is a minimally invasive procedure for the treatment of selected glial or secondary brain tumors. Compared to conventional radiosurgery (brachytherapy and external radiosurgery), PRS IR presents dose delivery characteristics useful for the treatment of tumors in the thalamus and basal ganglia, without inconveniences such as handling radioisotopes, the need of expensive facilities and radiation protection measures. Although the clinical value needs further investigations, PRS IR seems to be effective in metastases while it provides less benefit in malignant gliomas. PRS IR could have a major role in the treatment of low-grade astrocytomas.

Introduction

The treatment of low-grade or anaplastic glial tumors and metastatic lesions in the thalamus and basal ganglia, being in the circumferential neighborhood of critical structures, represents a challenging issue in neurosurgery. For this reason, in recent years, stereotactic radiosurgery has expanded as a minimally invasive treatment modality for such deep brain tumors. Radiosurgical techniques based on the use of external beams require a preventive histological diagnosis, in addition to large and expensive facilities. On the other hand, interstitial irradiation with radioactive isotopes involves the inconvenience of having to handle radioactive sources.

Interstitial radiosurgery (IR) using the photon radiosurgery system (PRS; Photoelectron Corporation, Waltham, Mass., USA) has recently been employed for the treatment of brain tumors [1–3]. Compared to brachytherapy, PRS IR eliminates the inconveniences of isotopes and presents dosimetric advantages, such as adjustable dose rate and steeper dose gradient; moreover, this portable device, compared to external radiosurgical systems, represents a cost-effective way to deliver IR immediately after the tumor biopsy – which is the legal basis for treatment decision – without requesting particular radiation protection measures or dedicated facilities [4–6]. In our institution, since January 2000, we have introduced the use of PRS IR in the minimally invasive treatment of selected tumors (spheroidal, glial or metastatic lesions). It has represented an alternative to conventional neurosurgery treatment when the risk-benefit ratio due to tumor localization was unfavorable or when such an option was requested by the patient. It

ments were observed in the range of 0–2 mm). The radiation source is then mounted on a self-modified stereotactic arc. The probe is introduced through the hole of the biopsy and moved forward so that the effective point of X-ray emission reaches the target coordinates. The irradiation treatment is then started. Patients receive a single intravenous dose of 8 mg of dexamethasone immediately before the radiation dose is delivered.

Treatment Strategy and Irradiation Parameters

Because of the nearly spherical shape of the PRS dose distribution, the effective point of X-ray emission has to be positioned at the geometrical center of the lesion. This point coincided with the one selected for the biopsy in the case of low-grade astrocytomas and in three patients with metastases, whereas in patients with malignant gliomas and in the remaining patients with metastases, the histological sample was obtained at a more adequate point. In order to define the planning target volume, both the tumor extension and the proximity of critical structures must be taken into account. In the case of metastatic lesions and low-grade gliomas, the target volume coincided with the tumor itself plus a 1- to 2-mm margin, while in the case of anaplastic gliomas, a wider margin (up to 4 mm) was used due to the infiltrative nature. Nevertheless, dose constraints were necessarily assigned to critical structures in some cases, resulting in lower doses to the tumor margin than desired. The radiation dose at the margins of the target volume ranged between 6 and 15.4 Gy (mean 11.3 Gy). A relative biological effectiveness factor ranging from 1.2 (50 kV) to 1.5 (40 kV) was taken into account during the dose prescription process [8]. The employed beam current was 20 μA and the irradiation procedure took between 10 and 42 min (mean 33 min). The irradiation parameters for each treatment are reported in table 1.

Results

When no complications were observed, patients were discharged after 2 days with a prescription of steroids and anticonvulsants. Patients were scheduled for clinical checks and imaging studies with contrast-enhanced CT scan and/or MR imaging 1, 3, 6 and 12 months after the treatment and at 6-month intervals thereafter. Clinical evaluation was obtained through Karnofsky Performance Scale rating. All imaging studies were reviewed during a multidisciplinary meeting attended by neurosurgeons, radiation oncologists and neuroradiologists at scheduled controls. An image integration between preoperative and follow-up CT and/or MR imaging studies made it possible to compare the target volume with the corresponding volume on the control images. Reduction or stabilization of the tumor size was assessed as local control, whereas increase of the tumor size was considered a treatment failure.

No postoperative mortality was observed. The procedure was well tolerated in 10 patients. One patient who presented acute, severe neurological deterioration recovered after the positioning of a temporary external ventricular drainage. Two patients experienced transient mild neurological deterioration that resolved with steroids; 1 month after the treatment, another patient developed hydrocephalus

necessitating the positioning of a ventriculoperitoneal shunt and long-term application of steroids.

Follow-up ranged from 3 to 26 months (mean 10.2 months). In the group of glioblastoma, 3 patients died (between 3 and 12 months after the procedure) due to tumor progression. Two patients (follow-up 3–5 months) are well and imaging shows tumor control (fig. 1). In the group of metastases, 2 patients died because of systemic disease progression (4–9 months after PRS IR) and 3 are alive and in good condition (3–8 months after treatment). Local control of metastases was achieved in all cases (fig. 2). The 4 patients with low-grade astrocytomas (follow-up 15–23 months) are well and imaging studies show tumor control (fig. 3). The results are summarized in table 1.

Discussion

In noncritical areas, radical surgery alone, in the case of low-grade astrocytomas, and radical surgery followed by whole-brain radiotherapy, in the case of anaplastic glial and secondary tumors, are still the gold standard [9–19]. On the other hand, when such lesions involve the basal ganglia or the thalamus, the surgical treatment, in spite of using computer-assisted volumetric resection techniques, is still very challenging [20–23].

Stereotactic radiosurgery with external beams has proved to be highly effective in the case of metastases of adequate dimensions and is considered the option of choice for deep-seated lesions [24]. On the other hand, in the case of malignant gliomas, the role of radiosurgery seems to be less well defined. Even though some authors consider radiosurgery an important additional treatment in the management of malignant gliomas, significant benefits remain to be shown [25–28]. Interstitial irradiation using isotopes in the case of low-grade gliomas has been extensively used and is considered a specific and effective treatment for selected patients with deep-seated lesions for whom surgery does not provide a curative treatment [29, 30]. PRS has operational and dosimetric characteristics that combine the advantages of external beam radiosurgery (short treatment time) with the advantages of interstitial radiosurgery (intratumoral placement of the radiation source); further, it does not present the inconveniences of these two treatment modalities. The first study on PRS IR was reported by Cosgrove et al. [1] in 1997, and presented preliminary results concerning their initial validation experience. In a subsequent work, the same authors presented their results in a larger series of patients, confirming a high local control rate in selected tumors [2]. We introduced PRS IR as a therapeutic option in the context of a modulated program for the management of brain tumors. In our experience, PRS proved to be easy to handle and reliable, even if its use requires a relatively long learning phase. Radia-

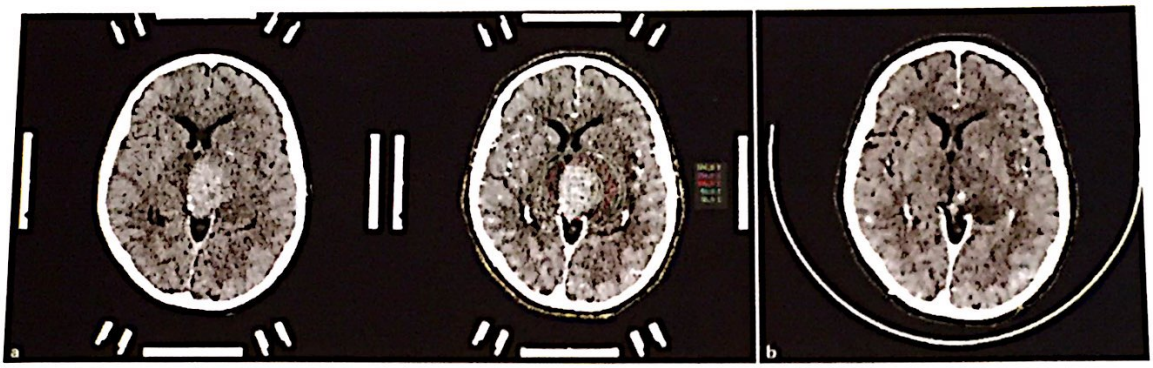

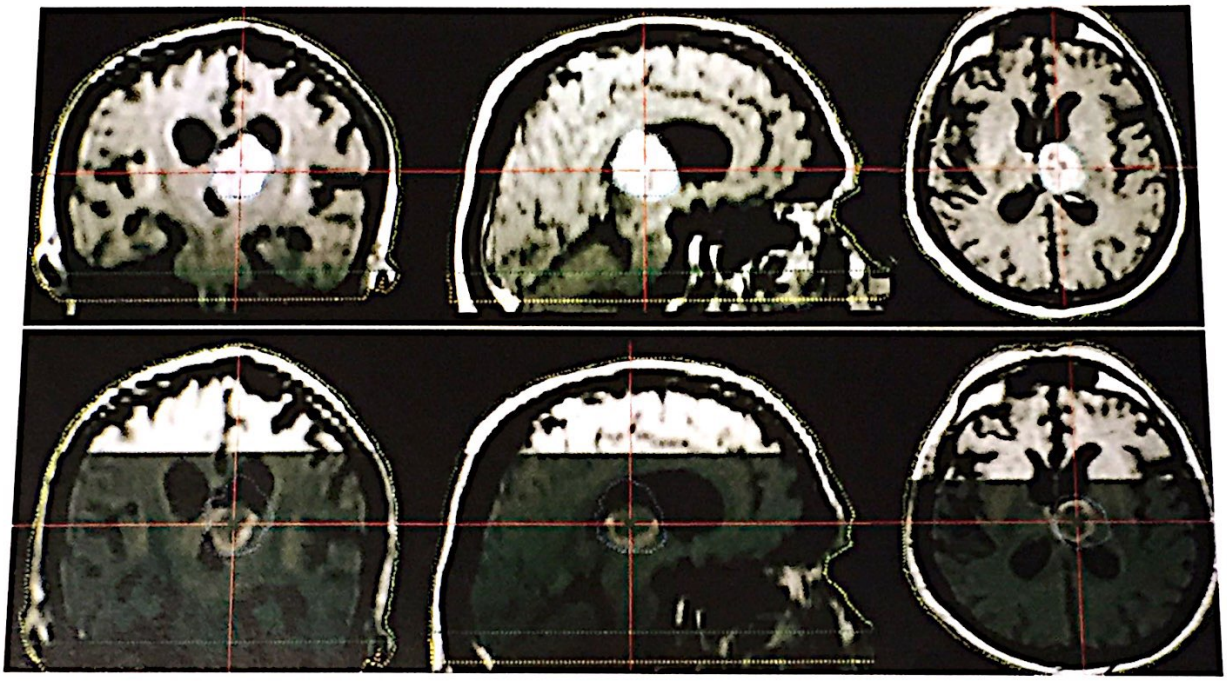

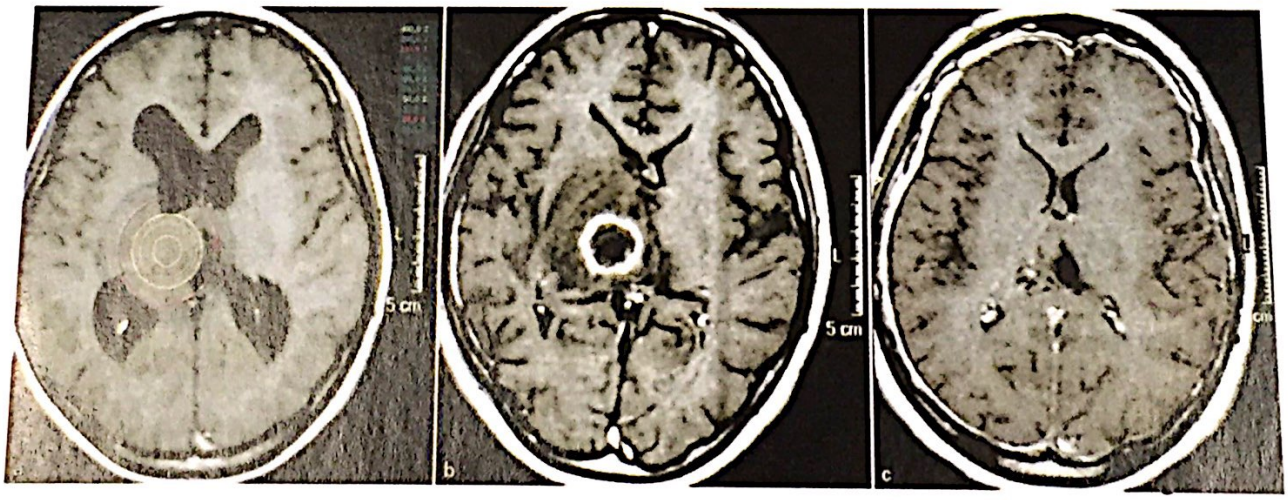

tion exposure level measurements in the environment during PRS IR have demonstrated that only minimal radiation protection measures are needed [3].

No experiments on PRS IR for lesions in the thalamus or in the basal ganglia have yet been reported in the literature. PRS has dose delivery characteristics that might be advantageous in the treatment of lesions for which the surgical approach is very delicate, being in the neighborhood of critical structures. The purpose of IR, either with isotopes or PRS, is to deliver a necrotizing dose of radiation accurately defined by means of image-guided stereotaxy. The dose delivered to the target tissue must have an extremely steep gradient, thus minimizing the dose on the surrounding tissue. In all our cases, the expected radiobiological effect was found as an expanding progressive central necrosis surrounded in some cases by a well-defined peripheral contrast-enhanced ring, as seen on MR imaging controls. The advantage of PRS IR compared to both isotopes and external radiosurgery is the steeper dose gradient, which can be varied via the accelerating potential. For example, at 10 mm from the source, it can be as high as 35% per mm, whereas

Fig. 1. Case 14. Left-sided thalamic glioblastoma. **a** Pre-PRS IR images. Unenhanced stereotactic CT (left) shows a hyperdense lesion which effaces the third ventricule. After contrast administration (right), an inhomogeneous enhancement is seen. Percentage isodose lines relative to the prescription point (3.85 Gy at 23 mm from the source) are shown. **b** Control CT, obtained 31 days after PRS IR, shows only a small nodule of contrast enhancement in the left thalamus with disappearance of the spontaneous lesion hyperdensity and of the mass effect.

Fig. 2. Case 9. Left-sided thalamic metastasis. Axial, coronal and sagittal T1-weighted, gadolinium contrast-enhanced MR images. Upper panel: pre-PRS IR images. The tumor has been contoured. Lower panel: MR images 4 months after PRS IR. The visualization is obtained by fusion of the posttreatment MR data (lower part of each image) over the pretreatment ones (upper part of each image). The pretreatment tumor contour is overdrawn. The images show the reduction of the tumor volume (from 13.4 to 4.9 cm^3) and loss of the central enhancement.

Fig. 3. Case 1. Right-sided thalamic low-grade astrocytoma on serial T1-weighted, gadolinium-enhanced axial MR imaging scans. **a** Pretreatment image showing a plan including the isocenter; isodoses lines are superimposed as the result of the treatment plan. Values are relative to the point of dose prescription (10 Gy at 10 mm). **b** One-month control after PRS IR shows the appearance of a spherical area of hypointensity, surrounded by a ring of enhancement and edema. Hydrocephalus necessitated the positioning of a ventriculoperitoneal shunt. **c** Eighteen months after PRS IR, imaging demonstrates the almost complete normalization of the anatomy of the area.

with linac radiosurgery, values of 15% per mm are generally achievable with a 20-mm-diameter circular collimator. Recent technology has provided micro-multileaf collimators to be coupled to linac accelerators, with which highly conformed isodose surfaces can be achieved; nevertheless, the dose gradient remains comparable with that obtained with circular collimators.

In this series, postoperative mortality was nil and the procedure proved to be well tolerated and safe, although not completely free from complications. In the absence of surgical incidents detected on postoperative CT scan, complications such as transient neurological deterioration can be attributed to an increase of edema. Such events are also reported with conventional radiosurgery. An additional traumatism in PRS IR might be caused by the repeated introduction of the instruments, i.e. biopsy instrument and radiation source probe. In fact, postoperative T1-weighted MR images show in some cases a thin striation of contrast enhancement that marks the probe path from the point of introduction to the target.

Because of the limited number of treated patients and the short follow-up, at the moment it is not possible to draw a firm conclusion about the clinical value of PRS IR; however, from our experience, the results seem to depend on tumor histology [3]. In malignant glial tumors, PRS IR allowed local control just for a limited span of time. MR imaging controls after the treatment presented characteristic patterns, i.e. a spherical well-delimited area of hypointensity (whose shape and dimensions were consistent with the treatment parameters) surrounded by a ring of enhancement. At 3–6 months of follow-up, a centrifugal tumor proliferation was observed departing from the periphery of the treated volume and corresponding to the deterioration of clinical condition. Pathological studies on postmortem specimens showed, in the region corresponding to the treated volume, a spherical area of coagulative necrosis involving both vascular net and parenchyma that was sharply demarcated at the periphery from the area of apparently undamaged viable tumor invading the surrounding tissue. Indeed, with respect to highly malignant lesions infiltrating the nervous tissue at a distance, PRS IR seems to present the same limits of other conventional radiosurgical treatments. However, the potentialities of PRS IR alone or associated with adjuvant whole-brain radiotherapy in the field of malignant glial tumors in the thalamus and basal ganglia have yet to be determined since this treatment seems to compare favorably with surgery, due to its minor morbidity. Stereotactic fractionated radiotherapy has a role in the treatment of malignant gliomas [31], but its positioning accuracy is poorer and its dose gradient is less steep compared to those of PRS [32].

Histologically, low-grade astrocytomas are lesions with little spread of tumor cells into the periphery. These characteristics correspond to a good target for interstitial irradiation. According to Kreth et al. [29], whose study involved 455 patients, interstitial irradiation with isotopes is a specific treatment modality for

selected patients with unifocal circumscribed low-grade gliomas with a diameter of less than 4 cm in any location. No experiences are reported in the literature regarding PRS IR for the treatment of low-grade gliomas. The dosimetric characteristics of the device allow us to obtain well-defined small volumes of tissue necrosis, with less dose to the normal tissue outside the target. These characteristics, added to the substantial advantage of avoiding all the associated problems related to handling radioactive sources, represent the potential of PRS IR in the management of low-grade astrocytomas not suitable for surgical excision.

Metastases are ideal targets for radiosurgical treatment because of their shape and their demarcation from the surrounding normal tissue. Our experience using PRS IR with metastases confirms the good results achieved by Cosgrove et al. [2]. In the case of single lesions of adequate dimensions in which a biopsy is needed, PRS IR presents the appeal of making a diagnosis and applying the therapy in one single session.

Conclusion

PRS IR is an innovative therapeutic modality in the context of a modulated program for the management of brain tumors. This minimally invasive procedure represents an alternative and cost-effective means for the treatment of glial and secondary tumors spheroidal in shape and of adequate dimensions that are not candidates for conventional neurosurgical treatment and that necessitate a histological diagnosis. PRS presents dose delivery characteristics that can be advantageous in the treatment of lesions localized in the thalamus or in the basal ganglia. While larger case series are necessary in order to assess the clinical efficacy of this treatment modality, PRS IR seems to provide a high local control rate in metastases, while in the case of malignant gliomas, it shows low benefit. Low-grade astrocytomas could represent ideal targets for PRS IR if our results are confirmed by longer follow-up.

Acknowledgments

The authors thank Mr. Gino Terrin for his valuable technical support, Simone Poggi, PhD for his contribution to imaging elaboration and Homère Mouchaty, MD, for assistance in translation and preparation of the manuscript.

References

1 Cosgrove GR, Hochberg FH, Zervas NT, Pardo FS, Valenzuela RF, Chapman P: Interstitial irradiation of brain tumors, using a miniature radiosurgery device: Initial experience. Neurosurgery 1997;40:518–525.

2 Cosgrove GR, Loeffler JS, Zervas NT: Stereotactic interstitial radiosurgery in the management of brain tumors; in Schmidek HH, Sweet WH (eds): Operative Neurosurgical Techniques: Indications, Methods, and Results. Philadelphia, Saunders, 2000, vol 1, pp 707–713.

3 Gallina P, Francescon P, Cavedon C, Casamassima F, Mungai R, Terrin G, Perrini P, Pallotta S, Capaccioli L, Di Lorenzo N: Stereotactic interstitial radiosurgey and intraoperative radiotherapy with a miniature x-ray device in the treatment of selected brain tumors: Preliminary results; in Kondziolka D (ed): Radiosurgery. Basel, Karger, 2002, vol 4, pp 167–178.

4 Beatty J, Biggs PJ, Gall K, Okunieff P, Pardo FS, Harte KJ, Dalterio MJ, Sliski AP: A new miniature x-ray device for interstitial radiosurgery: Dosimetry. Med Phys 1996;23:53–62.

5 Douglas RM, Beatty J, Gall K, Valenzuela RF, Biggs P, Okunieff P, Pardo FS: Dosimetric results from a feasibility study of a novel radiosurgical source for irradiation of intracranial metastases. Int J Radiat Oncol Biol Phys 1996;36:443–450.

6 Hakim R, Zervas NT, Hakim F, Butler WE, Beatty J, Yanch JC, Biggs PJ, Gall KP, Sliski AP: Initial characterization of the dosimetry and radiobiology of a device for administering interstitial stereotactic radiosurgery. Neurosurgery 1997;40:510–517.

7 Dinsmore M, Harte KJ, Sliski AP, Smith DO, Nomikos PM, Daltiero MJ, Boom AJ, Leonard WF, Oettinger PE, Yanch JC: A new miniature x-ray source for interstitial radiosurgery: Device description. Med Phys 1996;23:45–52.

8 Brenner DJ, Leu CS, Beatty JF, Shefer RE: Clinical relative biological effectiveness of low-energy x-rays emitted by miniature x-ray devices. Phys Med Biol 1999;44:323–333.

9 Janny P, Cure H, Mohr M, Heldt N, Kwiatkowski F, Lemaire JJ, Plagne R, Rozan R: Low grade supratentorial astrocytomas. Management and prognostic factors. Cancer 1994;73:1937–1945.

10 Lang FF, Sawaya R: Supratentorial cerebral metastases; in Kaye AH, Black PM (eds): Operative Neurosurgery. London, Churchill Livingstone, 2000, vol 1, pp 385–397.

11 Laws ER, Taylor WF, Clifton MB, Okazaki N: Neurosurgical management of low-grade astrocytoma of the cerebral hemispheres. J Neurosurg 1984;61:665–673.

12 McCormack BM, Miller DC, Budzilovich GN, Voorhees GJ, Ransohoff J: Treatment and survival of low-grade astrocytoma in adults – 1977–1988. Neurosurgery 1992;31:636–642.

13 Patchell RA, Tibbs PA, Walsh JW, Dempsey RJ, Maruyama Y, Kryscio RJ, Markesbery WR, Macdonald JS, Young B: A randomized trial of surgery in the treatment of single metastases to the brain. N Engl J Med 1990;322:494–500.

14 Philippon JH, Clemenceau SH, Fauchon FH: Supratentorial low grade astrocytomas in adults. Neurosurgery 1993;32:554–559.

15 Piepmeier J, Christopher S, Spencer D, Byrne T, Kim J, Knisel JP, Lacy J, Tsukerman L, Makuch R: Variations in the natural history and survival of patients with supratentorial low-grade astrocytomas. Neurosurgery 1996;38:872–878.

16 Salcman M: High grade cerebral hemisphere gliomas (adult); in Kaye AH, Black PM (eds): Operative Neurosurgery. London, Churchill Livingstone, 2000, vol 1, pp 317–332.

17 Schmidek HH: Surgical management of supratentorial hemispheric gliomas in adults; in Schmidek HH, Sweet WH (eds): Operative Neurosurgical Techniques: Indications, Methods, and Results. Philadelphia, Saunders, 2000, vol 1, pp 756–768.

18 Smalley SR, Laws ER Jr, O'Fallon JR, Shaw EG, Schray MF: Resection for solitary brain metastases; Role of adjuvant radiation therapy and prognostic variables in 229 patients. J Neurosurg 1992;77:531–540.

19 Soffietti R, Chio A, Giordana MT, Vasario E, Schiffer D: Prognostic factors in well-differentiated cerebral astrocytomas in the adult. Neurosurgery 1989;24:686–692.

20 Drake JM, Joy M, Goldenberg A, Kreindler D: Computer- and robot-assisted resection of thalamic astrocytomas in children. Neurosurgery 1991;29:27–33.

21 Kelly PJ: Volumetric stereotactic tumor surgery; in Gildenberg PL, Tasker RR (eds): Textbook of Stereotactic and Functional Neurosurgery. New York, McGraw-Hill, 1998, pp 509–522.
22 Krouwer HG, Prados MD: Infiltrative astrocytomas of the thalamus. J Neurosurg 1995;82:548–557.
23 Lyons MK, Kelly PJ: Computer-assisted stereotactic biopsy and volumetric resection of thalamic pilocytic astrocytomas. Report of 23 cases. Stereotact Funct Neurosurg 1992;59:100–104.
24 Alexander E III, Loeffler JS: Radiosurgery for metastases; in Kaye AH, Black PM (eds): Operative Neurosurgery. London, Churchill Livingstone, 2000, vol 1, pp 407–415.
25 Alexander E III, Loeffler JS: Clinical experience with linac radiosurgery; in Gildenberg PL, Tasker RR (eds): Textbook of Stereotactic and Functional Neurosurgery. New York, McGraw-Hill, 1998, pp 745–756.
26 Friedman WA, Bova FJ, Buatti JM: Linac stereotactic radiosurgery: Clinical experience at the University of Florida; in Gildenberg PL, Tasker RR (eds): Textbook of Stereotactic and Functional Neurosurgery. New York, McGraw-Hill, 1998, pp 733–744.
27 Lunsford LD, Kondziolka D, Flickinger JC: Deep brain surgery using the gamma knife; in Gildenberg PL, Tasker RR (eds): Textbook of Stereotactic and Functional Neurosurgery. New York, McGraw-Hill, 1998, pp 805–816.
28 Steiner L, Prasad D, Lindquist C, Steiner M: Clinical aspects of gamma knife stereotactic radiosurgery; in Gildenberg PL, Tasker RR (eds): Textbook of Stereotactic and Functional Neurosurgery. New York, McGraw-Hill, 1998, pp 763–803.
29 Kreth FW, Faist M, Warnke PC, Rossner R, Volk B, Ostertag CB: Interstitial radiosurgery of low-grade gliomas. J Neurosurg 1995;82:418–429.
30 Ostertag CB: Interstitial radiosurgery of brain tumors; in Gildenberg PL, Tasker RR (eds): Textbook of Stereotactic and Functional Neurosurgery. New York, McGraw-Hill, 1998, pp 589–598.
31 Brada M, Baumert B: Focal fractionated conformal stereotactic boost following conventional radiotherapy of high-grade gliomas: A randomized phase III study: A joint study of the EORTC (22972) and the MRC (BR10). Front Radiat Ther Oncol 1999;33:241–243.
32 Rosenberg I, Alheit H, Beardmore C, Lee KS, Warrington AP, Brada M: Patient position reproducibility in fractionated stereotactic radiotherapy: An update after changing dental impression material. Radiother Oncol 1999;50:239–240.