



UNIVERSITÀ  
DEGLI STUDI  
FIRENZE

## FLORE

# Repository istituzionale dell'Università degli Studi di Firenze

### **Spindle cell liposarcoma of the face: case report and literature review.**

Questa è la Versione finale referata (Post print/Accepted manuscript) della seguente pubblicazione:

*Original Citation:*

Spindle cell liposarcoma of the face: case report and literature review / Agostini T; Catelani C; Acocella A; Franchi A; Bertolai R; Sacco R; Lazzeri D; Shokrollahi K.. - In: BRITISH JOURNAL OF DERMATOLOGY. - ISSN 0007-0963. - STAMPA. - 163:(2010), pp. 638-640.

*Availability:*

The webpage <https://hdl.handle.net/2158/471660> of the repository was last updated on

*Terms of use:*

Open Access

La pubblicazione è resa disponibile sotto le norme e i termini della licenza di deposito, secondo quanto stabilito dalla Policy per l'accesso aperto dell'Università degli Studi di Firenze (<https://www.sba.unifi.it/upload/policy-oa-2016-1.pdf>)

*Publisher copyright claim:*

La data sopra indicata si riferisce all'ultimo aggiornamento della scheda del Repository FloRe - The above-mentioned date refers to the last update of the record in the Institutional Repository FloRe

(Article begins on next page)

# Spindle cell liposarcoma of the face: case report and literature review

T. Agostini, C. Catelani,\* A. Acocella,\* A. Franchi,† R. Bertolai,\* R. Sacco,\* D. Lazzeri and K. Shokrollahi‡

AOUP Burn Center and Plastic Surgery Unit, Via Paradisa 2, Ospedale Cisanello, 56100 Pisa, Italy

\*SOD of Maxillo-Facial Surgery, University of Florence, CTO-AOUC, Largo Palagi 1, 50100 Florence, Italy

†Department of Human Pathology and Oncology, University of Florence, Viale Morgagni 85, 50134 Florence, Italy

‡Department of Plastic Surgery, The Ottawa Hospital, Ottawa, ON, Canada

## Summary

### Correspondence

Tommaso Agostini.

E-mail: [tommasoagostini@ymail.com](mailto:tommasoagostini@ymail.com)

### Accepted for publication

17 April 2010

### Key words

head and neck, liposarcoma, sarcoma, soft tissue tumour, spindle cell liposarcoma

### Conflicts of interest

None declared.

DOI 10.1111/j.1365-2133.2010.09847.x

Liposarcoma is a common soft tissue sarcoma accounting for approximately 20% of all mesenchymal tumours across all ages. Recently, collaborative research in the specialties of pathology and genetics has led to the delineation of several tumour variants with different behaviours and prognoses, one of which includes the very rare spindle cell liposarcoma (SCL) subtype. We present the first case of an SCL arising in the subcutaneous tissue of the forehead of a 78-year-old man. In light of the rarity of this tumour, we describe the tumour and its clinical and pathological characteristics and undertake a literature review to clarify the surgical management and prognosis of SCL, and increase awareness to avoid misdiagnosis of a benign soft tissue neoplasm.

According to the World Health Organization classification scheme in use since 1994, liposarcomas can be classified into three groups: (i) well-differentiated (including sclerosing, adipocytic, inflammatory, spindle cell and dedifferentiated variants) subtypes, (ii) myxoid/round cell liposarcoma and (iii) pleomorphic liposarcoma.<sup>1,2</sup>

Well-differentiated liposarcoma represents almost half of all liposarcomas with a tendency to develop both in the retroperitoneum and in the limbs. The spindle cell variant was first described in 1994 as a subtype of well-differentiated liposarcoma characterized by subcutaneous tissue involvement with an anatomical distribution comparable with the other subtypes.<sup>1</sup>

## Case report

We report a case of a white 78-year-old man (nonsmoker), who was referred to our unit because of a left frontoparietal lesion following a fall 3 months earlier. Clinical examination revealed a well-circumscribed, painless, firm lesion with undamaged overlying skin and no regional lymphadenopathy.

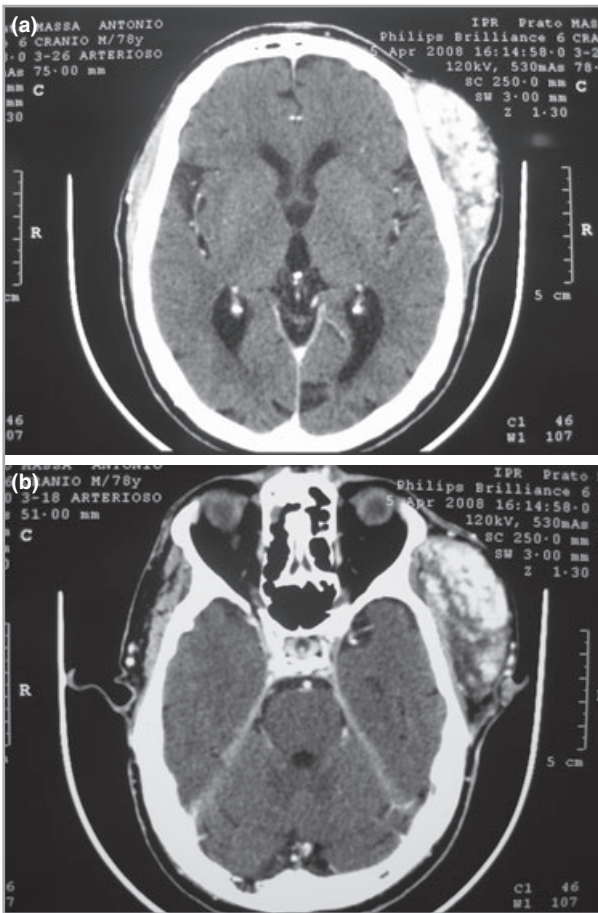
Ultrasound showed an ovoid mass (6 × 2 cm) with solid, nonhomogeneous content and with clear cleavage from the underlying tissues; Doppler imaging detected small vessels surrounded by a previous organizing haematoma. Computed tomographic scan confirmed an ovoid mass (7 × 3 cm) just

above the squamous temporal bone with nonhomogeneous enhancement with intravenous contrast (Fig. 1). The clinical examination and radiological reports suggested that the lesion was probably a vascular anomaly.

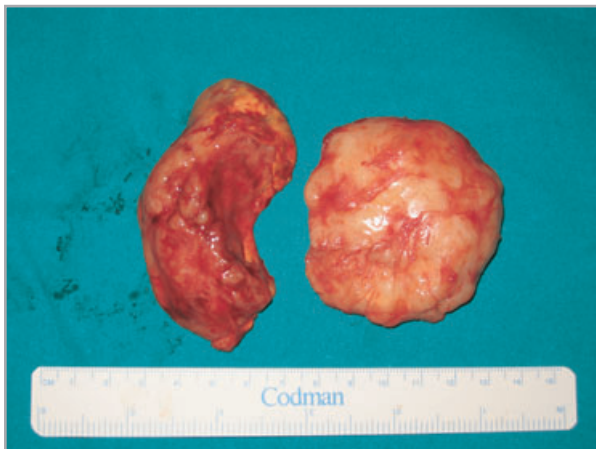The mass was enucleated through an overlying incision and a well-defined cleavage plane was observed. Macroscopically, the lesion presented as two compact yellow masses, with irregular surface and borders (Fig. 2). Histologically the tumour had a multinodular appearance, and it consisted predominantly of a proliferation of spindle cells arranged in fascicles or in whorls, with scarce intervening matrix, that focally exhibited a myxoid appearance (Fig. 3). On these bases a histopathological diagnosis of spindle cell liposarcoma (SCL) was made. Distant and local metastatic disease was excluded. Radiotherapy followed in a standard protocol with fractionated doses of 50 Gy 5 days a week for 1 month. After 21 months the patient is free from disease.

## Discussion

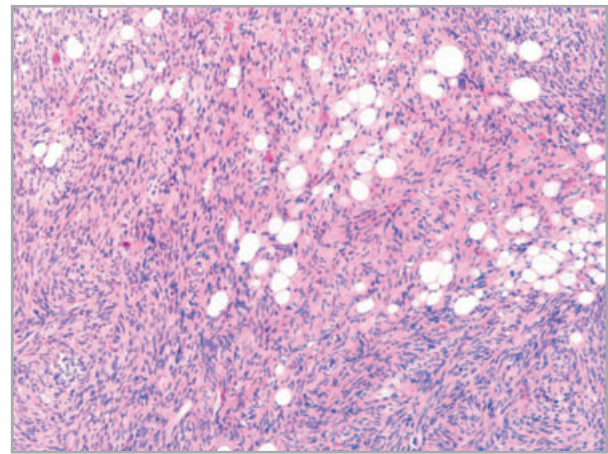
Nineteen previous cases of SCL were identified. The mean age was 37.1 years (range 11–83) (age was unavailable in seven cases). This rare subtype showed predilection for upper limbs (seven cases),<sup>1–5</sup> lower limbs (five cases)<sup>6,7</sup> and orbit (three cases),<sup>8,9</sup> one of which was a metastasis.<sup>8</sup> Neck,<sup>10</sup> vulva,<sup>7</sup> chest<sup>7</sup> and lung<sup>3</sup> accounted for only one case each. To our



**Fig 1.** (a, b) Computed tomographic scans showing a 7 × 3 cm mass above the squamous temporal bone with nonhomogeneous enhancement after contrast medium injection. The lesion extended inferiorly to the infratemporal fossa and superiorly to the parietal bone. Although the osseous outer table was uninjured, flattening of the ipsilateral curvature can be seen. The overlying skin was undamaged.



**Fig 2.** The mass was easily excised thanks to a well-defined cleavage plane. Macroscopically, it presented as a two yellow compact masses.



**Fig 3.** Histologically, the tumour has a multinodular appearance consisting of a proliferation of spindle cells arranged in fascicles. The cytoplasm is pale and eosinophilic, and the nucleus is oval. Mild to moderate nuclear atypia is present. A second component consists of mature adipocytic cells with marked variation in size, and scattered multivacuolated lipoblasts which are irregularly intermixed with the spindle cell component (haematoxylin and eosin).

knowledge SCL described in this paper appears to be the first case involving the face arising in a site other than the orbit.

Mortality seems to be low: three patients died of the disease within 4 years from primary diagnosis, two patients died of unrelated illness and one patient is still alive with unresectable metastasis. In four cases, the SCL recurred locally, whereas in two further cases distant metastasis developed. Tumour size and duration of the disease did not appear to be correlated well with prognosis.

The benefit of radiation and chemotherapy remains unproven from the collected data. In 13 cases treatment was not available, in two cases radiotherapy was associated with surgical resection and in one case palliative radiotherapy and chemotherapy were considered for a metastatic SCL to the orbit. It seems to be a minimally aggressive tumour either locally (it recurred in four cases) or distantly (two cases were distant metastases). Although three patients died of the disease, follow-up with a mean period of 54.8 months revealed a good survival rate after surgical resection as five patients were still alive with no evidence of disease. Two patients died of unrelated illness and the remaining cases were without follow-up data.

Among liposarcomas the spindle cell variant is one of the rarest as fewer than 20 cases are reported in the current medical literature. Although histological, clinical and molecular features are still poorly understood, its cytogenetics are well established, consisting of the presence of supernumerary ring or giant chromosomes containing amplified material from chromosome 12q14–q15 which includes the *MDM2* and *CDK4* genes. Recently a loss of genomic material from chromosome 7 without supernumerary chromosomes containing 12q amplified sequences or duplication of the 12q region has been demonstrated to be another molecular cytogenetic character-

ization.<sup>3</sup> SCL microscopically shows spindle cell proliferation arranged in fascicles and whorls set in a variable myxoid and/or fibrous stroma associated with an atypical adipocytic component often including lipoblasts.

Clinically liposarcoma can easily be misdiagnosed. It presents as a painless, slowly enlarging mass, becoming symptomatic when impinging upon surrounding structures; its indolent course can result in a misdiagnosis of cyst or benign soft tissue neoplasm, especially lipoma. These observations are confirmed by the present case report: SCL can simulate a variety of lesions, from haematoma to lipoma. Incisional biopsy is not indicated in large adipose tumours as malignant degeneration is usually at the centre of the mass, and false negatives can arise leading to inappropriate treatment.

Differential diagnosis includes diffuse neurofibroma, dermatofibrosarcoma protuberans, low-grade malignant peripheral nerve sheath tumour, low-grade sarcoma, spindle cell lipoma, sclerosing liposarcoma and low-grade myxofibrosarcoma.

Surgical removal remains the treatment of choice. Recurrence rate increases from 17% to 80% with incomplete excision.<sup>1,2</sup> Although grossly liposarcoma is encapsulated, it extends by infiltration. Prophylactic lymphadenectomy is not indicated unless there is evidence of metastasis, as the likelihood of nodal metastases is extremely low. Prognosis is influenced by histological variant, adequacy of surgical excision, and location of the tumour, whereas the role of tumour size remains unclear due to contrasting evidence.<sup>1-3</sup> Liposarcomas are radiosensitive, but this treatment does not produce cure and as a consequence radiotherapy is complementary to surgical treatment. The combination of radiotherapy and chemotherapy is used either for recurrences or for incompletely resected tumours. The role of chemotherapy alone is poor. The 5-year survival is above 80% for well-differentiated tumours and it reduces to 50% for round cell and pleomorphic variants. Even with complete removal, a proportion will recur.

### What's already known about this topic?

- A century and a half after Virchow originally described liposarcoma, several subtypes have been classified.
- We still have relatively poor knowledge of this disease and several unknowns remain in relation to prognosis and treatment despite the advent of cytogenetic and molecular investigations, and increased understanding and classification of lipomatous neoplasms.

### What does this study add?

- Our review of the literature and illustrative case report provide an update as to the current state of play in relation to the spindle cell variant, investigations, prognosis and treatment.
- In this paper are collected all the spindle cell liposarcomas (SCLs) available from a detailed literature review.
- The case report of SCL arising in the soft tissue of the face is the first described in the medical literature, to our knowledge.

### References

- 1 Dei Tos AP. Liposarcoma: new entities and evolving concepts. *Ann Diagn Pathol* 2000; **4**:252–66.
- 2 Dei Tos AP, Mentzel T, Fletcher CD. Primary liposarcoma of the skin: a rare neoplasm with unusual high grade features. *Am J Dermatopathol* 1998; **20**:332–8.
- 3 Italiano A, Chambonniere ML, Attias R *et al.* Monosomy 7 and absence of 12q amplification in two cases of spindle cell liposarcomas. *Cancer Genet Cytogenet* 2008; **184**:99–104.
- 4 Kindblom LG, Angervall L, Svendsen P. Liposarcoma a clinicopathologic, radiographic and prognostic study. *Acta Pathol Microbiol Scand Suppl* 1975; **253**:1–71.
- 5 Meis-Kindblom JM, Sjögren H, Kindblom LG *et al.* Cytogenetic and molecular genetic analyses of liposarcoma and its soft tissue simulators: recognition of new variants and differential diagnosis. *Virchows Arch* 2001; **439**:141–51.
- 6 Rajasekhar C, Paul AS, Bale RS. Spindle-cell liposarcoma: a rare variant of liposarcoma arising in the foot. *Clin Oncol (R Coll Radiol)* 2005; **17**:128–9.
- 7 Alaggio R, Coffin CM, Weiss SW *et al.* Liposarcomas in young patients: a study of 82 cases occurring in patients younger than 22 years of age. *Am J Surg Pathol* 2009; **33**:645–58.
- 8 Mentzel T, Toennissen J, Rütten A, Schaller J. Palmar atypical lipomatous tumour with spindle cell features (well-differentiated spindle cell liposarcoma): a rare neoplasm arising in an unusual anatomical location. *Virchows Arch* 2005; **446**:300–4.
- 9 Tehrani AH, Heegaard S, Prause JU *et al.* Liposarcoma metastatic to the orbit. *Eur J Ophthalmol* 2003; **13**:108–12.
- 10 Cai YC, McMenamin ME, Rose G *et al.* Primary liposarcoma of the orbit: a clinicopathologic study of seven cases. *Ann Diagn Pathol* 2001; **5**:255–66.