



UNIVERSITÀ
DEGLI STUDI
FIRENZE

FLORE

Repository istituzionale dell'Università degli Studi di Firenze

Efficacy of treatment with oral alitretinoin in patient suffering from lichen simplex chronicus and severe atopic dermatitis of hands

Questa è la Versione finale referata (Post print/Accepted manuscript) della seguente pubblicazione:

Original Citation:

Efficacy of treatment with oral alitretinoin in patient suffering from lichen simplex chronicus and severe atopic dermatitis of hands / Angelo Massimiliano D'Erme;Nicola Milanesi;Arianna Fay Agnoletti;Vincenza Maio;Daniela Massi;Massimo Gola. - In: DERMATOLOGIC THERAPY. - ISSN 1396-0296. - STAMPA. - 27(2014), pp. 21-23. [10.1111/dth.12035]

Availability:

This version is available at: 2158/841695 since:

Published version:

DOI: 10.1111/dth.12035

Terms of use:

Open Access

La pubblicazione è resa disponibile sotto le norme e i termini della licenza di deposito, secondo quanto stabilito dalla Policy per l'accesso aperto dell'Università degli Studi di Firenze (<https://www.sba.unifi.it/upload/policy-oa-2016-1.pdf>)

Publisher copyright claim:

(Article begins on next page)

THERAPEUTIC HOTLINE

Efficacy of treatment with oral alitretinoin in patient suffering from lichen simplex chronicus and severe atopic dermatitis of hands

ANGELO MASSIMILIANO D'ERME*, NICOLA MILANESI*,
ARIANNA FAY AGNOLETTI†, VINCENZA MAIO‡, DANIELA MASSI‡ &
MASSIMO GOLA*

**Allergological and Occupational Dermatology Unit, Department of Surgery and Translational Medicine, University of Florence, Florence, †DISSAL Section of Dermatology San Martino-IRCCS, Genoa, and ‡Division of Pathological Anatomy, Department of Critical Care Medicine and Surgery, University of Florence, Florence, Italy*

ABSTRACT: Lichen simplex chronicus (LSC) is a skin disorder characterized by chronic itching and scratching, which can lead to thick, leathery, brownish skin, sometimes with papules and can be associated with atopic eczema. We report the case of a 52-year-old man with a 45-year atopic condition and presenting LSC in his dorsum. After a 3-month treatment with alitretinoin at the daily dosage of 30 mg, we have observed a moderate improvement of the hand eczema together with a substantial clinical improvement of LSC and an almost complete resolution of pruritus. We want to report this peculiar case to suggest the use of oral alitretinoin for LSC.

KEYWORDS: alitretinoin, atopic dermatitis, lichen simplex chronicus

Address correspondence and reprint requests to: Angelo Massimiliano D'Erme, MD, Allergological and Occupational Dermatology Unit, Department of Surgery and Translational Medicine, University of Florence, Piazza dell'Indipendenza 11, 50129 Florence, Italy, or email: a.m.derme@gmail.com.

Learning Points: Alitretinoin can represent an effective drug for the treatment of lichen simplex chronicus and atopic dermatitis of hands.

The authors declare no affiliation or significant financial involvement in any organization or entity with a direct financial interest in the subject matter or materials discussed in the following manuscript.

Introduction

Lichen simplex chronicus (LSC) is a skin disorder characterized by chronic itching and scratching, which can lead to thick, leathery, brownish skin, sometimes with papules and can be associated with atopic eczema. Standard therapeutic options include topical corticosteroids, calcineurin inhibitors, phototherapy, retinoids, psychopharmacological agents, systemic corticosteroids, and other immunomodulatory agents

such as cyclosporin A and combinations thereof (1).

Alitretinoin (9-*cis*-retinoic acid) is a novel endogenously occurring vitamin A derivative, which binds both retinoic acid receptors and retinoid X receptors. It has recently been licensed in Italy for oral treatment of severe chronic hand eczema (CHE) unresponsive to potent topical corticosteroids (2,3).

In the literature, only one case has been described reporting the efficacy of alitretinoin in extrapalmar atopic eczema (4). The authors reported the successful oral alitretinoin treatment of six patients suffering from diffuse atopic eczema associated with atopic CHE lesions, whereas no reports are available regarding its potential use in atopic eczema.

Report

We report the case of a 52-year-old man with a 45-year history of atopy and atopic eczema.

At the first medical examination, he presented with chronic and severe hand eczema and erythematous and scratched nonconfluent papules involving the dorsum (between shoulders and the neck area) (FIG. 1A). He referred severe pruritus.

These lesions had been present for more than a year and had become permanent. The previous year, the patient had carried out a cycle of 12 narrowband UVB sessions, which he had to stop because he did not tolerate the treatment. Moreover, he resulted unresponsive to potent topical corticosteroids both on hands and on the dorsum.

During the first visit, the patient underwent allergological examination and cutaneous biopsy of a lesion on the dorsum.

The skin prick test with common allergens revealed positive atopy markers to pollen and *dermatophagoides pteronyssinus*. Patch tests were carried out according to International Contact Dermatitis Research Group (ICDRG) recommendations with standard and additional allergens. At Day 4, the patient showed no reaction to the allergens of standard SIDAPA (Italian Society of Allergological, Occupational and Environmental Dermatology) series.

Histopathological examination showed a spongiotic dermatitis associated to a sparse superficial dermal inflammatory infiltrate with lymphocytes, rare eosinophils, and melanophages (FIG. 1B).

These findings led to the diagnosis of LSC of the dorsum in patient suffering from atopic dermatitis of the hands.

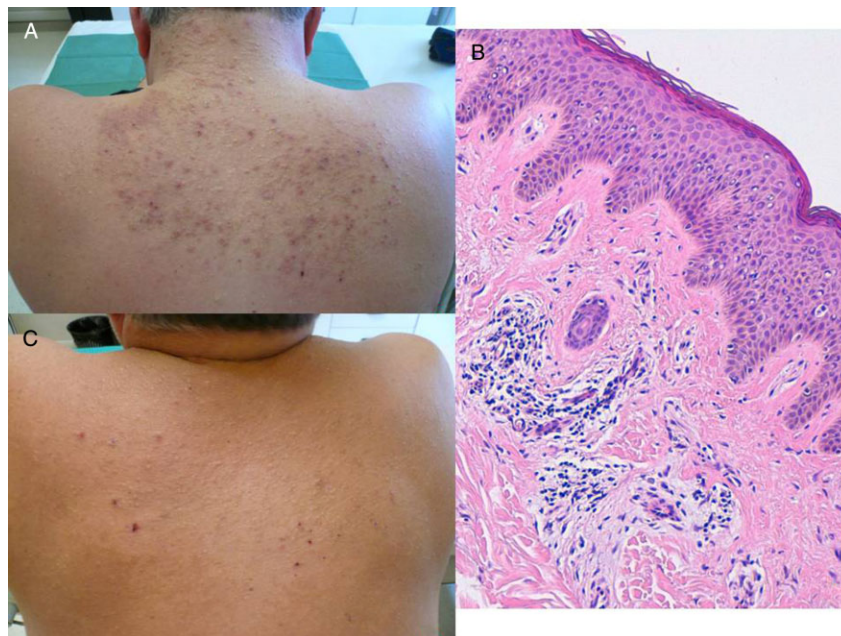


FIG. 1. (A) Chronic and severe hand eczema with erythematous and scratched nonconfluent papules on the dorsum. (B) Hyperorthokeratosis, parakeratosis, acanthosis, spongiosis, and a dermal lymphohistiocytic infiltrate with some eosinophils and melanophages (EE \times 20). (C) Substantial clinical improvement of lichen simplex chronicus after 3 months of therapy with oral alitretinoin. Resolution of papules and erythema of the dorsum.

The patient was treated for CHE with oral alitretinoin at the daily dosage of 30 mg for 12 weeks and with emollients as a basic topical therapy.

After 3 months of treatment, a moderate improvement of the hand eczema was observed together with a substantial clinical improvement of LSC (FIG. 1C). After 4 months from the end of treatment, no recurrence of lesions has been observed.

The clinical improvement was followed by an almost complete resolution of pruritus. In fact, the patients' visual analogue scales (VAS) itch decreased from 80 at the baseline to 10 at the end of the treatment. The therapy was generally well tolerated; no cutaneous or systemic side effects were observed.

Discussion

No studies or cases have been published so far regarding the potential benefits of this drug in LSC.

Alitretinoin is the only retinoid that activates both intracellular retinoid acid receptors, retinoic acid receptors and retinoid X receptors. It is known to have immunomodulating and anti-inflammatory effects and a regulating action on the keratinocyte cytokine production and leukocyte activity. In our patient, the clinical improvement

was paralleled by a marked reduction of pruritus, rubbing, and scratching, which had a positive impact on quality of life and contributed to skin lesion improvement.

Our case suggests that oral alitretinoin may constitute a novel, effective, and well-tolerated treatment option for exacerbated LSC refractory to standard topical treatments.

In conclusion, our case, together with the six cases described by Grahovac et al. (4), suggests a potential benefit of oral alitretinoin treatment of LSC as a manifestation of extrapalmar atopic eczema.

However, further analysis with longer follow-ups and randomized controlled trials are needed to confirm our clinical observation.

References

1. Lotti T, Buggiani G, Prignano F. Prurigo nodularis and lichen simplex chronicus. *Dermatol Ther* 2008; **21** (1): 42–46.
2. Ruzicka T, Lynde CW, Jemec GB, et al. Efficacy and safety of oral alitretinoin (9-cis retinoic acid) in patients with severe chronic hand eczema refractory to topical corticosteroids: results of a randomized, double-blind, placebo-controlled, multicentre trial. *Br J Dermatol* 2008; **158** (4): 808–817.
3. Bissonnette R, Worm M, Gerlach B, et al. Successful retreatment with alitretinoin in patients with relapsed chronic hand eczema. *Br J Dermatol* 2010; **162** (2): 420–426.
4. Grahovac M, Molin S, Prinz JC, Ruzicka T, Wollenberg A. Treatment of atopic eczema with oral alitretinoin. *Br J Dermatol* 2010; **162** (1): 217–218.